

To cite this article: Sengul Inan M, Isik H, Unsal U, Sapmaz E, Kavakli K, Caylak H, Gozubuyuk A. Analysis of non-operative management of 53 thoracic gunshot injuries in a training hospital from a thoracic surgical perspective. *Curr Thorac Surg* 2023; 8(2): 85-90.

Original Article

Analysis of non-operative management of 53 thoracic gunshot injuries in a training hospital from a thoracic surgical perspective

 Merve Sengul Inan*,  Hakan Isik,  Ufuk Unsal,  Ersin Sapmaz,  Kuthan Kavakli,  Hasan Caylak,  Alper Gozubuyuk

Department of Thoracic Surgery, Gulhane Education and Training Hospital, Ankara, Turkey

ABSTRACT

Background: Although clinicians use selective non-operative control of thoracic gunshot injuries (TGSI), parameters that may affect the clinical response have not been studied. The aim of this study is to determine the safety and clinical outcome of non-operative follow-up of TGSIs.

Materials and Methods: Demographic, radiological and clinical features of 53 TSGIs, 2 female and 51 male, who were followed conservatively were examined. The data from the patients were retrospectively studied in terms of age, gender, extra-thoracic organ injuries, duration of chest tube, and length of hospital stay.

Results: Median age was 24. Twenty patients had extrathoracic injury (%37.7). The presence of extrathoracic pathology did not affect the total length of stay, but the diameter of hemothorax, pneumothorax or contusion did. No correlation was observed between the length of stay of the chest tube and the Thoracic Trauma Severity Score (TTSS) or Injury Severity Score (ISS) of the patients ($p = 0.756$, $p = 0.160$). No correlation was observed between the diameter of the contusion area and the TTSS score or ISS score ($p = 0.672$, $p = 0.201$).

Conclusions: Thoracic gunshot injuries can be approached conservatively by close monitoring and being aware of all life-threatening conditions. While trauma scores are quite adept at predicting length of stay, they do not always correlate with trauma severity.

Keywords: gunshot wounds, chest, penetrating trauma, selective nonoperative management.

Corresponding Author*: Merve Sengul Inan, MD. Gulhane Training and Research Hospital General Tevfik Saglam Street No:1, Kecioren, Ankara, Turkey.

E-mail: drmervesengul@hotmail.com Phone: +90 5062889188

Doi: 10.26663/cts.2023.0014

Received 26.07.2022 accepted 12.12.2022

Introduction

In trauma cases where many regions are affected at once, including vital organs, thoracic involvement is an indicator of the severity of the trauma. Blunt thoracic traumas are more common than penetrating traumas; however, in examining the trends of penetrating traumas, the rate of firearm injuries has increased in recent years [1]. Tissue damage in gunshot wounds is not limited to the trajectory of the bullet. The ballistic waves it creates in direct proportion to the kinetic energy hitting the body are transmitted by the parenchyma and cause ruptures and cavitations in neighboring tissues, resulting in an increased area of tissue damage [2]. In thoracic traumas, since the chest wall is affected most frequently (70%), conservative methods are sufficient to treat most patients. Only 15% to 30% of penetrating traumas require major procedures [3]. However, information regarding the prognosis of conservatively managed gunshot thoracic injuries is limited [4]. Knowledge of this field is mostly determined by clinical foresight. Thus this study aimed to analyze thoracic gunshot injuries with trauma scores to define treatment strategies and determine the effectiveness of conservative treatment and prognosis.

Materials and Methods

Data of patients who were treated for thoracic gunshot wounds in Gulhane Education and Training Hospital, between June 2000 and October 2021 were analyzed retrospectively. The study was approved by the institutional ethics committee (December 16, 2021, 2021-413). The thoracic cavity is defined as the cavity surrounded by the thoracic vertebrae, ribs, and sternum and the muscles that cover them, bounded below by the diaphragm and superiorly by the aperture thoracica superior. Patients who presented to the emergency department, who underwent surgery, and whose files could not be obtained were excluded from the study. Only patients with thoracic gunshot injuries treated without surgery were included in the study. All patients underwent abdominal and thoracic computed tomography (CT) during their first admission. Cerebral CT, extremity CT, and direct radiography were also performed when required. The largest contusion diameter was measured on the

first thorax CT scans. If there are two or more contusions, the diameter of the larger one is taken. Patients with penetrating cardiac, vascular, or diaphragmatic injuries were excluded. Eleven patients were excluded because their injuries only involved the muscle layer of the thorax but not intrathoracic organs. Ten patients died within an hour of arrival in the emergency department, so they were not included in the study. Finally, 53 patients with thoracic gunshot injury were reviewed.

Data from the patients were retrospectively studied in terms of age, sex, injury site (left, right, and bilateral), extrathoracic organ injuries, chest tube duration (day), length of hospital stay (day), and need for intensive care unit (ICU) stay or surgery after follow-up. The injury severity score (ISS) was defined by Baker et al. to classify patients with blunt and penetrating traumas [5]. In the ISS, wounds are scored from 1 (minimum severity) to 6 (maximum severity, almost always fatal) for seven anatomical regions (head and neck, face, chest, abdomen, extremity, and external) (Table 1). An injury with a magnitude of 6 in any region constitutes an ISS of 75. The thoracic trauma severity score (TTSS) provides prognostic information by evaluating patient data against anatomical and physiological data. A score of ≥ 7 has been associated with increased morbidity (Table 2) [6]. The recovery criteria were as follows: absence or minimal pain with adequate analgesics; ability to take in food orally; absence of abdominal discomfort, nausea, or vomiting; ability to void, dress, and ambulate; and absence of fever or tachycardia, finding or complaint indicating any pathology, requirement of additional blood transfusion, and gross increase in contusion. The patients were discharged from the hospital when their general condition was stable and by their own will.

Table 1. The Injury Severity Score (ISS).

Body region	Score	Injury severity
Head and neck	1	Minor
Face	2	Moderate
Chest	3	Serious
Abdomen	4	Severe
Extremity	5	Critical
External and other	6	Maximal (untreatable)

The ISS can range from 0 to 75. It is obtained by adding the squares of the scores of the 3 highest scoring regions.

Table 2. The Thoracic Trauma Severity Score (TTSS).

PaO ₂ /FiO ₂	Rib fracture	Contusion	Pleural involvement	Age (years)	Points
<400	0	None	none	<30	0
300-400	1-3	1 lobe	PT	30-41	1
200-300	4-6 unilateral	1 lobe bilateral or 2 lobes unilateral	Unilateral HT or HPT	42-54	2
150-200	>3 bilateral	<2 lobes bilateral	HT or HPT bilateral	55-70	3
<150	Flail chest	≥2 lobes bilateral	Tension PT	>70	5

Abbrev.: PT,pneumothorax; HT, hemothorax; HPT, hemopneumothorax

Results

Over 20 years, 145 gunshot injuries, with thoracic involvement, were recorded, and 53 of them were healed with a non-operative approach. Moreover, 51 of the 53 patients were male and two were female. The median age was 24 (15-60) years. Two of the gunshot injuries were attempted suicide. Rib fracture was observed in six patients, whereas sternal fractures were observed in two patients. Hemothorax, pneumothorax, and hemopneumothorax were identified in 40, 39, and 36 patients, respectively. Twenty (37.7%) patients had extrathoracic injuries. Two patients had pathologies that required intensive care indication. Patient demographics and injury characteristics are outlined in Table 3. The distribution of gunshot injuries is detailed in Figure 1. The length of stay was not different between those with and without extrathoracic pathology (p = 0.336). Hospitalization and tube thoracostomy time were significantly longer in patients with hemothorax or pneumothorax than those without (p < 0.01). The diameter of the contusion created by the firearm was not different between patients with and without hemothorax and patient with and without pneumothorax (p = 0.591, p = 0.904).

Parameters such as contusion diameter, hemothorax, pneumothorax, TTSS, ISS score, age, and sex were not different from each other in the group with and without tube insertion. The mean TTSS was 3.79 ± 0.256, and the median ISS score was 16 (4–36, IQR = 11). Age, TTSS, and ISS score were not correlated (p = 0.903, p = 0.245). A chest tube was inserted in 39 patients. There was no need for two or more chest tube insertions in any patients. No correlation was observed between the length of stay and chest tube duration (p = 0.756). No correlation was found between the TTSS and ISS scores (p = 0.160). TTSS and ISS scores were significantly different from each other in patients with and without tube insertion (both p < 0.01). A significant positive correlation was found between the total length of stay and their TTSS and ISS scores (r = 0.782, p < 0.01 and r = 0.582, p < 0.01, respectively) (Figure 2). No correlation was observed between the diameter of the contusion area in the lung and the TTSS or ISS score (p = 0.672, p = 0.201). Moreover, no correlation was observed between the chest tube duration and the diameter of the lung contusion (p = 0.624). The contusion diameter was also not correlated with the total hospital stay (p = 0.705). The number of rib fractures and chest tube duration were not correlated, but the number of rib fractures positively correlated with the total length of stay (p = 0.025, r = 0.308). The number of rib fractures was also positively correlated with the TTSS (p = 0.006, r = 0.376). A positive correlation was found between TTSS and ISS (p < 0.01, r = 0.605). Only two patients required admittance to the ICU. Two complications occurred, i.e., sepsis and pneumonia. No mortality was recorded.

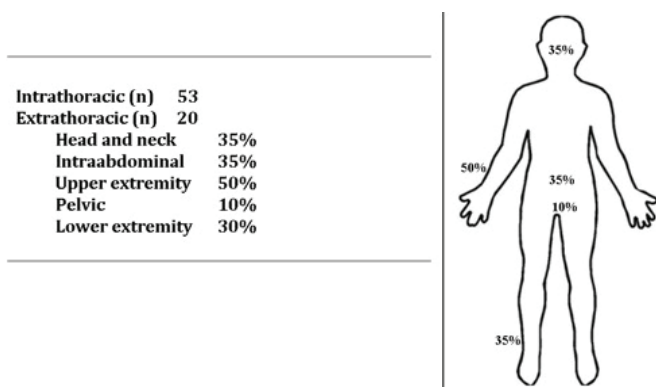


Figure 1. The distribution of gunshot injuries.

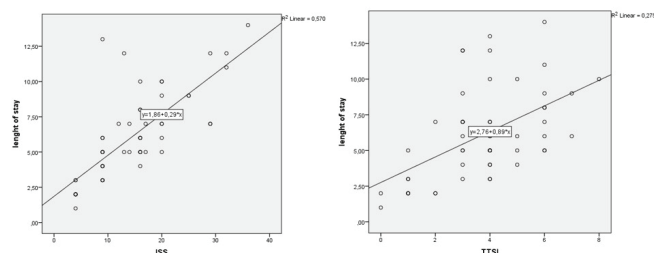


Figure 2. Shows the positive correlation between ISS and TTSS and length of stay.

Table 3. Characteristics of patients.

Age (median,range)	24(15-60)
Gender, number (male/female)	51/2
Extrathoracic injuries	20
Brain injury	7
Abdominal injury	7
Extremity injury	14
Thoracic injuries	53
Sternum fracture	2
Rib fracture	6
Pneumothorax	39
Hemothorax	40
Hemopneumothorax	36
Chest tube insertion (number)	39
Chest tube duration (day)	4.58
Length of stay ICU (day)	2.5
Length of stay hospital (day)	6.13
Mortality	0

Discussion

Serious thoracic injuries are the most common cause of trauma-related deaths [7]. Thoracic gunshot wounds require careful decision-making at every stage because of the damage and unexpected complications they cause. Having clearly defined indications for emergency surgery in patient management makes it easier for clinicians [8]. Furthermore, for hemodynamically stable patients, the boundaries for whom the wait–see approach can be applied are not clearly drawn. This study was conducted to facilitate clinicians in making tough decisions about their patients by investigating the epidemiology, characteristics, and non-operative management of thoracic gunshot injuries.

In this study, the rate of thoracic gunshot injuries treated without surgery was 36%. This rate is significantly higher than reported previously [8] because this hospital served as a military hospital in the first 15 years covered by the study, and patients who underwent surgery had considerably complicated injuries.

Hemothorax is one of the most common pathologies after thoracic gunshot wounds [9]. In our study, 40 (75.5%) patients had hemothorax, but we concluded that hemothorax was not associated with the destruction on the parenchyma. Since the bullet has a cauterizing effect on the parenchyma, hemothorax may not be seen in the absence of a thoracic wall or pulmonary vascular injury [10]. For hemothorax detected by CT, a clear rule has

not been specified regarding how much blood accumulation requires tube thoracostomy. Some clinicians find it appropriate to apply tube thoracostomy, even in small amounts [9]. Resorption capacity is individualized and depends on additional pathologies. Therefore, whether tube thoracostomy should be performed is a patient-specific decision, considering additional pathologies. In patients with minimal hemothorax and stable hemodynamics, tube insertion is not needed in cases without intrathoracic organ injury and bleeding. Close follow-up is essential, even if the initial drainage amount is not alarming in patients with tube placement.

If hemothorax is accompanied by pneumothorax, our approach is to perform tube thoracostomy regardless of the extent of pneumothorax. Considering that the differences in the amounts of lung contusion in gunshot injuries and lung capacity will decrease, tube thoracostomy is recommended for hemopneumothorax. However, isolated pneumothorax cases, i.e., without or with minimal hemothorax and does not cause dyspnea, can be followed without tube thoracostomy [11].

TTSS and ISS scores were different from each other in groups with and without both hemothorax and pneumothorax. Despite the lack of tomography imaging in these scoring systems, it is proved to be adept at determining the severity of injury.

Patients with hemothorax or pneumothorax significantly had longer length of stay. Respiratory symptoms also vary because the lung capacity will be different for each patient. However, a median of the total length of stay of 6 days is acceptable. Because the length of stay was not different between those with and without extrathoracic pathology, it can be concluded that the main factor affecting the total length of stay is the severity of the injury.

Scoring systems should be easy to implement without losing time [12]. Therefore, using anatomic scoring systems that do not consider physiological parameters is convenient for ease of use, but it may be insufficient in estimating mortality and morbidity because of the uncertainty of physiological heart and lung capacity information. Moreover, the three sites with the highest ISS scores are considered, and there is an opinion that the expected morbidity and mortality in a region is underestimated when other injuries are ignored [12-15]. A score of >20 is

an indicator of a poor prognosis. In our study, 16 patients had a score of ≥ 20 points. Only nine patients had an ISS score of < 9 . Despite its shortcomings, ISS is widely used and has been associated with mortality and length of hospital stay. Furthermore, a thoracic gunshot injury results in the patient's score being evaluated as 25 of 75 overall.

TTSS also considers functional capacity because of its parameters. It can also be easily calculated even with a chest X-ray alone, providing valuable information for the quick estimation of mortality and morbidity. A TTSS of < 9 is classified as minor trauma. In our study, the mean TSSS was 3.79 ± 0.256 , and the highest score was 8.

In the TTSS system, the only parameter detected by imaging is the presence of a contusion. However, the contusion diameter of our patients was not correlated with the TTSS. This finding indicates that the lung capacity of a patient and the tolerance level to damage caused by the contusion are more important in determining the severity of the damage. The finding that the total length of stay is not affected by the contusion diameter supports this finding. In the future, we think that combining lung-specific trauma scores with a biological marker reflecting the respiratory reserve of the individual, such as surfactant protein D, will yield more accurate results [13]. As expected, hemothorax or pneumothorax increases the patient's trauma score and prolongs hospital stay [8]. Extrathoracic organ injury has been reported in 75% of thoracic traumas [14,15]. In this study, this rate was 37.7%. Thoracic areas are of great importance in the estimation of mortality and morbidity.

In conclusion non-operative management of hemodynamically stable thoracic gunshot injuries with careful monitoring is effective and safe. Trauma scores calculated at the first sight are successful in estimating the results, but they may not accurately reflect the severity of trauma because of personal differences in respiratory capacity; thus, clinical decisions should be made accordingly. In the future, there is a need to develop trauma scoring systems combined with biochemical markers that reflect individual respiratory capacity.

Declaration of conflicting interests

The authors declared no conflicts of interest with respect to the authorship and/or publication of this article.

Funding

The authors received no financial support for the research and/or authorship of this article.

Ethics approval

Approval for study was obtained from the Clinical Research Ethics Committee of Gulhane Training and Research Hospital (16/12/2021, 2021-413) .

Authors' contribution

MSI; conceptualized and designed the study. UU, visualization, data presentation. MSI, HI, UU collected and analyzed data. AG, HC, ES, KK; revised the final version of the manuscript. All authors approved the final manuscript as submitted and agree to be accountable for all aspects of the work

References

1. Muckart DJ, Meumann C, Botha JB. The changing pattern of penetrating torso trauma in KwaZulu/Natal- a clinical and pathological review. *S Afr Med J* 1995; 85: 1172-4.
2. Çaylak H, Genç O. Toraksı ilgilendiren ateşli silah yaralanmaları. In: *TTD Toraks Cerrahisi Bülteni*. 2010; 1: 29-32.
3. Deslauriers J, Mehran R. Chest Trauma. In Deslauriers J, Mehran R. *Handbook of perioperative care in general thoracic surgery*. 1st ed. Philadelphia: Pennsylvania; 2005: 553-98.
4. Stawicki SP. Trends in nonoperative management of traumatic injuries - A synopsis. *Int J Crit Illn Inj Sci* 2017; 7: 38-57.
5. Baker SP, O'Neill B, Haddon W Jr, Long WB. The injury severity score: a method for describing patients with multiple injuries and evaluating emergency care. *J Trauma* 1974; 14: 187-96.
6. Mirka H, Ferda J, Baxa J. Multidetector computed tomography of chest trauma: indications, technique and interpretation. *Insights Imaging* 2012; 3:433-49.
7. Moon SH, Kim JW, Byun JH, Kim SH, Choi JY, Jang IS et al. The thorax trauma severity score and the trauma and injury severity score: Do they predict in-hospital mortality in patients with severe thoracic trauma?: A retrospective cohort study. *Medicine (Baltimore)* 2017; 96: 8317.
8. Kong VY, Sartorius B, Clarke DL. The selective conservative management of penetrating thoracic trauma is still appropriate in the current era. *Injury* 2015; 46: 49-53.
9. Pumarejo Gomez L, Tran VH. Hemothorax. In: *StatPearls*. Treasure Island (FL): StatPearls Publishing; August 11, 2021.

10. Chrysou K, Halat G, Hokschi B, Schmid RA, Kocher GJ. Lessons from a large trauma center: impact of blunt chest trauma in polytrauma patients-still a relevant problem? *Scand J Trauma Resusc Emerg Med* 2017; 20: 25-42.
11. Daurat A, Millet I, Roustan JP, Maury C, Taourel P, Jaber S, Capdevila X, Charbit J. Thoracic Trauma Severity score on admission allows to determine the risk of delayed ARDS in trauma patients with pulmonary contusion. *Injury* 2016; 47: 147-53.
12. Feldhaus I, Carvalho M, Waiz G, Igu J, Matthay Z, Dicker R, Juillard C. The feasibility, appropriateness, and applicability of trauma scoring systems in low and middle-income countries: a systematic review. *Trauma Surg Acute Care Open* 2020; 5: 424.
13. Bowler RP. Surfactant protein D as a biomarker for chronic obstructive pulmonary disease. *COPD* 2012; 9: 651-3.
14. Dogrul BN, Kiliccalan I, Asci ES, Peker SC. Blunt trauma related chest wall and pulmonary injuries: An overview. *Chin J Traumatol* 2020; 23: 125-38.
15. Subhani SS, Muzaffar MS, Khan MI. Comparison of outcome between low and high thoracic trauma severity score in blunt trauma chest patients. *J Ayub Med Coll Abbottabad* 2014; 26: 474-7.

This article is an open access article distributed under the terms and conditions of the Creative Commons Attribution (CC BY) license (<http://creativecommons.org/licenses/by/4.0/>).