

To cite this article: Kavakli K, Isik H, Ayberik G, Gozubuyuk A. Intraoperative findings of spontaneous hemopneumothorax. *Curr Thorac Surg* 2018;3(3):152.

Images in Thoracic Surgery

Intraoperative findings of spontaneous hemopneumothorax

Kuthan Kavakli*, Hakan Isik, Gokhan Ayberik, Alper Gozubuyuk

Department of Thoracic Surgery, University of Health Sciences, Gülhane Training and Research Hospital, Ankara, Turkey

Spontaneous hemopneumothorax is a life-threatening complication association with spontaneous pneumothorax and accumulation of more than 400 mL of blood in the pleural cavity [1]. Physiopathology includes ruptured vascularized bullae or lung parenchyma, an aberrant vessel or a hemorrhage from a torn parietal pleura [2].

A 25-year-old male was referred to our hospital with unexpanded lung and massive air leaks after chest tube insertion (Figure 1a). The patient was followed for two days at our clinic. Thoracoscopic bullae wedge resection was recommended for him because the air leak was not cease. He underwent thoracoscopic bullae wedge resection for curative intent. We determined a few vascularized bundles that were pending the bullae to apex of the chest intraoperatively (Figures 1b,c). It was seen that the lung did not separate from the thoracic wall and was attached through vascularized fibrous bundles when pneumothorax developed.

In our case, we detected the potential for spontaneous hemopneumothorax that can occur with the separation of these vascularized fibrous bands in the event of a sudden pulmonary collapse. We think that intraoperative findings of our case are important for explaining the physiopathology of spontaneous hemopneumothorax.

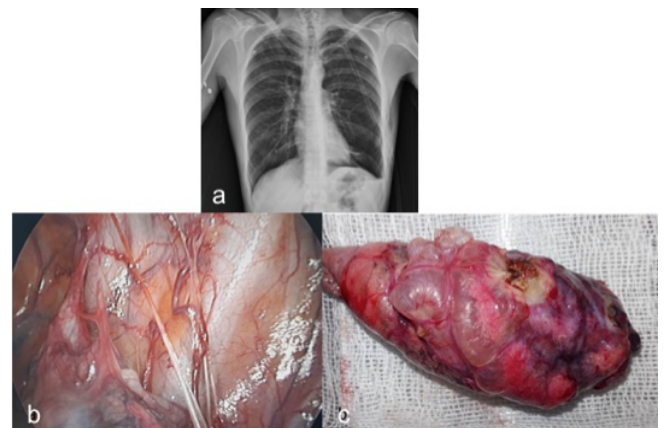


Figure 1a. Chest X ray of the patient revealed an unexpanded lung, **b.** intraoperative view of the vascularized bundle that was the cause of hemothorax after sudden collapse of the lung and **c.** wedge resection of the vascularized bullae.

Key Words: hemopneumothorax, spontaneous, thoracoscopic surgery

Declaration of conflicting interests

The authors declared no conflicts of interest with respect to the authorship and/or publication of this article.

Funding

The authors received no financial support for the research and/or authorship of this article.

References

1. Ohmori K, Ohata M, Narata M. Twenty-eight cases of spontaneous hemopneumothorax. *J Jpn Assoc Thorac Surg* 1988; 36: 1059-64.
2. Hsu NY, Shih CS, Hsu CP, Chen PR. Spontaneous Hemopneumothorax Revisited: Clinical Approach and Systemic Review of the Literature. *Ann Thorac Surg* 2005; 80: 1859-63.

Corresponding Author*: Kuthan Kavakli, MD. Department of Thoracic Surgery, SBÜ, Gülhane Eğitim ve Araştırma Hastanesi, Ankara, Turkey.

E-mail: kavaklikuthan@gmail.com

Phone: +90 312 3045171

Doi: 10.26663/cts.2019.00030

Received 14.08.2018 accepted 04.12.2018