Volume 10 Number 2 August 2025 eISSN 2548-0316

CURRENT THORACIC SURGERY

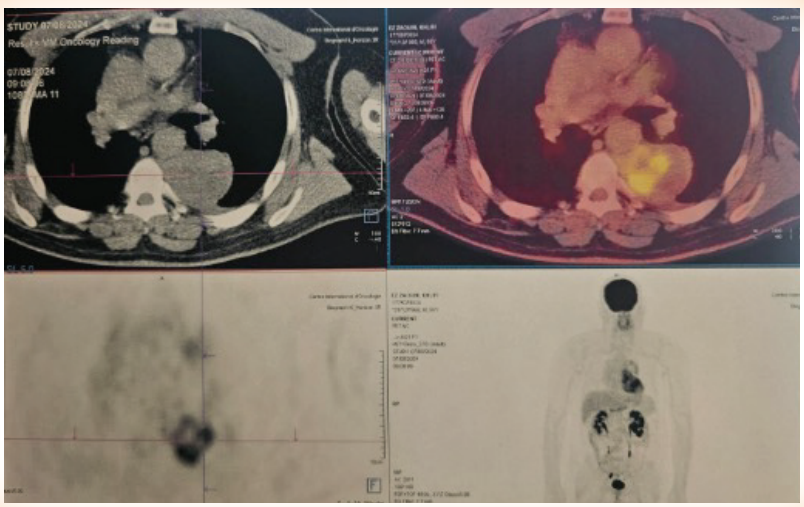

Official e-journal of the Turkish Society of Thoracic Surgery CTS

When you cite this journal, use the following abbreviation

Curr Thorac Surg

There is no article processing charges or submission fees for any submitted articles. All expenses of the journal are covered by Turkish Society of Thoracic Surgery

Table of Contents

Volume 10 Number 2 August 2025 eISSN 2548-0316

Original Articles

32 **Surgical outcomes in non–small cell lung cancer patients with synchronous solitary extrathoracic metastases: a retrospective cohort study**
İlker Kolbaş, Serdar Evman, Hakan Kıral, Elçin Ersöz, Çağatay Tezel, Volkan Baysungur

42 **The effect of obesity on prognosis in patients undergoing lobectomy for lung cancer impact of obesity on lobectomy results**
Halil Kolcu, Caner İşevi, Yasemin Bilgin Büyükkarabacak, Ahmet Başoğlu

49 **Diaphragm elevation after lobectomy: defining its extent, duration, and diagnostic significance**
Ilker Kolbas, Feyza Sonmez Topcu, Berivan Karatekin, Berker Ozkan

57 **22 years of surgical experience in non-cystic fibrosis bronchiectasis; what has changed in the last 10 years?**
Gamze Tanrıkulu, Tolga Evrim Sevinc, Hüseyin Melek, Eylem Yenturk, Erhan Ozer, Nilufer Aylin Acet Ozturk, Ahmet Ursavas, Cengiz Gebitekin, Ahmet Sami Bayram

Review

64 **Pulmonary metastasectomy: indications, surgical principles, prognosis and outcomes**
Ali Bilal Ulas, Yener Aydin, Atilla Eroglu

Case Report

81 **Management of recurrent spontaneous pneumothorax in twin pregnancy after IVF: a case report**
Argün Kış, Eren Zenci, Gökhan Öztürk

85 **Successful treatment of an endobronchial schwannoma by bronchoscopic application of electrocautery: a case report**
Mehmet Akif Ekici, Oğuzhan Turan, Bayram Metin, İbrahim Ethem Özsoy, Mehmet Akif Tezcan

89 **Adult ganglioneuroblastoma of the posterior mediastinum: case report**
Ikram Arramach, Hicham Harmouchi, Khaoula El Amraoui, Maha Tachaouine, Marouane Lakranbi, Yassine Ouadnouni, Mohamed Smahi, Mustapha Maaroufi

94 **Massive thoracic cystic schwannoma: a rare case occupying half of the hemithorax**
Mehmet Akif Ekici, Oğuzhan Turan, Enes Fatih Çelik, Muhammet Halil Aydoğdu

98 **Tracheal compression due to straight back syndrome: successful treatment with partial manubrium sterni resection**
Volkan Karaçam, Emrah Karcı, Fatma Mutlu

To cite this article: Kolbaş İ, Evman S, Kıral H, Ersöz E, Tezel Ç, Baysungur V. Surgical outcomes in non–small cell lung cancer patients with synchronous solitary extrathoracic metastases: a retrospective cohort study. Curr Thorac Surg 2025;10(2):32-41.

Original Article

Surgical outcomes in non–small cell lung cancer patients with synchronous solitary extrathoracic metastases: a retrospective cohort study

İlker Kolbaş[1]*, Serdar Evman[2], Hakan Kıral[2], Elçin Ersöz[2], Çağatay Tezel[3], Volkan Baysungur[2]

[1]Department of Thoracic Surgery, Istanbul Aydın University, VM Medical Park Florya Hospital, Istanbul, Turkey
[2]Department of Thoracic Surgery, Health Sciences University, Sureyyapasa Chest Diseases and Thoracic Surgery Training and Research Hospital, Istanbul, Turkey
[3]Department of Thoracic Surgery Memorial Hospital, Istanbul, Turkey

ABSTRACT

Background: Although stage IV non-small cell lung cancer (NSCLC) is often considered incurable, a growing body of evidence suggests that patients with oligometastatic disease-characterized by a limited number of metastases-may benefit from aggressive local treatment. This study evaluates the outcomes of patients with synchronous extrathoracic oligometastases and explores factors influencing survival.

Materials and Methods: We retrospectively analyzed 35 consecutive patients (4 females, 31 males) diagnosed with NSCLC who presented with synchronous extrathoracic metastases. All patients underwent standardized staging, including cervical mediastinoscopy, and, where feasible, both the primary tumor and metastatic lesions were managed with curative intent (surgery or ablative therapies).

Results: Overall mean survival was 38 ± 6 months; when hospital mortality (n = 4) was excluded, mean survival rose to 43 ± 7 months with a median of 27 months. The 1-, 2-, and 5-year survival rates were 58.9%, 47.7%, and 38.1%, respectively. Brain metastases were the most frequent site (74% of patients), and patients with brain metastases insignificantly exhibited higher mortality compared to other metastasis sites. Neither age, smoking history, nor tumor laterality significantly affected survival, and histological subtype did not confer a clear survival advantage.

Conclusions: In selected patients with synchronous oligometastatic NSCLC, aggressive treatment targeting both the primary tumor and metastases can extend survival beyond historical expectations for stage IV disease. Further large-scale prospective studies are needed to identify the subgroups most likely to benefit from bifocal (primary and metastatic) surgical management.

Keywords: non-small cell lung cancer, synchronous metastasis, oligometastatic disease, lobectomy

Corresponding Author*: Ilker Kolbas, MD. Beşyol, Florya, Akasya Sk. No:4 D:1, 34295 Küçükçekmece, İstanbul, Turkey.
E-mail: dr_ilkerkolbas@hotmail.com Phone: +90 5336329282
Doi: 10.26663/cts.2025.009
Received 24.04.2025 accepted 04.07.2025

Introduction

Lung cancer is the most common cause of cancer-related death worldwide. In 2020, there were approximately 1.8 million deaths due to lung cancer [1]. Non-small cell lung cancer (NSCLC) accounts for about 85% of all lung cancers, and a significant portion of these patients are in advanced stage at the time of diagnosis. Especially in metastatic (Stage IV) NSCLC, the prognosis is poor; modern series report a 5-year relative survival rate of only ~9% in patients with metastatic lung cancer (Non-Small Cell Lung Cancer Treatment (PDQ®) - NCI). Nonetheless, it has become clear that Stage IV disease is a heterogeneous group, and a subgroup with a limited number of metastases has been identified. In the condition termed "oligometastatic," the number and distribution of distant metastases are limited, and long-term survival can be achieved in suitable patients with aggressive local therapies [2].

In oligometastatic NSCLC, the most commonly involved organs are the brain and adrenal gland, followed by bone and other sites [3]. In particular, in the presence of synchronous (simultaneous) solitary brain or adrenal metastasis, administering curative treatments for both the primary lung tumor and the metastasis in eligible patients has historically yielded promising results. For example, in NSCLC cases with a single brain metastasis, surgical resection of the brain metastasis or stereotactic radiosurgery combined with lung resection can achieve long-term survival [4]. Similarly, various studies have reported 5-year survival rates in the range of 25–30% in cases where lung surgery was performed together with metastasectomy for adrenal gland metastasis. These data indicate the potential curative role of aggressive local therapies in oligometastatic NSCLC [5-7].

Current guidelines and studies support a multidisciplinary, individualized approach in patients with oligometastatic NSCLC. The European Society for Medical Oncology (ESMO) guideline recommends adding local ablative therapies to systemic treatment in appropriate patients and emphasizes that surgical or stereotactic radiotherapy for oligometastatic foci should be considered regardless of molecular profile [3]. The National Comprehensive Cancer Network (NCCN) guidelines similarly recommend administering definitive/curative treatments for the metastatic focus(es) and the primary tumor. In particular, in the case of a solitary synchronous brain metastasis, it is recommended to apply stereotactic radiosurgery or neurosurgery to the metastasis first, followed by definitive chest treatment (surgical resection or radiotherapy) [4]. This approach aims to increase the chance of long-term disease control by treating the primary tumor after controlling the metastasis. Phase II randomized studies conducted in recent years have also shown that adding local consolidative therapy (via surgery or radiotherapy) to systemic treatment can improve both progression-free survival and overall survival [4,8,9]. In light of all these data, surgical treatment emerges as an important option in appropriate patients with limited metastatic NSCLC. In this study, we evaluated the outcomes of surgical treatments applied to patients with synchronous solitary extrathoracic oligometastatic NSCLC. To this end, we examined the demographic and tumor-related characteristics of patients in our clinic who underwent surgery for both primary lung cancer and the metastatic lesion, the treatments applied, survival and recurrence outcomes, and analyzed prognostic factors and the effects of surgical approaches.

Materials and Methods

Study design and patient selection

In this retrospective cohort study, we examined NSCLC patients treated in our clinic between January 2012 and December 2017 who presented with a synchronous single extrathoracic metastasis at the time of diagnosis. The inclusion criteria for the study were: (1) a histologically confirmed diagnosis of NSCLC, (2) the presence of a solid extrathoracic organ metastasis, and (3) the application of curative-intent treatment via anatomical lung resection (lobectomy or pneumonectomy) and metastasis-focused therapy. The distant metastasis was considered synchronous, meaning it was diagnosed simultaneously with the primary lung cancer. Cases deemed inoperable for surgical treatment or those in which anatomical resection was not feasible were excluded from the study. A total of 35 consecutive patients who met these criteria during the specified period were included. All patients provided informed consent prior to treatment. The study protocol was reviewed and approved by the Institutional Review Board of Istanbul Aydın University (Approval No. 102/2024). The research was conducted in accordance with the World Medical Association Declaration of Helsinki on Ethical Principles for Medical Research Involving Human Subjects. Given the retrospective nature of the study, all patient data were anonymized prior to analysis.

Diagnosis and staging

Standard staging protocols were applied in patients' preoperative evaluations. All cases underwent contrast-enhanced thoracic computed tomography (CT), 18F-FDG positron emission tomography/computed tomography (PET/CT), and cranial magnetic resonance imaging

(MRI) to assess the primary tumor and metastatic foci. For patients in whom PET/CT showed suspicious extrathoracic lesions, such as in the abdomen, advanced imaging (e.g., abdominal MRI) was performed. To confirm the diagnosis, each patient underwent endobronchial biopsy via fiber-optic bronchoscopy; in suitable cases with peripheral tumors, samples were also taken by transthoracic fine needle aspiration biopsy (TTFNA), and histopathological diagnoses were confirmed. As part of preoperative staging for the primary lung tumor, cervical mediastinoscopy was performed in all cases to exclude mediastinal lymph node metastasis. Patients for whom mediastinoscopic biopsy results revealed no N2/N3 metastatic lymph node involvement were found suitable for surgical resection.

Surgical treatment and perioperative management

Treatment strategies were determined in a multidisciplinary manner depending on the location of the metastasis. In patients with brain metastases, metastasis-directed treatment was performed first, guided by the size, number, and location of the metastasis: either neurosurgery or stereotactic radiosurgery (SBRT) [4]. The metastasis management in patients with brain metastases was personalized through joint decisions by neurosurgery and radiation oncology specialists. About three to four weeks (on average 24 days, range 17-48 days) following successful treatment of the brain metastasis, anatomical resection of the primary lung cancer was carried out. For patients with metastases in sites outside the brain - adrenal gland, spleen, or ocular region - the process was reversed: first, the primary lung lesion was resected, then, after a brief recovery period, the metastatic lesion was surgically excised. Metastasectomy was the preferred treatment modality, and in all cases with non-cerebral solitary metastases, the metastatic lesion was removed surgically. All thoracic surgeries were performed under general anesthesia via a posterolateral thoracotomy, during which anatomical resections (lobectomy or pneumonectomy) were performed. Systematic mediastinal lymph node dissection was carried out during lung resection. Postoperative care was managed according to standard protocols, and all patients were referred to medical oncology in the postoperative period to receive necessary oncological treatments, such as adjuvant chemotherapy and/or radiotherapy. Deaths occurring within 30 days of the operation were defined as "hospital mortality."

Statistical Analysis

The demographic characteristics of the patients (age, sex), smoking history (pack-years), localization of the primary tumor (right/left and specific lobes), tumor size and histological type, metastasis site and the therapy used for metastasis, type of lung operation performed, hospital length of stay post-surgery, postoperative complications, and mortality were all recorded. In pathological staging, the pT and pN stages were determined in accordance with the 8th edition of the TNM classification [10]. The patients were followed for the development of recurrence or new metastases, as well as for any treatments administered in such cases (e.g., salvage treatments in the event of recurrence). The data obtained were analyzed using the IBM SPSS or NCSS 2007 (Kaysville, Utah, USA) software package. Continuous variables were reported as mean ± standard deviation or median (minimum–maximum). Categorical variables were summarized as numbers and percentages. Appropriate statistical tests were used for comparisons; for instance, normally distributed quantitative data were evaluated between two groups using Student's t-test. Fisher's exact test or the Fisher-Freeman-Halton test was used for comparing categorical variables. Survival analyses were performed via the Kaplan-Meier method, and comparisons of survival curves across groups were carried out using the Log-rank test. Overall survival was defined as the time from the date of thoracic surgery to the date of death or the last follow-up. A p-value of <0.05 was deemed statistically significant.

Results

Among the 35 patients included in the study, 31 were men and 4 were women (male ratio of 88.6%). At the time of diagnosis, patients ranged in age from 39 to 77 years, with a mean age of 60.1 ± 8.3 years. Just over half of the cases (n = 18, 51.4%) were 60 years of age or younger, and the remaining 48.6% were older than 61. The majority of the patients were smokers, with an average consumption of around 30 pack-years; 60% had a smoking history of ≥20 pack-years (Table 1). Regarding the location of the primary lung tumors, 37.1% were in the right upper lobe, 31.4% in the left upper lobe, 25.7% in the left lower lobe, and 5.7% in the right lower lobe. Histopathological examination revealed that 71.4% (n = 25) of the cases were adenocarcinoma, 25.7% (n = 9) were squamous cell carcinoma, and 2.9% (n = 1) were large cell carcinoma. Distribution of the pathological T stage was most frequently T2 (57.1%, n = 20), followed by T3 (28.6%, n = 10). Three patients (8.6%) were staged as T1, and two (5.7%) were T4. In terms of pathological N stage, nearly half of the patients had no mediastinal lymph node metastasis: 54.3% (n = 19) were N0, 25.7% (n = 9) were N1, and 20% (n = 7) were N2. All patients were clinically classified as Stage IVA (M1b) due to the presence of a single distant metastasis.

Table 1. Survival analysis by age (n=31).

Age Group	N	Deaths (Ex)	Alive	Survival rate (%)	Mean survival (months)	95% CI (Lower–upper)
≤60 years	17	9	8	47.1	36.49 ± 8.94	18.970–54.018
≥61 years	14	5	9	64.3	34.03 ± 4.95	24.312–43.748

Metastasis and treatment characteristics

The most frequently observed metastasis site was the brain; 26 of the 35 patients (74.3%) had synchronous brain metastases. Adrenal gland metastases were found in 6 patients (17.1%). Three patients (8.6%) had metastases in other organs (2 in the spleen, 1 in the eye). Curative-intent treatment was carried out in all cases for metastatic foci: in 80.0% (n = 28), the metastasis was removed surgically (metastasectomy), while in 20.0% (n = 7) it was managed with stereotactic radiosurgery (Table 2). Radiosurgery was applied only in patients with brain metastases, and in a subset of these, SBRT was chosen instead of neurosurgery. Examination of the surgical resections for the primary lung tumor showed that 29 patients underwent lobectomy (82.9%) and 6 underwent pneumonectomy (17.1%). Postoperative hospital stays ranged from 3 to 12 days, with a median of 5 days (mean 5.9 ± 2.3 days) (Table 2). The number of patients who developed major postoperative complications was small, and four patients died within 30 days of surgery (categorized as "hospital mortality").

Oncological results

Following the completion of appropriate adjuvant treatments determined by pathological stage, patients were followed up on a regular basis. The median follow-up time was 14 months (range: 0-81 months). Within this period, 4 patients (11.4%) experienced disease recurrence (local recurrence and/or new distant metastases); in most patients (88.6%), the disease remained under control during follow-up. At the last follow-up, 17 patients (48.6%) were alive, while 18 (51.4%) had died. Since 4 of those 18 died within the first month postoperatively, the perioperative mortality rate was calculated as 11.4%. All four 30-day deaths occurred in patients with synchronous brain metastases. In case 1, postoperative day 3 – sepsis progressing to multi-organ failure after cranial metastasectomy + left upper lobectomy. In case 2, postoperative day 10 – pneumonia leading to respiratory failure after stereotactic body radiotherapy (SBRT) to the brain lesion + right pneumonectomy. In case, postoperative day 22 – acute respiratory failure following SBRT + right upper lobectomy. In case 4, postoperative day 25 - acute myocardial infarction after SBRT + sleeve right upper lobectomy. Excluding these early deaths (i.e., censored), the overall survival analysis (n = 31) showed a median survival of 27 months (Table 3). The 1 and 2- year survival rates were 59% and 48%, respectively, while the 5-year survival rate was about 38%. Examination of the Kaplan-Meier curve indicated that the last death occurred in the 38th month and that the survival rate stabilized at around 39% at about 3 years.

Prognostic analyses

Survival by site of metastasis is summarized in Table 2, where 22 patients had brain metastases and 6 had adrenal metastases. In the brain-metastasis group, 10 patients (45.5%) survived, 12 died, and the mean survival was 26 ± 4 months (median: 20 months). Among patients with adrenal metastases, all 6 were alive (100%) at their last follow-up, yielding a mean survival time of 21 ± 17 months (median: 18 months). Because no deaths occurred in the adrenal group, statistical comparison among metastasis sites was not feasible. The survival curve by metastasis site is displayed in Figure 1A.

Further analysis in patients with brain metastases appears in Table 3, which contrasts survival in those who underwent cranial surgery versus radiosurgery. Of the 18 who had cranial surgery, 9 (50.0%) survived, and the mean survival was 28 ± 4 months (median: 24 months). In the 4 who received radiosurgery, 1 (25.0%) remained alive, and the mean survival was 13 ± 2 months (median: 11 months). A Log Rank test found no statistically significant difference between these two treatment subgroups ($p > 0.05$). These results appear in Figure 1B. In terms of primary tumor location, Table 4 shows that 12 patients had right-lung tumors (9 alive, 3 deceased) and 19 had left-lung tumors (8 alive, 11 deceased). The mean survival was 59 ± 10 months for right-sided tumors (median: 24 months) and 25 ± 4 months for left-sided tumors (median: 24 months). The difference by tumor laterality was not significant ($p > 0.05$), and their survival curves are provided in Figure 1C. When stratified by T stage, as indicated in Table 5, 22 patients were in T1+T2 (14

alive, 8 deceased) with a mean survival of 51 ± 8 months (median: 21 months), whereas 9 were in T3+T4 (3 alive, 6 deceased) with a mean survival of 21 ± 5 months (median: 12 months). Although survival was numerically longer in T1+T2, the Log Rank test did not show a statistically significant difference ($p = 0.125$; $p > 0.05$). The T-stage survival curves can be seen in Figure 1D. Survival by N stage is presented in Table 6: N0 included 18 patients (9 alive, 9 deceased) with a mean survival of 29 ± 4 months (median: 27 months), N1 included 6 patients (5 alive, 1 deceased) with a mean survival of 67 ± 12 months (median: 23 months), and N2 included 7 patients (3 alive, 4 deceased) with a mean survival of 23 ± 6 months (median: 20 months). No statistically significant difference emerged among N0, N1, and N2 ($p > 0.05$). The survival curves by N stage are shown in Figure 2. With regard to cell type, Table 7 indicates that, among 21 patients diagnosed with adenocarcinoma, 12 (57.1%) remained alive (mean survival: 46 ± 8 months, median: 27 months), while among 9 diagnosed with squamous cell carcinoma, 5 (55.6%) were alive (mean survival: 28 ± 5 months, median: 38 months). Large cell carcinoma was excluded from the comparative analysis because it was observed in only one patient. No statistically significant difference emerged between adenocarcinoma and squamous cell carcinoma ($p > 0.05$).

Regarding surgical procedure, Table 8 shows that 26 patients underwent lobectomy (16 alive, 10 deceased) and 5 underwent pneumonectomy (1 alive, 4 deceased). Mean survival was 49 ± 7 months (median: 18 months) in the lobectomy group and 23 ± 6 months (median: 27 months) in the pneumonectomy group. Although pneumonectomy had fewer survivors numerically, the Log Rank test did not indicate a statistically significant difference ($p > 0.05$). Lastly, to explore risk factors potentially affecting mortality, a logistic regression analysis was conducted, as summarized in Table 9. Metastasis, advanced T stage, and surgery type were included because their effects approached significance in earlier steps. The overall model was significant and explained around 64.5% of variance in mortality. However, none of these variables-metastasis, T stage, or surgery-reached statistical significance ($p > 0.05$).

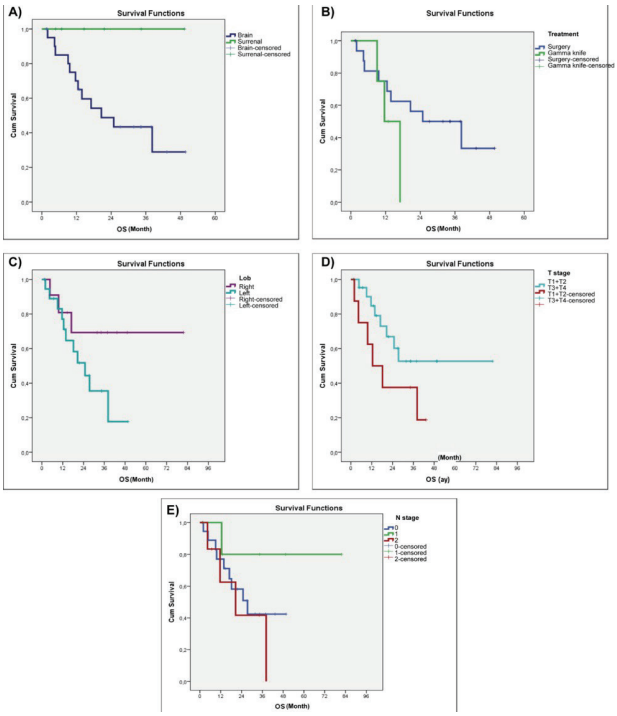

Figure 1. Survival curves (n=31). Survival curve by primary tumor location **(A)**, survival curve by T stage **(B)**, survival curve by N stage **(C)**, survival curve by cell type **(D),** survival curve by surgical procedure **(E)**.

Table 2. Survival Analysis by metastasis (n=31).

Metastasis site	N	Deaths (Ex)	Alive	Survival rate (%)	Mean survival (months)	95% CI (Lower–upper)
Brain	22	12	10	45.5	26.71 ± 4.20	18.47–34.94
Adrenal	6	0	6	100	–	–

Note: Other metastasis sites were excluded due to insufficient numbers.

Table 3. Survival analysis by treatment type in patients with brain metastases (n=22).

Treatment	N	Deaths (Ex)	Alive	Survival rate (%)	Mean survival (months)	95% CI (Lower–Upper)
Surgery	18	9	9	50.0	28.72 ± 4.76	19.387–38.056
Radiosurgery	4	3	1	25.0	13.67 ± 2.11	9.524–17.809

Table 4. Survival analysis by primary tumor location.

Primary location	N	Deaths (Ex)	Alive	Survival rate (%)	Mean survival (months)	95% CI (Lower–upper)
Right lung	12	3	9	75.0	59.99 ± 10.56	39.289–80.701
Left lung	19	11	8	42.1	25.58 ± 4.06	17.619–33.549

Table 5. Survival analysis by T stage (n=31).						
T Stage	N	Deaths (Ex)	Alive	Survival rate (%)	Mean survival (months)	95% CI (Lower-upper)
T1+T2	22	8	14	63.6	51.16 ± 8.05	35.370–66.949
T3+T4	9	6	3	33.3	21.14 ± 5.56	10.028–32.201

Table 6. Survival analysis by N stage (n=31).						
N Stage	N	Deaths (Ex)	Alive	Survival rate (%)	Mean survival (months)	95% CI (Lower–upper)
N0	18	9	9	50.0	29.81 ± 4.59	20.815–38.805
N1	6	1	5	83.3	67.91 ± 12.39	43.627–92.199
N2	7	4	3	42.9	23.35 ± 6.83	9.969–36.737

Table 7. Survival analysis by cell type (n=31).						
Cell type	N	Deaths (Ex)	Alive	Survival rate (%)	Mean survival (months)	95% CI (Lower–upper)
Adenocarcinoma	21	9	12	57.1	46.35 ± 8.15	30.379–62.328
Squamous cell carcinoma	9	4	5	55.6	28.16 ± 5.43	17.511–38.801
Note: Large cell carcinoma (1 case) was excluded.						

Table 8. Survival analysis by surgical procedure (n=31).						
Procedure	N	Deaths (Ex)	Alive	Survival rate (%)	Mean survival (months)	95% CI (Lower–upper)
Lobectomy	26	10	16	61.5	49.85 ± 7.49	35.172–64.537
Pneumonectomy	5	4	1	20.0	23.24 ± 6.54	10.424–36.051

Table 9. Logistic regression analysis of risk factors for mortality.			
Variable	p	Odds ratio	95% CI (Lower–upper)
Metastasis (Adrenal)	0.999	0.000	–
Metastasis (Other)	0.941	0.892	0.043–18.436
Surgery (Pneumonectomy)	0.343	3.676	0.249–54.324
T Stage (T3+T4)	0.603	1.608	0.268–9.628

Discussion

Although the current NCCN guideline provides no specific treatment recommendations for other extrathoracic metastases, it does recommend aggressive local therapy for NSCLC with oligometastatic disease in the brain or adrenal gland [11]. In our clinic, all lung cancer patients routinely undergo thoracic CT, PET/CT, and cranial MRI for metastasis screening. In the event that suspicious extrathoracic lesions are detected on imaging, further imaging methods targeting those lesions are used. MRI was performed for six patients with adrenal metastases, two with splenic metastases, and one with an ocular metastasis when metastasis was suspected. We included 35 consecutive patients (4 women, 31 men) diagnosed with lung cancer who had synchronous extrathoracic metastases. In our study, patient follow-up ranged from 0 to 81 months, with a mean of 20 months. The mean survival time was 38 ± 6 months. After censoring hospital mortality (n = 4), the remaining 31 patients had a mean survival of 43 ± 7 months and a median survival of 27 months. The 1, 2, and 5-year survival rates were 58.9%, 47.7%, and 38.1%, respectively. In the phase II study by De Ruysscher et al with 40 patients having synchronous oligometastatic NSCLC, the median survival was 13 months, and the 1-, 2-, and 3-year survival rates were 56.4%, 23.3%, and 17.5%, respectively [12]. In the series by Plönes et al, which included 56 cases of synchronous oligometastatic NSCLC, overall survival was 14 months [13]. In the 29-case series of oligometastatic NSCLC by Collaud et al, the 5-year survival rate was 36.8%, and the median survival was 20 months [14]. In the 75-case series published by Fleckenstein et al, which included both synchronous and metachronous metastases, the median follow-up was 54 months; the median survival was 21 months; and the 1-, 2-, and 5-year survival rates were 78%, 44%, and 27%, respectively [15]. In a review by Ashworth et al involving 2176 cases, the median survival was 14 months, while the 1-, 2-, and 5-year survival rates were 57.2%, 42%, and 23.3%, respectively [16]. Over the course of follow-up in our study, 51.4% (n = 18) of patients died, while 48.6% (n = 17) remained alive. Among those who died, the hospital mortality rate was 11.4% (n = 4). Our in-hospital mortality rate was found to be higher than in the literature. All four patients who experienced hospital mortality had brain metastases. One patient with adenocarci-

noma, who underwent cranial metastasectomy followed by mediastinoscopy and left upper lobectomy, died on postoperative day 3 from sepsis and multi-organ failure. Another patient with adenocarcinoma, who underwent stereotactic body radiotherapy (SBRT) followed by mediastinoscopy and right pneumonectomy, died of pneumonia and respiratory failure on postoperative day 10. A third patient, diagnosed with adenocarcinoma, who underwent SBRT followed by mediastinoscopy and right upper lobectomy, died from acute respiratory failure on postoperative day 22. Finally, a patient diagnosed with adenocarcinoma, who underwent SBRT followed by mediastinoscopy and a sleeve right upper lobectomy, died of acute myocardial infarction on postoperative day 25. Although reported hospital mortality after lung resection is typically lower, we believe that an 11.4% in-hospital mortality rate is acceptable for patients with advanced-stage disease. In our series, postoperative complications related to surgery included pneumonia in two patients, supraventricular tachycardia in two patients, and wound infection in one patient. All five patients who developed postoperative complications recovered with medical treatment.

In our series, patient ages ranged from 39 to 77, with an average of 60 ± 8 years. In our study, 55.6% (n = 18) of patients were 60 years old or younger, while 48.6% (n = 17) were 61 or older. We found no relationship between age and survival (p = 0.461). After censoring hospital mortality, mean survival for patients aged ≤60 years (n = 17) was 36 ± 8 months with a median survival of 20 months, whereas for those ≥61 (n = 14), the mean survival was 34 ± 4 months. In a series by Pessini et al, survival was poorer among those over 70 [17]. In a review by Ashworth et al of 2176 oligometastatic NSCLC cases and a study by Bai et al involving 76 patients with synchronous brain oligometastases, age was reported as a poor prognostic factor for overall survival. In our study, no statistically significant difference in survival was found between these age groups (p > 0.05). Among our patients, 40.0% (n = 14) had a smoking history of <20 pack-years, 31.4% (n = 11) had 21–39 pack-years, and 28.6% (n = 10) had >40 pack-years. In the series by Guerra et al, which included 78 oligometastatic NSCLC patients treated with definitive chemoradiotherapy, heavy smoking was found to be a poor prognostic factor. In the study by Bai et al, smoking had a negative effect on survival [18]. In our series, smoking history had no impact on survival (p = 0.360).

In the series by Barone et al and Johnson et al, no effect on survival was observed when the side (laterality) of the surgery was evaluated. In reviews by Novoa et al and Ashworth et al, lobectomy was identified as a better prognostic factor for survival [19]. In the study by Plönes et al, the type of lung resection showed no relationship with survival [20]. In our study, 5.7% (n = 2) of primary tumors were located in the right lower lobe, 37.1% (n = 13) in the right upper lobe, 25.7% (n = 9) in the left lower lobe, and 31.4% (n = 11) in the left upper lobe, with no significant effect of tumor laterality on survival (p = 0.456). After censoring hospital mortality, the mean survival was 59 ± 10 months (median: 24) for right-sided tumors and 25 ± 4 months (median: 24) for left-sided tumors. No significant survival difference was found based on tumor side (p > 0.05). In evaluating tumor histology, we found that 71.4% (n = 25) of patients had adenocarcinoma, 25.0% (n = 9) had squamous cell carcinoma, and 3.6% (n = 1) had large cell carcinoma. Consistent with the literature, adenocarcinoma was the most frequently observed histological type. In the series by Plönes et al, median survival according to cell type was 18 months for adenocarcinoma, 14 months for squamous cell carcinoma, and 8 months for large cell carcinoma; no statistically significant difference was found based on histological subtype. After censoring hospital mortality in our study, for adenocarcinoma, the mean survival time was 46 ± 8 months (median: 27), and for squamous cell carcinoma, it was 28 ± 5 months (median: 38). Since only one patient had large cell carcinoma, no separate survival analysis was performed for that subgroup. In reviews by Novoa et al. and Ashworth et al, adenocarcinoma was reported as a favorable prognostic factor [21]. However, in the series by Fleckenstein et al and Collaud et al, no difference in prognosis was found between adenocarcinoma and other histological types. In our series as well, when comparing histological subtypes, no statistically significant difference in survival was observed (p > 0.05). For an accurate evaluation of the N (nodal) stage in oligometastatic disease, invasive mediastinal staging is recommended. In our study, all patients underwent cervical mediastinoscopy to evaluate mediastinal lymph node status, and among those confirmed pathologically as N0, 29 underwent lobectomy and 6 underwent pneumonectomy. In the literature, better survival has been reported in patients undergoing lobectomy [21]. After censoring hospital mortality, the mean survival was 49

± 7 months (median: 18) in patients who underwent lobectomy and 23 ± 6 months (median: 27) in those who underwent pneumonectomy. We found no statistically significant difference in survival between types of surgical procedures ($p > 0.05$).

In patients with synchronous brain metastases, the treatment strategy should address the metastasis first. Metastasis therapy options include cranial surgery, radiosurgery, WBRT, or post-surgical radiosurgery [17]. While guidelines provide no definitive recommendation for curative resection, they do suggest WBRT following a curative resection [22]. In our series, of 26 patients with synchronous isolated brain metastases, 26.9% (n = 7) underwent SBRT and 73.1% (n = 19) underwent cranial surgery with metastasectomy. Following metastasis treatment, pneumonectomy was performed in 5 patients and lobectomy in 21. There was no statistical difference regarding treatments of the metastasis and primary tumor. Postoperatively, 13 patients received adjuvant chemotherapy (CT) alone, 3 had WBRT, 6 had WBRT plus CT and thoracic RT, and 4 had WBRT plus CT. Recurrent lesions were identified in four patients, who underwent additional surgical resection. After censoring hospital mortality, survival analysis showed that the mean survival was 13 ± 2 months (median: 11) in those who had SBRT for metastases and 28 ± 4 months (median: 24) in those who underwent cranial surgery. There was no statistically significant difference in survival based on the type of metastasis treatment ($p > 0.05$). Among 26 patients with brain metastases, the mean survival time was 26 ± 4 months (median: 20), with 1-, 2-, and 5-year survival rates of 50.2%, 43.0%, and 28.7%, respectively, when hospital mortality was censored. In NSCLC patients with adrenal metastases, a five-year survival rate of 25% has been reported if both the primary tumor and adrenal metastasis can be resected. The literature indicates that adrenal metastases occur in 1.5–3.5% of NSCLC cases. Tantevyanon et al reported in a review of 114 patients with synchronous adrenal metastases that overall survival was 12 months and the five-year survival was 26% [5]. In a study of 37 patients by Raz et al, adrenalectomy, ipsilateral metastasis, N0/1 status, and synchronous metastasis were cited as favorable prognostic factors for patients with adrenal metastases [7]. In a 37-patient series published by Barone et al, the five-year median survival rate for those undergoing adrenalectomy was 29.3% [23]. Treatment options for adrenal metastases include surgery or radiosurgery; however, surgical intervention offers better survival outcomes [23]. In patients with isolated adrenal metastases in NSCLC who undergo complete resection of the lung tumor and have no other metastases, surgery or radiosurgery is recommended. In our series, after resection of the primary tumor, six patients underwent a surgical adrenalectomy. Their mean overall survival was 21 ± 17 months, with a median of 18 months. Postoperatively, five patients received adjuvant CT, and one received adjuvant CT plus thoracic RT.

In a review by Salah et al involving 75 oligometastatic cases (excluding brain and adrenal metastases), a five-year survival rate of 50% was reported. In that series, which was predominantly composed of adenocarcinoma cases undergoing lobectomy, nodal involvement was found to be the main factor influencing survival [22]. In autopsy studies of cancer patients, the prevalence of splenic metastasis has been reported to be 2-7%. In our series, of two patients with splenic metastases, one underwent simultaneous splenectomy with lung resection, while the other had a post-resection splenectomy. Both received adjuvant CT postoperatively. Although current guidelines do not recommend metastasectomy for lesions beyond the brain and adrenal glands, the survival times for these two patients were 18 months for the first and 81 months for the second. About 30% of ocular metastases originate from lung cancer. The incidence of choroidal metastases in lung carcinoma is 2-6.7% [24]. Treatment options for choroidal metastases include radiotherapy, plaque radiotherapy, surgical resection, transpupillary thermotherapy, and intravitreal chemotherapy [25]. Survival ranges from 5 to 19 months in patients with choroidal metastases secondary to a lung primary [25]. In our series, the patient with ocular metastasis underwent surgical enucleation and received adjuvant chemotherapy in the postoperative period; that patient died in the 27th month after pulmonary resection. In earlier years, stage IV disease was managed conservatively, and survival was limited to 8-11 months. However, with recent advances in surgery and staging, as well as large published series, survival has improved in patients with oligometastatic disease. In selected oligometastatic patients, complete resection of the primary tumor and curative treatment of metastases can prolong survival. Although our patients with brain metastases had poorer survival compared to patients with other metastases, our data suggest that ag-

gressive therapy improves survival in oligometastatic NSCLC. Our series, as well as an increasing number of studies in the literature, demonstrate prolonged survival in patients undergoing bifocal surgical treatment.

Declaration of conflicting interests

The authors declared no conflict of interest with respect to the authorship and/or publication of this article.

Funding

The authors received no financial support for the research and/or authorship of this article.

Ethics approval

This study was approved by the Istanbul Aydin University Non-invasive Research Ethics Committee with protocol number 102/2024, and conducted in accordance with the Declaration of Helsinki.

Authors' contribution

IK,HK, Design: IK,HK,CT, Definition of intellectual content: RSE,VB, Literature Search: IK,EEK, Clinical Studies:IK,EEK,RSE,HK,CT,VB, Data acquisition: IK,HK, Statistical analysis: IK, Manuscript preparation: IK, Editing: HK,VB, Review:RSE,CT

References

1. Sung H, Ferlay J, Siegel RL, Laversanne M, Soerjomataram I, Jemal A, Bray F. Global Cancer Statistics 2020: GLOBOCAN Estimates of Incidence and Mortality Worldwide for 36 Cancers in 185 Countries. CA Cancer J Clin 2021; 71: 209-249.
2. Euhus CJ, Ripley TR, Medina CG. The Role of Surgery for Oligometastatic Non-Small Cell Lung Cancer. Cancers (Basel) 2022; 14: 2524.
3. Torresan S, Costa J, Zanchetta C, De Marchi L, Rizzato S, Cortiula F. Oligometastatic NSCLC: Current Perspectives and Future Challenges. Curr Oncol 2025; 32: 75.
4. Kumar A, Kumar S, Potter AL, Raman V, Kozono DE, Lanuti M, Jeffrey Yang CF. Surgical management of non-small cell lung cancer with limited metastatic disease involving only the brain. J Thorac Cardiovasc Surg 2024; 167: 466-477.
5. Tanvetyanon T, Robinson LA, Schell MJ, Strong VE, Kapoor R, Coit DG, Bepler G. Outcomes of adrenalectomy for isolated synchronous versus metachronous adrenal metastases in non-small-cell lung cancer: a systematic review and pooled analysis. J Clin Oncol 2008; 26: 1142-7.
6. Gao XL, Zhang KW, Tang MB, Zhang KJ, Fang LN, Liu W. Pooled analysis for surgical treatment for isolated adrenal metastasis and non-small cell lung cancer. Interact Cardiovasc Thorac Surg 2017; 24: 1-7.
7. Raz DJ, Lanuti M, Gaissert HC, Wright CD, Mathisen DJ, Wain JC. Outcomes of patients with isolated adrenal metastasis from non-small cell lung carcinoma. Ann Thorac Surg 2011; 92: 1788-92; discussion 1793.
8. Varela G, Thomas PA. Surgical management of advanced non-small cell lung cancer. J Thorac Dis 2014; 6 Suppl 2: S217-23.
9. Deboever N, Mitchell KG, Feldman HA, Cascone T, Sepesi B. Current Surgical Indications for Non-Small-Cell Lung Cancer. Cancers (Basel) 2022; 14: 1263.
10. O'Sullivan B, Asamura H, Lee A, Van Eycken E, Denny M, Amin M. TNM Classification of Malignant Tumours. Head and Neck Tumours. 8th ed. John Wiley & Sons, Ltd, 2017: p. 18-21.
11. Iyengar P, All S, Berry MF, Boike TP, Bradfield L, Dingemans AC, et al., Treatment of Oligometastatic Non-Small Cell Lung Cancer: An ASTRO/ESTRO Clinical Practice Guideline. Pract Radiat Oncol 2023; 13: 393-412.
12. Dingemans AC, Hendriks LEL, Berghmans T, Levy A, Hasan B, Faivre-Finn C et al., Definition of Synchronous Oligometastatic Non-Small Cell Lung Cancer-A Consensus Report. J Thorac Oncol 2019; 14: 2109-19.
13. George J, Maas L, Abedpour N, Cartolano M, Kaiser L, Fischer RN et al., Evolutionary trajectories of small cell lung cancer under therapy. Nature 2024; 627: 880-9.
14. Collaud S, Stahel R, Inci I, Hillinger S, Schneiter D, Kestenholz P, Weder W. Survival of patients treated surgically for synchronous single-organ metastatic NSCLC and advanced pathologic TN stage. Lung Cancer 2012; 78: 234-8.
15. Stelljes M, Krug U, Beelen DW, Braess J, Sauerland MC, Heinecke A et al., Allogeneic transplantation versus chemotherapy as postremission therapy for acute myeloid leukemia: a prospective matched pairs analysis. J Clin Oncol 2014; 32: 288-96.
16. Ashworth AB, Senan S, Palma DA, Riquet M, Ahn YC, Ricardi U et al., An individual patient data metaanalysis of outcomes and prognostic factors after treatment of oligometastatic non-small-cell lung cancer. Clin Lung Cancer 2014; 15: 346-55.
17. Pessina F, Navarria P, Cozzi L, Ascolese AM, Maggi G, Riva M et al., Outcome Evaluation of Oligometastatic Patients Treated with Surgical Resection Followed by Hypofractionated Stereotactic Radiosurgery (HSRS) on the Tumor Bed, for Single, Large Brain Metastases. PLoS One 2016; 11: e0157869.

18. Bai H, Xu J, Yang H, Jin B, Lou Y, Wu D, Han B. Survival prognostic factors for patients with synchronous brain oligometastatic non-small-cell lung carcinoma receiving local therapy. Onco Targets Ther 2016; 9: 4207-13.

19. Lanuti M. Surgical management of oligometastatic non–small cell lung cancer. Thorac Surg Clin 2016: 26: 287-94.

20. Plönes T, Osei-Agyemang T, Krohn A, Passlick B. Surgical Treatment of Extrapulmonary Oligometastatic Non-small Cell Lung Cancer. Indian J Surg 2015; 77(Suppl 2): 216-20.

21. Novoa NM, Varela G, Jiménez MF. Surgical management of oligometastatic non-small cell lung cancer. J Thorac Dis 2016; 8(Suppl 11): S895-S900.

22. Salah S, Tanvetyanon T, Abbasi S. Metastatectomy for extracranial extra-adrenal non-small cell lung cancer solitary metastases: systematic review and analysis of reported cases. Lung Cancer 2012; 75: 9-14.

23. Barone M, Di Nuzzo D, Cipollone G, Camplese P, Mucilli F. Oligometastatic non-small cell lung cancer (NSCLC): adrenal metastases. Experience in a single institution. Updates Surg 2015; 67: 383-7.

24. Namad T, Wang J, Tilton A, Abdel Karim N. Bilateral choroidal metastasis from non-small cell lung cancer. Case Rep Oncol Med 2014; 2014: 858265.

25. Singh A, Singh P, Sahni K, Shukla P, Shukla V, Pant NK. Non-small cell lung cancer presenting with choroidal metastasis as first sign and showing good response to chemotherapy alone: a case report. J Med Case Rep 2010; 4: 185.

This article is an open access article distributed under the terms and conditions of the Creative Commons Attribution (CC BY) license (http://creativecommons.org/licenses/by/4.0/).

To cite this article: Kolcu H, İşevi C, Bilgin Büyükkarabacak Y, Başoğlu A. The effect of obesity on prognosis in patients undergoing lobectomy for lung cancer impact of obesity on lobectomy results. Curr Thorac Surg 2025;10(2):42-48.

Original Article

The effect of obesity on prognosis in patients undergoing lobectomy for lung cancer impact of obesity on lobectomy results

Halil Kolcu[1], Caner İşevi[2]*, Yasemin Bilgin Büyükkarabacak[2], Ahmet Başoğlu[3]

[1]Department of Thoracic Surgery, Bayburt State Hospital, Bayburt, Turkey
[2]Department of Thoracic Surgery, Ondokuz Mayis University, Medical Faculty, Samsun, Turkey
[3]Department of Thoracic Surgery, Istanbul Atlas University, Medical Faculty, İstanbul, Turkey

ABSTRACT

Background: Obesity, defined as a body mass index (BMI) of 30 kg/m^2 or greater, constitutes a substantial global health concern and is associated with an extensive spectrum of comorbid conditions, including numerous malignancies. Among these, lung cancer presents distinctive challenges, particularly with regard to surgical management. The present study examines the impact of obesity on clinical outcomes - namely, prognosis, postoperative complications, and overall survival - among patients undergoing lobectomy for primary lung cancer.

Materials and Methods: This retrospective analysis was conducted on a cohort of 1,000 patients who underwent lobectomy for lung cancer between 2010 and 2017. Following the application of predefined inclusion criteria-namely, pathological staging limited to 2A through 3A and the exclusion of cases with concurrent malignancies-a total of 71 patients were deemed eligible for the final analysis. Key clinical and perioperative variables were assessed, including body mass index (BMI), incidence of postoperative complications, duration of hospitalization, operative time, smoking history, and overall survival. Statistical analysis was performed using SPSS version 21.0. Group comparisons were conducted using independent samples t-tests for continuous variables with two categories, while one-way analysis of variance (ANOVA) was applied for comparisons involving more than two groups. Categorical data were evaluated using chi-square tests. A two-tailed p-value of less than 0.05 was considered indicative of statistical significance.

Results: Patients classified as obese exhibited a significantly longer postoperative survival duration when compared to individuals with normal or overweight BMI ($p < 0.05$). The incidence of postoperative complications was also notably lower in the obese group ($p < 0.05$). However, no statistically significant differences were observed among the BMI categories in terms of hospital stay length or operative time ($p > 0.05$). Interestingly, the prevalence of smoking was markedly lower among obese patients ($p < 0.001$). In contrast, among patients who survived less than five years following surgery, BMI was not found to be significantly associated with either extended hospitalization or postoperative complication rates.

Conclusions: The findings of this study highlight a compelling example of the so-called "obesity paradox" within the context of thoracic surgery. Despite the anticipated risks associated with higher BMI and accompanying comorbidities, obese patients demonstrated more favorable postoperative outcomes and improved survival compared to their non-obese counterparts. These results prompt further investigation into the biological and clinical factors contributing to this paradoxical trend, with the aim of better informing perioperative risk stratification and individualized treatment strategies in lung cancer surgery.

Keywords: obesity, body mass index, lung cancer, lobectomy, postoperative complications

Corresponding Author*: Caner İşevi, MD. Ondokuz Mayıs University, Department of Thoracic Surgery, Samsun, Turkey.
E-mail: drcanerisevi@gmail.com Phone:+90 3623121919 / 4240
Doi: 10.26663/cts.2025.010
Received 15.05.2025 accepted 11.08.2025

Introduction

Obesity, defined as a body mass index (BMI) of 30 kg/m^2 or above, is a major public health issue that significantly contributes to the development of cancer and various other pathological conditions. In an increasingly digital and sedentary society, the global prevalence of obesity continues to rise, driven in large part by the widespread availability and consumption of high-calorie, nutrient-poor foods. A 2010 study reported that the prevalence of obesity in the United States had reached 35% [1-3].

The burden of obesity becomes particularly evident in the context of complex surgical procedures, such as lung resections, esophageal surgeries, lung transplants, and chest wall reconstructions. These interventions are frequently complicated by intra- and postoperative challenges, including glycemic fluctuations, blood pressure instability, impaired wound healing, deep vein thrombosis, respiratory and systemic infections, ischemic heart disease, renal dysfunction, and cerebrovascular events [4,5].

Despite decades of research, the relationship between obesity and surgical outcomes in thoracic procedures remains a subject of ongoing debate. Clinical experience often suggests increased rates of postoperative complications in obese individuals; however, findings in the literature have been inconsistent. While some studies report a rise in morbidity among obese patients undergoing thoracic surgery, this trend does not appear to extend to mortality rates [6,7].

Interestingly, although obesity is well-documented to increase the risk of overall mortality and is linked to a spectrum of metabolic and clinical disorders, higher BMI has also been associated with improved survival outcomes in certain cancer populations. This apparent contradiction, often referred to as the "obesity paradox," has prompted further inquiry into the prognostic role of obesity in oncologic surgery. The present study was designed to evaluate the impact of obesity on outcomes following lobectomy in patients with lung cancer.

Materials and Methods

This retrospective analysis included a total of 1,000 patients who underwent surgical resection for lung cancer at our institution between 2010 and 2017. Following the application of specific inclusion criteria, 71 patients were selected for detailed evaluation. Eligibility criteria encompassed pathological staging between 2A and 3A, the absence of synchronous malignancies, no prior history of neoadjuvant chemotherapy, absence of concomitant tuberculosis, clear surgical margins confirmed by pathology, availability of all required clinical and laboratory data, and follow-up continuity within our clinic.

Preoperative staging involved standard imaging modalities including chest radiography, contrast-enhanced thoracic computed tomography (CT), positron emission tomography-CT (PET-CT), and brain magnetic resonance imaging (MRI). A thorough preoperative work-up was completed for all patients, incorporating pulmonary function testing, complete blood count, comprehensive biochemical profiling, and pre-anesthesia evaluations. Where indicated, patients with coexisting medical conditions were referred to appropriate specialties for further consultation and risk stratification.

Demographic variables - including age, sex, smoking history, and relevant personal and familial health information - were collected from electronic health records and archived patient files. Clinical data such as comorbidities, histological subtype, surgical technique, and operative duration were similarly retrieved. Preoperative height and weight values were extracted from anesthesia assessment forms, and body mass index (BMI) was calculated as weight in kilograms divided by height in meters squared. Based on BMI, patients were stratified into four categories: underweight (<18.5), normal weight (18.5-24.9), overweight (25-29.9), and obese (≥30). Ethical approval for this study was granted by the University Clinical Research Ethics Committee on May 21, 2021 (Reference No. B.30.2.ODM.0.20.08/316).

Statistical Analyses

Statistical analyses were conducted using SPSS software version 21.0. Descriptive statistics-including means, standard deviations, and percentages-were reported for relevant variables. Comparisons between two independent groups were analyzed using independent samples t-tests, while comparisons across more than two groups employed one-way analysis of variance (ANOVA). Relationships between categorical variables were assessed using the chi-square test. Survival outcomes were analyzed using the Kaplan-Meier method, and differences between groups were compared with the log-rank test. A p-value below 0.05 was accepted as the threshold for statistical significance.

Results

The demographic characteristics of the study population are detailed in Table 1. The relationship between body mass index (BMI) and intraoperative variables was first assessed by analyzing surgical duration across BMI categories (Table 2). This analysis did not reveal any statistically significant difference in mean operative time among underweight, normal weight, overweight, and obese patients ($p > 0.05$).

Similarly, the potential impact of BMI on postoperative length of hospital stay was examined, and no significant variation was found across the different BMI groups (Table 3), with p-values exceeding the threshold for significance ($p > 0.05$).

Table 1. Baseline demographic and clinical characteristics of patients undergoing lobectomy.					
Sex	N	%	Age	N	%
Male	62	87.3	<65	41	57.7
Female	9	12.7	≥65	30	42.3
Weight			Height		
Maximum 113 kg Minimum 56 kg Mean 74.16 kg			Maximum 180 cm Minimum 147 cm Mean 166.07 cm		
Postoperative survival			Smoking history		
<5 year	29	40.8	No	12	16.9
≥5 year	42	59.2	Yes	59	83.1
Stage			Body Mass Index		
2A	12	16.9	Normal	31	43.7
2B	36	50.7	Overweight	27	38.0
3A	23	32.4	Obese	13	18.3
Postoperative complication			Charlson Comorbidity Index		
No	36	50.7	2	16	22.5
Yes	35	49.3			
Prolonged hospital stay			3	19	26.8
No	50	70.4			
Yes	21	29.6	4	20	28.2
Postoperative cure			5	7	9.9
Yes	42	59.2	6	4	5.6
No	29	40.8	7	5	7.0

Table 2. Comparison of mean surgical duration among BMI categories in patients undergoing lobectomy for lung cancer.					
BMI*	N	Mean (Surgical duration)	Standard error	F	p
Normal	31	285.81	12.08	1.478	0.235
Overweight	27	277.11	13.93		
Obese	13	244.77	23.67		
**BMI: Body Mass Index*					

Conversely, a statistically significant difference in median postoperative survival was identified across BMI categories (Table 4), with obese patients demonstrating longer survival than those in the normal and overweight groups ($p < 0.05$). To further evaluate cumulative survival, a Kaplan-Meier survival analysis was conducted. Although the survival curve appeared more favorable in the obese group, the difference did not reach statistical significance in the log-rank test ($p = 0.27$). The Kaplan–Meier curves are presented in Figure 1.

Postoperative complication rates were also evaluated in relation to BMI, and the analysis yielded a significant association ($p < 0.05$). Among patients who did not experience postoperative complications, 27.8% were found to be obese, whereas 51.4% of those who developed complications were categorized as overweight (Table 5).

When assessing the relationship between BMI and prolonged postoperative hospital stay, no statistically significant association was detected ($p > 0.05$), as presented in Table 6.

Lastly, a strong and statistically significant relationship was observed between BMI and smoking status (Table 7). According to the findings, 52.5% of patients with a normal BMI were active smokers, while 58.3% of non-smokers were classified as obese ($p < 0.001$).

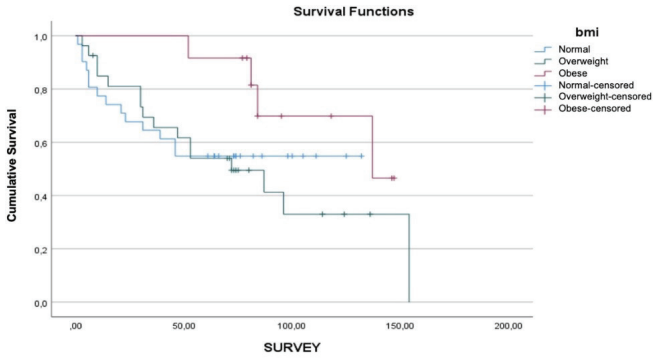

Figure 1. The Kaplan-Meier curves for survival.

Table 3. Comparison of mean postoperative hospital stay across BMI categories in patients undergoing lobectomy for lung cancer.

BMI	N	Mean (Postoperative hospital stay)	Standard error	F	p
Normal	31	9.97	1.11	1.420	0.249
Overweight	27	12.30	2.36		
Obese	13	7.46	0.73		

**BMI: Body Mass Index*

Table 4. Comparison of mean postoperative survival duration across BMI groups in patients undergoing lobectomy for lung cancer

BMI	N	Mean (Postoperative survival)	Standard error		
Normal	31	55.42b	7.08		
Overweight	27	60.37b	7.96	4.175	0.019
Obese	13	92.46a	10.14		

**BMI: Body Mass Index*

Table 5. Distribution of postoperative complication status by BMI categories in patients undergoing lobectomy for lung cancer.

BMI	Postoperative complication		χ^2	p
	Yes, n(%)	No, n(%)		
Normal	17 (47.2)	14 (40.0)		
Overweight	9 (25.0)	18 (51.4)	7.047	0.029
Obese	10 (27.8)	3 (8.6)		

**BMI: Body Mass Index*

Table 6. Distribution of prolonged postoperative hospital stay according to BMI categories in patients undergoing lobectomy for lung cancer.

BMI	Prolonged hospital stay		χ^2	p
	Yes, n(%)	No, n(%)		
Normal	21 (42.0)	10 (47.6)		
Overweight	18 (36.0)	9 (42.9)	1.547	0.461
Obese	11 (22.0)	2 (9.5)		

**BMI: Body Mass Index*

Table 7. Distribution of smoking history across BMI categories in patients undergoing lobectomy for lung cancer.

BMI	Smoking history		χ^2	p
	No, n(%)	Yes, n(%)		
Normal	0 (0.00)	31 (52.5)		
Overweight	5 (41.7)	22 (37.3)	18.989	<0.001
Obese	7 (58.3)	6 (10.2)		

**BMI: Body Mass Index*

Discussion

Body mass index (BMI), frequently used as a marker of nutritional status, has long been associated with the pathophysiology of numerous systemic diseases. Obesity and excess weight are established contributors to hypertension and diabetes mellitus, and by extension, to ischemic heart disease and cerebrovascular events [4,8,9]. Lung cancer, the leading cause of cancer-related mortality worldwide, presents a more nuanced picture in this regard. Several epidemiological studies suggest an inverse correlation between BMI and lung cancer incidence [10-12]. This relationship, however, is confounded by smoking - an established carcinogen - that is more prevalent among individuals with lower BMI, complicating interpretation of causality.

Cigarette smoking remains the principal risk factor for lung cancer, with reported rates as high as 91.5% [13]. Although the disease may arise from multiple etiologies, the fact that 85-90% of lung cancer cases are linked to smoking highlights its predominant role. Risk intensity correlates with the age of smoking initiation, duration of use, cigarette type, and daily consumption patterns [14].

In our cohort, 83.1% of patients reported current or former smoking, while 16.9% were non-smokers. These results align with findings from Ergün et al [15], who documented a smoking prevalence of 87.3% among lung cancer patients. Although no significant correlation was identified between smoking status and survival in our analysis, a noteworthy observation was the lower prevalence of smoking among obese patients relative to their non-obese counterparts. Given the known contribution of smoking to pulmonary complications following thoracic surgery, the reduced smoking rate among obese individuals may offer a partial explanation for their lower incidence of postoperative complications. The concurrent reduction in smoking prevalence and complication rates in obese patients may reflect a non-random association. Since smoking is a known contributor to postoperative pneumonia, persistent air leakage, and prolonged hospitalization, the protective effect seen in obese individuals may be attributable not solely to body composition but also to diminished tobacco exposure. This potential confounder merits closer examination in future prospective studies with broader inclusion criteria.

Among all patients analyzed, postoperative complications were observed in 49.3%, prolonged hospital stays in 29.6%, and successful recovery in 59.2%. These figures are somewhat lower than those reported in a study by Ülker [16], who found complication rates of 67.5% and 67.3% for conventional and sleeve lobectomy, respectively. That study detailed specific complications, including prolonged air leaks (35.4%), pneumonia (20.7%), reoperation (15.3%), and atrial arrhythmias (11.4%) for conventional lobectomies, while similar distributions were reported for sleeve resections, with arrhythmias (22.4%) and pneumonia (20.9%) being prominent.

In the present analysis, the rate of postoperative complications was significantly lower in the obese group. Although obese patients appeared to have shorter durations of surgery and hospitalization, these differences did not reach statistical significance. This is consistent with prior literature suggesting divergent findings on the role of BMI in surgical risk. Some investigators have identified high BMI as a potential risk factor for cardiopulmonary complications [7,17,18], whereas others argue that these associations are either absent or, in some cases, inversely related [19-21]. Furthermore, some studies suggest that low BMI may be a stronger predictor of adverse outcomes than obesity itself [18,22]. One plausible explanation is that patients with higher BMI are more likely to engage with the healthcare system due to obesity-related comorbidities, thereby enabling earlier cancer detection and improved perioperative optimization.

Regarding postoperative survival, our findings demonstrated significantly longer survival times in the obese cohort compared to the normal and overweight groups. This is in agreement with the meta-analysis by Gupta et al [23], which similarly reported enhanced survival among lung cancer patients with elevated BMI. These observations reinforce the presence of an "obesity-survival paradox" in thoracic surgical oncology.

In our subgroup analysis, a significant relationship was observed between BMI and the occurrence of postoperative complications. Among patients who remained free of complications, 27.8% were obese, whereas 51.4% of those who experienced complications were in the overweight category. While an inverse association was noted between BMI and prolonged hospitalization, this did not reach statistical significance.

Although obesity is widely recognized as a contributor to chronic diseases such as diabetes, hypertension, and coronary artery disease [21,22], its effect on perioperative and postoperative mortality within thoracic surgery remains equivocal. Some studies have identified low BMI as a predictor of worse outcomes, including increased complication rates and reduced survival. Notably, this subset of patients also tends to experience longer operative times. Nevertheless, perioperative mortality remains relatively low across BMI categories. Intriguingly, obese patients tend to experience fewer postoperative complications than those with lower BMI, with lung transplantation being the notable exception. In such cases-particularly among individuals with COPD or cystic fibrosis-elevated BMI correlates with higher perioperative mortality, reinforcing the complexity of this clinical context.

Despite an elevated risk of minor wound infections, obesity has not been conclusively associated with an increase in major complications or mortality [24-27]. In fact, the two largest studies conducted to date on this subject report paradoxical survival advantages in obese patients. In one analysis involving 337 obese lung cancer patients matched 1:1 with non-obese controls, obesity was independently associated with improved survival outcomes

[20,21]. Similarly, a large multicenter retrospective study encompassing 18,800 patients who underwent lung resections showed a statistically significant association between higher BMI and reduced 30-day mortality rates [28].

These findings underscore the complexity of interpreting the obesity paradox in surgical outcomes, particularly in thoracic oncology. The apparent survival advantage observed in obese individuals raises questions regarding the interplay of metabolic, immunologic, and behavioral variables that may influence perioperative risk and recovery.

It is important to acknowledge several limitations of this study. The relatively modest sample size restricts the broader applicability of the findings. In addition, the retrospective design limits the ability to establish causal relationships. Furthermore, important covariates such as nutritional status, body composition, and muscle mass were not assessed, which may have influenced outcome measures and introduced residual confounding.

In conclusion, the relationship between obesity and perioperative outcomes in thoracic surgery remains multifaceted and at times contradictory. Although clinical experience might lead one to anticipate increased complication rates among obese patients, emerging evidence points toward a more complex interaction. The survival advantage observed in this study among obese patients undergoing lobectomy and mediastinal lymphadenectomy supports the growing recognition of the obesity paradox in thoracic oncology. Notably, no significant differences were observed in surgical duration or hospital length of stay across BMI groups, and smoking prevalence was lower in the obese population. While these results contribute to the ongoing discourse, the limited sample size and retrospective nature of the analysis highlight the need for large-scale, prospective, multicenter studies to validate these findings and explore the biological mechanisms underlying the observed associations.

Declaration of conflicting interests

The authors declared no conflicts of interest with respect to the authorship and/or publication of this article.

Funding

The authors received no financial support.

Ethics approval

This study was approved by Ondokuz Mayis University Research Ethics Committee May 21, 2021 (Reference No. B.30.2.ODM.0.20.08/316).

Authors' contribution

HK,CI; made substantial contributions to the design of the work, HK,CI,YBB; made the analysis of data, HC;CI;YBB; have drafted the work, YBB;AB; revised it. All authors read and approved the fnal manuscript.

References

1. Paul S, Andrews W, Osakwe NC, Port JL, Lee PC, Stiles BM et al. Perioperative outcomes after lung resection in obese patients. Thorac Cardiovasc Surg 2015; 63: 544-50.
2. Flegal KM, Carroll MD, Kit BK, Ogden CL. Prevalence of obesity and trends in the distribution of body mass index among US adults, 1999–2010. JAMA 2012; 307: 491-7.
3. Flegal KM, Kit BK, Orpana H, Graubard BI. Association of all-cause mortality with overweight and obesity using standard body mass index categories: a systematic review and meta-analysis. JAMA 2013; 309: 71-82.
4. Prospective Studies Collaboration. Body-mass index and cause-specific mortality in 900,000 adults: collaborative analyses of 57 prospective studies. Lancet 2009; 373: 1083-96.
5. Sepesi B, Gold KA, Correa AM, Heymach JV, Vaporciyan AA, Roszik J et al. The influence of body mass index on overall survival following surgical resection of non-small cell lung cancer. J Thorac Oncol 2017; 12: 1280-7.
6. Julien JBS, Aldrich MC, Sheng S, Deppen SA, Burfeind WR Jr, Putnam JB Jr et al. Obesity increases operating room time for lobectomy in the Society of Thoracic Surgeons database. Ann Thorac Surg 2012; 94: 1841-7.
7. Petrella F, Radice D, Borri A, Galetta D, Gasparri R, Solli P et al. The impact of preoperative body mass index on respiratory complications after pneumonectomy for non-small cell lung cancer. Eur J Cardiothorac Surg 2011; 39: 738-44.
8. Manson JE, Colditz GA, Stampfer MJ, Willett WC, Rosner B, Monson RR et al. A prospective study of obesity and risk of coronary heart disease in women. N Engl J Med 1990; 322: 882-9.
9. Rexrode KM, Hennekens CH, Willett WC, Colditz GA, Stampfer MJ, Rich-Edwards JW et al. A prospective study of body mass index, weight change, and risk of stroke in women. JAMA 1997; 277: 1539-45.
10. Knekt P, Heliövaara M, Rissanen A, Aromaa A, Seppänen R, Teppo L et al. Leanness and lung cancer risk. Int J Cancer 1991; 49: 208-13.
11. Kabat GC, Wynder EL. Body mass index and lung cancer risk. Am J Epidemiol 1992; 135: 769-74.

12. Olson JE, Yang P, Schmitz K, Vierkant RA, Cerhan JR, Sellers TA. Differential association of body mass index and fat distribution with three major histologic types of lung cancer: evidence from a cohort of older women. Am J Epidemiol 2002; 156: 606-15.

13. Göksel T. Akciğer kanserinde risk faktörleri ile histolojik tip ilişkisi (Türkiye'nin Akciğer Kanseri Haritası Projesi). In: Türk Toraks Derneği 11. Yıllık Kongresi Bildiri Özetleri Kitabı; 2008; Antalya.

14. Halilçolar H, Tatar D, Ertuğrul G, Çakan A, Acıtaş MG, Kömürcüoğlu B. Epidemiyoloji. In: Akciğer Kanseri Multidisipliner Yaklaşım. Ankara: Bilimsel Tıp Yayınevi; 1999. p. 17-22.

15. Ergün D, Savaş İ, Ergün R, Kaya A, Gülhan M. Akciğer kanseri ve ailesel kanser hikâyesi. Tuberk Toraks 2009; 57: 251-8.

16. Ülker MG. Akciğer kanseri tanısıyla sleeve veya konvansiyonel lobektomi uygulanan olguların karşılaştırılması: Propensity skor [specialist thesis]. İstanbul: İstanbul Üniversitesi, İstanbul Tıp Fakültesi, Göğüs Cerrahisi Anabilim Dalı; 2020.

17. Launer H, Nguyen DV, Cooke DT. National perioperative outcomes of pulmonary lobectomy for cancer in the obese patient: a propensity score matched analysis. J Thorac Cardiovasc Surg. 2013;145:1312-8.

18. Thomas PA, Berbis J, Falcoz PE, Le Pimpec-Barthes F, Bernard A, Jougon J et al. National perioperative outcomes of pulmonary lobectomy for cancer: the influence of nutritional status. Eur J Cardiothorac Surg 2014; 45: 652-9.

19. Dhakal B, Eastwood D, Sukumaran S, Hassler G, Tisol W, Gasparri M, et al. Morbidities of lung cancer surgery in obese patients. J Thorac Cardiovasc Surg 2013; 146: 379-84.

20. Smith PW, Wang H, Gazoni LM, Shen KR, Daniel TM, Jones DR. Obesity does not increase complications after anatomic resection for non-small cell lung cancer. Ann Thorac Surg 2007; 84: 1098-105.

21. Attaran S, McShane J, Whittle I, Poullis M, Shackcloth M. A propensity-matched comparison of survival after lung resection in patients with a high versus low body mass index. Eur J Cardiothorac Surg 2012; 42: 653-8.

22. Jagoe RT, Goodship TH, Gibson GJ. The influence of nutritional status on complications after operations for lung cancer. Ann Thorac Surg 2001; 71: 936-43.

23. Gupta A, Majumder K, Arora N, Mayo HG, Singh PP, Beg MS et al. Premorbid body mass index and mortality in patients with lung cancer: a systematic review and meta-analysis. Lung Cancer 2016; 102: 49-59.

24. Thomas EJ, Goldman L, Mangione CM, Marcantonio ER, Cook EF, Ludwig L et al. Body mass index as a correlate of postoperative complications and resource utilization. Am J Med 1997; 102: 277-83.

25. lasen J, Junger A, Hartmann B, Jost A, Benson M, Virabjan T, Hempelmann G. Increased body mass index and peri-operative risk in patients undergoing non-cardiac surgery. Obes Surg 2004; 14: 275-81.

26. Dindo D, Muller MK, Weber M, Clavien PA. Obesity in general elective surgery. Lancet 2003; 361: 2032-5.

27. Lee CT, Dunn RL, Chen BT, Joshi DP, Sheffield J, Montie JE. Impact of body mass index on radical cystectomy. J Urol 2004; 172: 1281-5.

28. Kozower BD, Sheng S, O'Brien SM, Liptay MJ, Lau CL, Jones DR, Shahian DM, Wright CD. STS database risk models: predictors of mortality and major morbidity for lung cancer resection. Ann Thorac Surg 2010; 90: 875-81; discussion 881-3.

This article is an open access article distributed under the terms and conditions of the Creative Commons Attribution (CC BY) license (http://creativecommons.org/licenses/by/4.0/).

To cite this article: Kolbas I, Sonmez Topcu F, Karatekin B, Ozkan B. Diaphragm elevation after lobectomy: defining its extent, duration, and diagnostic significance. Curr Thorac Surg 2025;10(2):49-56.

Original Article

Diaphragm elevation after lobectomy: defining its extent, duration, and diagnostic significance

Ilker Kolbas[1]*, Feyza Sonmez Topcu[2], Berivan Karatekin[3], Berker Ozkan[4]

[1] Department of Thoracic Surgery, Istanbul Aydın University, Medical Faculty, Istanbul, Turkey
[2] Department of Radiology, Istanbul Aydın University, Medical Faculty, Istanbul, Turkey
[3] Department of Pulmonology, Istanbul Aydın University, Medical Faculty, Istanbul, Turkey
[4] Department of Thoracic Surgery, Istanbul University, Medical Faculty, Istanbul, Turkey

ABSTRACT

Background: Diaphragmatic elevation is among the earliest compensatory changes following lung resection; however, its extent and duration remain inadequately defined.

Materials and Methods: A retrospective analysis was conducted on 198 patients who underwent surgical treatment for non-small cell lung cancer between January 2022 and June 2023. Of these, 102 patients who underwent upper or lower lobectomy were included in the study. Diaphragmatic position was assessed using chest radiographs obtained preoperatively and on postoperative days 1, 10, and 30. Measurements were performed by independent radiologists and compared according to surgical approach (VATS vs. thoracotomy), lobectomy location (upper vs. lower), and operative side (right vs. left).

Results: Significant diaphragmatic elevation was observed on the first postoperative day and persisted through day 10. The mean difference between preoperative and postoperative day 1 measurements was 29.16 ± 12.93 mm ($p < 0.0001$). Partial recovery was noted by day 10 ($p < 0.001$). Both hemidiaphragms showed similar patterns, although the right hemidiaphragm demonstrated greater recovery. No significant associations were identified between diaphragmatic elevation and surgical approach, lobectomy location, or laterality ($p > 0.05$ for all comparisons).

Conclusions: Diaphragmatic elevation represents a normal anatomical adaptation in the early postoperative period following lung resection. Defining its expected extent and duration may facilitate the early recognition of postoperative complications. Larger-scale studies are warranted to establish definitive reference criteria for postoperative diaphragmatic elevation.

Keywords: diaphragm elevation, lobectomy, non-small cell lung cancer, postoperative radiographic changes, video-assisted thoracoscopic surgery, thoracic surgery outcomes

Corresponding Author*: Ilker Kolbas, MD, Istanbul Aydin Universitesi, Florya Medicalpark Hastanesi, Besyol, Inonu Cd. No:38, 34295, Kucukcekmece, Istanbul, Turkey.
E-mail: dr_ilkerkolbas@hotmail.com
Doi: 10.26663/cts.2025.011
Received 28.06.2025 accepted 11.08.2025

Introduction

Lung cancer remains one of the most frequently diagnosed malignancies worldwide, with an estimated 2.48 million new cases annually. It is also the leading cause of cancer-related mortality, accounting for approximately 1.79 million deaths each year [1,2].

For patients with early-stage non-small cell lung cancer (NSCLC), surgical resection is the primary treatment modality and the cornerstone of thoracic oncologic surgery. Lobectomy with ipsilateral mediastinal lymph node dissection is considered the gold standard surgical approach for NSCLC [3]. In addition to lobectomy, other procedures such as bilobectomy, sleeve lobectomy, and pneumonectomy may be performed; in addition, sublobar resections, including segmentectomy and wedge resection, are also indicated in selected cases [4-6]. In patients with locally advanced NSCLC, radical resection may be extended to involve adjacent structures such as the chest wall, major vessels, or the atrium [7].

Lung resections result in notable anatomical changes, including narrowing of the intercostal spaces, mediastinal shift toward the operated side, diaphragmatic elevation, and compensatory expansion of the contralateral lung [8]. These alterations are often visible on postoperative imaging and must be distinguished from pathological findings to avoid misdiagnosis and to promptly identify potential complications.

The aim of this study was to investigate the extent and duration of diaphragmatic elevation following lobectomy and to evaluate variations based on surgical side and type of resection. By defining normative postoperative patterns of diaphragmatic elevation, we seek to contribute to the early detection of postoperative complications.

Materials and Methods

This study was designed as a retrospective observational analysis. Between January 1, 2022, and June 30, 2023, a total of 198 patients who underwent surgical treatment for non-small cell lung cancer (NSCLC) at our institution were retrospectively reviewed. Patients who underwent segmentectomy (n = 16), wedge resection (n = 12), middle lobectomy (n = 7), bilobectomy (n = 11), or pneumonectomy (n = 8), as well as those with prolonged postoperative air leak (n = 9), those requiring reoperation (n = 6), or those who received neoadjuvant or adjuvant chemotherapy (n = 18) or chemo-immunotherapy (n = 9), were excluded. A total of 102 patients, including 63 female, met the inclusion criteria and were included in the final analysis. The study was conducted in accordance with the Declaration of Helsinki and ethical approval was obtained from the institutional review board.

Chest X-ray evaluation

The diaphragmatic position was evaluated using standard upright posteroanterior chest radiographs obtained during full inspiration at four time points: preoperatively (within one week prior to surgery) and on postoperative days 1, 10, and 30. Independent radiologists, blinded to clinical information and surgical details, measured the vertical distance (in millimeters) from the highest point of the hemidiaphragm to the thoracic apex on the ipsilateral side. Diaphragmatic elevation was compared across subgroups according to surgical approach (VATS vs. thoracotomy), operative side (right vs. left), and lobectomy location (upper vs. lower).

All radiographs were acquired with patients standing in full inspiration and facing the cassette. The x-ray tube was positioned 6 feet behind the patient, and patients were instructed to hold onto handles beside the cassette to move their arms away from the chest. Images were obtained during deep inspiration [9].

Outcome measures

The primary outcome measure was the change in the vertical distance from the diaphragm apex to the thoracic apex across time points. As illustrated in Figure 1, measurements were taken from chest radiographs at four time points: preoperative (A), postoperative day 1 (B), day 10 (C), and day 30 (D). Differences in diaphragm position were calculated between the following pairs: day 1 vs. preoperative, day 10 vs. preoperative, day 30 vs. preoperative, day 10 vs. day 1, day 30 vs. day 1, and day 30 vs. day 10.

Statistical Analysis

Statistical analyses were conducted using Python (version 3.12.4) with the pandas (2.2.3), NumPy (1.26.4), SciPy (1.11.4), Matplotlib (3.10.1), and Seaborn (0.13.2) libraries. For each timepoint comparison,

normality and variance homogeneity were assessed before selecting the appropriate statistical test. The Shapiro-Wilk test was used to assess normality, and Levene's test was employed to evaluate homogeneity of variances. For normally distributed data, paired t-test was used for within-subject comparisons, and independent t-test (or Welch's modification for unequal variances) for between-group comparisons. For non-normally distributed data, the Wilcoxon signed-rank test (paired samples) and the Mann-Whitney U test (unpaired samples) were applied. One-sample comparisons against reference values were done by t-test or Wilcoxon test, depending on the distribution.

Subgroup analyses were performed according to surgical technique (VATS vs. thoracotomy), lobectomy location (upper vs. lower), and operative side (left vs. right). Statistical significance was set at $p < 0.05$. Significance levels in figures are denoted as follows: *$p < 0.05$, **$p < 0.01$, and ***$p < 0.001$.

Results were visualized using bar charts with standard deviation error bars. Comparative analyses were presented using side-by-side visualizations with direct statistical annotations. Where applicable, dual y-axes were used to display both absolute distances and percentages normalized to preoperative values. All statistical comparisons between time points and subgroups were annotated in the corresponding figures.

Results

Between January 1, 2022, and June 30, 2023, we retrospectively analyzed 102 consecutive patients who underwent pulmonary lobectomy for non-small cell lung cancer at our institution. As detailed in Table 1, the study population included 63 females (61.8%) and 39 males (38.2%). Video-assisted thoracoscopic surgery (VATS) was performed in 71 patients (69.6%), while conventional thoracotomy was used in 31 cases (30.4%). The right hemithorax was involved in 69 procedures (67.6%) and the left in 33 (32.4%). Upper lobectomy was the most common procedure (71 patients, 69.6%), followed by lower lobectomy (31 patients, 30.4%).

Changes in diaphragm position

Figure 1 displays representative chest radiographs demonstrating the positional changes of the diaphragm relative to the thoracic apex. Figure 1A shows the preoperative baseline position. On postoperative day 1 (Figure 1B), marked diaphragmatic elevation is evident. Changes observed on day 10 (Figure 1C) and on day 30 (Figure 1D) are also shown.

Figure 2A presents the mean vertical distance from the diaphragm apex to the thoracic apex at each time point. The baseline preoperative value (214.19 ± 24.92 mm) significantly decreased on postoperative day 1 (185.03 ± 20.01 mm; 86.39% of baseline; $p < 0.01$). On day 10, a modest increase was recorded (190.52 ± 20.71 mm; 88.95% of baseline), which remained significantly lower than preoperative values ($p < 0.001$) but higher than day 1 ($p < 0.05$). Day 30 measurements (189.53 ± 20.54 mm; 88.49% of baseline) were also significantly reduced compared to baseline ($p < 0.001$) and differed significantly from day 1 ($p < 0.05$).

Figure 2B illustrates the magnitude of change across intervals. The most pronounced elevation occurred immediately after surgery, with a mean diaphragm elevation of 29.16 ± 12.93 mm from baseline to day 1 ($p < 0.0001$). A partial recovery of 5.49 ± 9.55 mm occurred between days 1 and 10 ($p < 0.0001$), and 4.50 ± 8.35 mm from day 1 to day 30 ($p < 0.0001$). No significant difference was detected between days 10 and 30 (-0.99 ± 5.37 mm; $p > 0.05$).

Table 1. Baseline characteristics of the patients and the procedures.

Characteristics	n=102
Age (years), mean ± SD	60.8 ± 12.9
Sex	
Female	63 (61.8%)
Male	39 (38.2%)
Surgical Approach	
VATS	71 (69.6%)
Thoracotomy	31 (30.4%)
Operation Side	
Left hemithorax	33 (32.4%)
Right hemithorax	69 (67.6%)
Lobectomy Location	
Upper lobectomy	71 (69.6%)
Lower lobectomy	31 (30.4%)

Unless otherwise stated, data presented as number (percentage). VATS, video-assisted thoracoscopic surgery

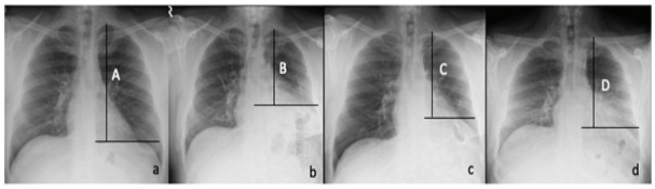

Figure 1. Representative chest radiographs showing diaphragm position changes following surgery. Serial chest radiographs demonstrate changes in diaphragm position relative to the thoracic apex. Preoperative baseline **(A),** postoperative day 1 **(B)**, postoperative day 10 **(C),** postoperative day 30 **(D).**

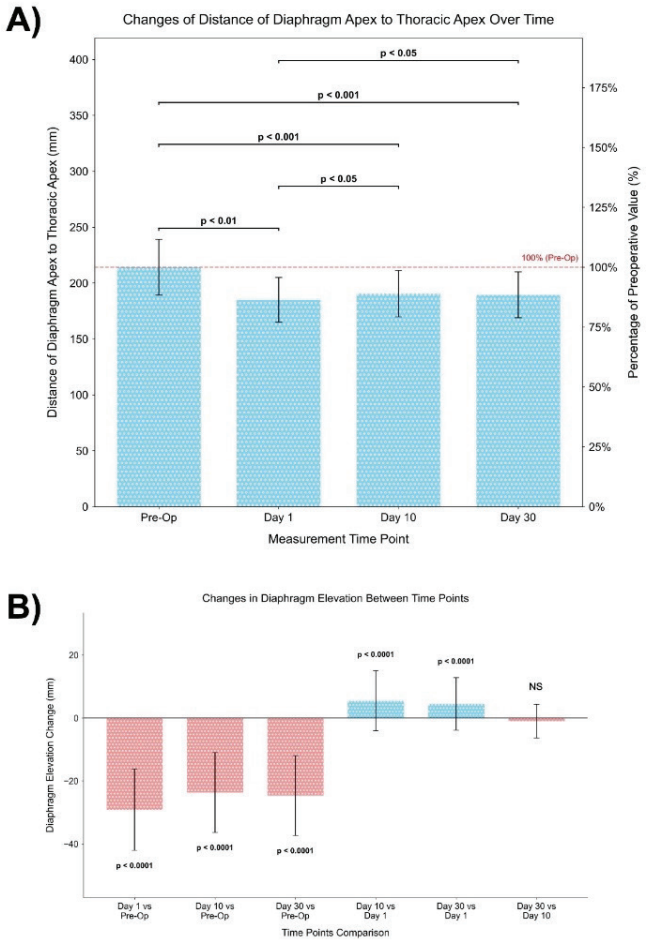

Figure 2. Quantitative analysis of diaphragm position changes over time following surgery. Bar graph showing the mean distance (± SD) from diaphragm apex to thoracic apex at preoperative baseline and postoperative days 1, 10, and 30. Left y-axis shows distance in millimeters; right y-axis displays percentage of preoperative baseline value (red dashed line = 100%). Brackets indicate statistical comparisons between time points with corresponding p-values **(A),** bar graph showing diaphragm position changes between time points. Negative values (red bars) represent diaphragm elevation relative to the compared time point; positive values (blue color bars) represent diaphragm descent (recovery). Error bars show standard deviation **(B).**

Left versus right hemidiaphragm

Figure 3A shows the quantitative analysis of diaphragm apex to thoracic apex distance on the left (n = 33) and right (n = 69) sides across all time points. Preoperatively, the right hemidiaphragm exhibited higher distance (215.67 ± 25.13 mm) than the left (211.09 ± 24.57 mm), but the difference was not statistically significant ($p > 0.05$).

On postoperative day 1, both sides exhibited significant elevation-183.12 ± 19.38 mm (left, 86.75% of baseline) and 185.94 ± 20.38 mm (right, 86.22% of baseline)-with no significant side-to-side difference ($p > 0.05$). By day 10, the right hemidiaphragm exhibited higher distance, but without a statistically significant difference (192.35 ± 20.82 mm vs. 186.70 ± 20.24 mm; $p > 0.05$). Similar findings were observed on day 30: 190.87 ± 20.85 mm (right) and 186.73 ± 19.89 mm (left; $p > 0.05$). Overall, diaphragm elevation patterns were bilaterally proportional with no statistically significant differences at any time point ($p > 0.05$).

As shown in Figure 3B, both sides experienced significant diaphragmatic elevation compared to preoperative values. The most substantial changes were seen on day 1: -27.97 ± 11.06 mm (left) and -29.72 ± 13.77 mm (right; $p < 0.001$ for both). This persisted on day 10 (left: -24.39 ± 11.33 mm; right: -23.32 ± 13.35 mm; $p < 0.001$) and day 30 (left: -24.36 ± 10.98 mm; right: -24.80 ± 13.49 mm; $p < 0.001$).

In Figure 3B, analysis of recovery patterns between consecutive time points revealed significant improvement in diaphragm position from day 1 to day 10 on both sides: 3.58 ± 9.60 mm for the left ($p < 0.05$) and 6.41 ± 9.45 mm for the right ($p < 0.001$), with the right side exhibiting more pronounced recovery. No significant changes were observed between days 10 and 30 for either the left (0.03 ± 2.82 mm, $p > 0.05$) or right side (-1.48 ± 6.19 mm, $p > 0.05$). Change in elevation between day 1 and day 30 was significant for both the left (3.61 ± 8.49 mm, $p < 0.05$) and right sides (4.93 ± 8.31 mm, $p < 0.001$). Although both sides showed improvement during this period, the diaphragm position remained significantly elevated compared to preoperative measurements on day 30. Notably, the right side exhibited a more statistically significant degree of recovery between day 1 and day 30 ($p < 0.001$) compared to the left side ($p < 0.05$).

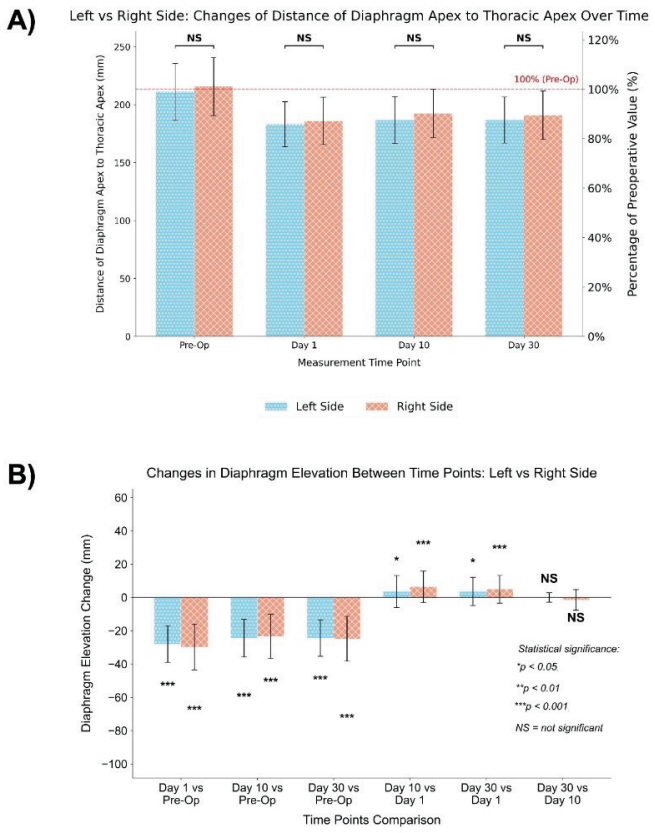

Figure 3. Comparison of left versus right hemidiaphragm positions and changes over time. Bar graph comparing the distance from diaphragm apex to thoracic apex between left (blue color) and right (salmon color) sides at preoperative baseline and postoperative days 1, 10, and 30. Left y-axis shows distance in millimeters; right y-axis displays percentage of preoperative baseline value (red dashed line = 100%) **(A)**, bar graph showing the magnitude and direction of diaphragm position changes between time points for left (blue color) and right (salmon color) sides. Negative values represent diaphragm elevation; positive values represent diaphragm descent (recovery). Error bars show standard deviation. Statistical significance is indicated by asterisks (* $p < 0.05$; ** $p < 0.01$; *** $p < 0.001$; NS = not significant) **(B)**.

Comparison by surgical approach

Figure 4A compares diaphragm position by surgical approach. Baseline values for diaphragm-to-thoracic apex distance were comparable between the VATS (213.73 ± 24.38 mm) and thoracotomy groups (215.23 ± 26.49 mm; $p > 0.05$).

In Figure 4A, both groups demonstrated a similar pattern of diaphragm elevation following surgery. On day 1, elevation occurred in both groups (VATS: 184.73 ± 20.13 mm, 13.6% reduction; thoracotomy: 185.71 ± 20.03 mm, 13.7% reduction), with no significant difference ($p > 0.05$) (Figure 4A).

At postoperative day 10, partial recovery of diaphragm position was observed in both groups, with mean distances of 191.01 ± 20.05 mm in the VATS group and 189.39 ± 22.44 mm in the thoracotomy group, corresponding to 89.4% and 88.0% of preoperative values, respectively. No significant difference was found between the two surgical approaches ($p > 0.05$).

By postoperative day 30, the diaphragm position measured 189.72 ± 20.00 mm in the VATS group and 189.10 ± 22.06 mm in the thoracotomy group, representing 88.8% and 87.9% of baseline values, respectively. Again, no significant difference was observed between the groups ($p > 0.05$). These findings suggest that the choice of surgical approach (VATS or thoracotomy) did not significantly affect the extent of postoperative diaphragm elevation or its recovery pattern over the 30-day follow-up period.

Figure 4B illustrates diaphragmatic changes within and between time points by surgical technique. Both groups showed significant decreases in distances from baseline on all postoperative days (VATS: -29.00 ± 12.49 mm, -22.72 ± 11.74 mm, -24.01 ± 12.25 mm; thoracotomy: -29.52 ± 14.08 mm, -25.84 ± 14.62 mm, -26.13 ± 13.72 mm; all $p < 0.001$).

In Figure 4B, both groups exhibited significant partial recovery of diaphragmatic elevation between postoperative day 1 and subsequent time points. In the VATS group, the diaphragm position improved by 6.28 ± 9.63 mm between days 1 and 10 ($p < 0.001$) and by 4.99 ± 8.58 mm between days 1 and 30 ($p < 0.001$). Similarly, the thoracotomy group demonstrated significant recovery, with increases of 3.68 ± 9.24 mm from day 1 to day 10 ($p < 0.05$) and 3.39 ± 7.80 mm from day 1 to day 30 ($p < 0.05$). No significant change occurred between days 10 and 30 in either group (VATS: -1.30 ± 5.58 mm; thoracotomy: -0.29 ± 4.88 mm; $p > 0.05$) (Figure 4B).

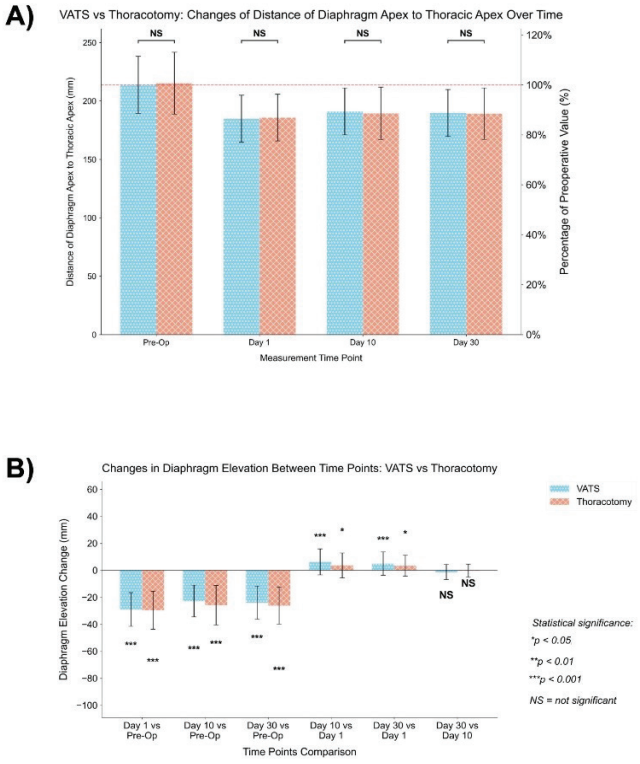

Figure 4. Comparison of diaphragm position changes between VATS and thoracotomy surgical approaches. Bar graph comparing the distance from diaphragm apex to thoracic apex between VATS (blue color) and thoracotomy (salmon color) groups at preoperative

baseline and postoperative days 1, 10, and 30. Left y-axis shows distance in millimeters; right y-axis displays percentage of pre-operative baseline value (red dashed line = 100%) **(A),** bar graph showing the magnitude and direction of diaphragm position changes between time points for VATS (blue color) and thoracotomy (salmon color) groups. Negative values represent diaphragm elevation; positive values represent diaphragm descent (recovery). Error bars show standard deviation. Statistical significance is indicated by asterisks (* $p < 0.05$; ** $p < 0.01$; *** $p < 0.001$; NS = not significant) **(B)**.

Upper vs. lower lobectomy

In Figure 5A, the distance from the diaphragm apex to the thoracic apex was compared between patients who underwent upper lobectomy (n = 71) and those who underwent lower lobectomy (n = 31), at four time points. At baseline, both groups exhibited similar preoperative diaphragm positions (upper: 214.79 ± 25.34 mm; lower: 212.81 ± 24.27 mm; $p > 0.05$).

On postoperative day 1, both groups demonstrated significant decreases in diaphragm-to-thoracic apex distance, indicating diaphragmatic elevation. The mean distances were 184.83 ± 20.56 mm for the upper lobectomy group and 185.48 ± 19.00 mm for the lower lobectomy group, with no statistically significant difference between them ($p > 0.05$). This pattern persisted on day 10 (upper: 190.90 ± 20.69 mm; lower: 189.65 ± 21.07 mm; $p > 0.05$) and day 30 (upper: 190.80 ± 20.80 mm; lower: 186.61 ± 19.95 mm; $p > 0.05$). Notably, by day 30, neither group had returned to their baseline diaphragm position, with the diaphragm-to-apex distance remaining at approximately 89% of the preoperative value in the upper lobectomy group and 88% in the lower lobectomy group.

Figure 5B presents the changes in diaphragm elevation across time points for upper and lower lobectomy patients. Both groups showed highly significant diaphragmatic elevation immediately after surgery, with diaphragm-to-thoracic apex distance decreases of -29.96 ± 12.58 mm in the upper lobectomy group and -27.32 ± 13.73 mm in the lower lobectomy group ($p < 0.001$, for both). This elevation persisted through postoperative days 10 and 30, with measurements remaining significantly different from baseline in both groups (all $p < 0.001$).

Between days 1 and 10, both groups exhibited statistically significant recovery: 6.07 ± 8.73 mm for the upper lobectomy group ($p < 0.001$) and 4.16 ± 11.24 mm for the lower lobectomy group ($p < 0.05$) (Figure 5B). However, a notable difference emerged between days 1 and 30. The upper lobectomy group showed continued significant improvement (5.97 ± 8.47 mm, $p < 0.001$), whereas the lower lobectomy group demonstrated a smaller, statistically non-significant change (1.13 ± 7.10 mm, $p > 0.05$). Between days 10 and 30, neither group showed significant recovery (upper: -0.10 ± 3.77 mm, $p > 0.05$; lower: -3.03 ± 7.60 mm, $p > 0.05$).

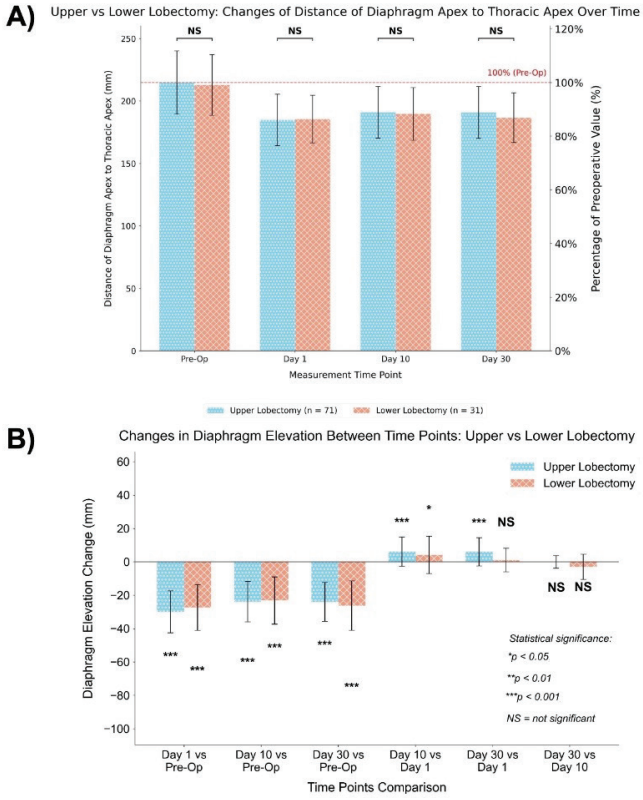

Figure 5. Comparison of diaphragm position changes between upper and lower lobectomy procedures. Bar graph comparing the distance from diaphragm apex to thoracic apex between upper lobectomy (blue color) and lower lobectomy (salmon color) groups at preoperative baseline and postoperative days 1, 10, and 30. Left y-axis shows distance in millimeters; right y-axis displays percentage of preoperative baseline value (red dashed line = 100%) **(A),** bar graph showing the magnitude and direction of diaphragm position changes between time points for upper lobectomy (blue color) and lower lobectomy (salmon color) groups. Negative values represent diaphragm elevation; positive values represent diaphragm descent (recovery). Error bars show standard deviation. Statistical significance is indicated by asterisks (* $p < 0.05$; ** $p < 0.01$; *** $p < 0.001$; NS = not significant) **(B).**

Discussion

Lung cancer remains the leading cause of cancer-related mortality worldwide. According to GLOBOCAN 2022, there were approximately 2.48 million new cases and 1.81 million deaths attributed to lung cancer, reflecting a nearly 20% increase in incidence compared to previous data [1,10]. Surgical resection remains the corner-

stone of treatment for stage I and II non-small cell lung cancer (NSCLC) [11,12]. Consequently, the growing incidence of lung cancer and the increased application of surgical management have led to a greater number of patients undergoing lung resection.

Postoperative follow-up in these patients who have undergone lung resection typically begins with chest radiographs, while computed tomography (CT) is more commonly used for evaluating recurrence and late complications. Radiological findings in the early postoperative period often reflect expected anatomical adaptations to lung resection, such as minor pneumothorax or hydropneumothorax, parietal emphysema, hemithorax retraction. Over few days to weeks, additional compensatory changes include expansion of the remaining lung lobes, blunting of the costodiaphragmatic angle, and elevation of the diaphragm and hilar structures, as well as a mediastinal shift towards the operated side [5]. These changes result in progressive anatomical modifications of the thoracic cavity depending on the type of resection. Correct interpretation of these normal postoperative radiological findings is essential to avoid misdiagnosis and to detect early complications [13]. For instance, excessive diaphragmatic elevation may suggest phrenic nerve injury, whereas insufficient elevation may point to complications such as pneumothorax, hemothorax, or expansion defects.

Following lung resection, the diaphragm rapidly adapts to the changing thoracic volume, resulting in early elevation. However, this phenomenon is largely assessed subjectively, and there is no widely accepted quantitative standard for its evaluation [14]. Furthermore, the expected duration and extent of diaphragmatic elevation have not been clearly defined in the literature. In our study, we observed that most of the compensatory diaphragmatic elevation occurred within the first 10 postoperative days (Figures 2A, B).

The diaphragm is a striated muscle that separates the thoracic and abdominal cavities, attaching from the xiphoid process of the sternum to the 7th through 12th ribs, with a central tendon shaped like a dome. Its primary function is assisting ventilation [9,15,16]. On a posteroanterior chest X-ray, the dome of the diaphragm is positioned at the level of the 5th to 7th ribs along the midclavicular line. In most individuals, the right hemidiaphragm lies 1.5 to 2.5 cm higher than the left hemidiaphragm [9,17]. Diaphragmatic eventration is defined as abnormal elevation of a portion or the entire hemidiaphragm due to loss of muscle or nerve function, while anatomical continuity is preserved [18]. This condition is typically partial, involving one-third to one-half of the hemidiaphragm, and appears radiographically as a smoothly contoured elevation. Eventration is more frequently observed on the left side but may progress to total diaphragmatic elevation over time [9]. Diaphragmatic elevation observed after thoracic surgery is caused by the retraction of the hemithorax, whereas diaphragmatic elevation developing after cardiac surgery is due to phrenic nerve damage and the mechanism of occurrence is completely different [19]. In our study, compensatory elevation was significantly greater on the right side (Figure 3B).

Although lung resection has traditionally been performed via thoracotomy, advances in camera systems and surgical instruments have improved the feasibility of video-assisted thoracic surgery (VATS), allowing for smaller incisions, shorter operative times, and enhanced safety. Consequently, the use of VATS has become increasingly common [10]. Thoracoscopic surgery offers several advantages, including shorter hospital stays, reduced chest tube duration, lower postoperative pain, better preservation of pulmonary function, decreased cytokine release, and a lower overall complication rate [11]. In our study, no significant effect of surgical technique on diaphragmatic elevation was observed (Figure 4B). The diaphragm movement that develops due to thoracic surgery is a compensatory elevation, it is not affected by the inflammatory response created by the surgical technique.

In conclusion, diaphragmatic elevation in patients undergoing lung resection occurs predominantly on the first postoperative day and continues until approximately day 10. The absence or excessive presence of this elevation may serve as a supportive indicator for the early detection of postoperative complications. Large-scale studies are needed to determine the standardization of postoperative diaphragm elevation.

Declaration of conflicting interests

The authors declared no conflicts of interest with respect to the authorship and/or publication of this article.

Funding

The authors received no financial support.

Ethics approval

This study was approved by Istanbul Aydin University Non-invasive Research Ethics Committee with protocol number 102-2025.

Authors' contribution

IK,BK; made substantial contributions to the design of the work, IK,BK,FST; made the analysis of data, FST,BO; made the creation of new software used in the work, IK,BK,FST; have drafted the work, IK,BO; revised it. All authors read and approved the fnal manuscript.

References

1. Bray F, Laversanne M, Sung H, Ferlay J, Siegel RL, Soerjomataram I et al. Global cancer statistics 2022: GLOBOCAN estimates of incidence and mortality worldwide for 36 cancers in 185 countries. CA Cancer J Clin 2024; 74: 229-63.
2. Thai AA, Solomon BJ, Sequist LV, Gainor JF, Heist RS. Lung cancer. Lancet 2021; 398: 535-54.
3. Aokage K, Suzuki K, Saji H, Wakabayashi M, Kataoka T, Sekino Y et al. Segmentectomy for ground-glass-dominant lung cancer with a tumour diameter of 3 cm or less including ground-glass opacity (JCOG1211): a multicentre, single-arm, confirmatory, phase 3 trial. Lancet Respir Med 2023; 11: 540-9.
4. Saji H, Okada M, Tsuboi M, Nakajima R, Suzuki K, Aokage K et al. Segmentectomy versus lobectomy in small-sized peripheral non-small-cell lung cancer (JCOG0802/WJOG4607L): a multicentre, open-label, phase 3, randomised, controlled, non-inferiority trial. Lancet 2022; 399: 1607-17.
5. Burel J, El Ayoubi M, Baste JM, Garnier M, Montagne F, Dacher JN, et al. Surgery for lung cancer: postoperative changes and complications-what the Radiologist needs to know. Insights Imaging 2021; 12: 116.
6. Berthet JP, Paradela M, Jimenez MJ, Molins L, Gomez-Caro A. Extended sleeve lobectomy: one more step toward avoiding pneumonectomy in centrally located lung cancer. Ann Thorac Surg 2013; 96: 1988-97.
7. Speicher PJ, Englum BR, Ganapathi AM, Onaitis MW, D'Amico TA, Berry MF. Outcomes after treatment of 17,378 patients with locally advanced (T3N0-2) non-small-cell lung cancer. Eur J Cardiothorac Surg 2015; 47: 636-41.
8. Simsek B, Ozyuksel A, Saygi M, Bilal MS. Plication for diaphragm paralysis after paediatric cardiac surgery: a single-centre experience. Cardiol Young 2023; 33: 2087-93.
9. Kalra MK. Thoracic imaging. In: Shepard JAO, Abbott GF, Ackman JB, et al., eds. Thoracic Imaging: The Requisites. Philadelphia: Elsevier; 2019.
10. Kolbas I, Tezel C, Ozturk A, Alpay L, Evman S. Does VATS Lobectomy Avoid Delay and Increase Compliance in Adjuvant Chemotherapy? Turk J Oncol 2022; 37: 388-93.
11. Howington JA, Blum MG, Chang AC, Balekian AA, Murthy SC. Treatment of stage I and II non-small cell lung cancer: Diagnosis and management of lung cancer, 3rd ed: American College of Chest Physicians evidence-based clinical practice guidelines. Chest 2013; 143(5 Suppl): e278S-e313S.
12. Paul S, Altorki NK, Sheng S, Lee PC, Harpole DH, Onaitis MW et al. Thoracoscopic lobectomy is associated with lower morbidity than open lobectomy: a propensity-matched analysis from the STS database. J Thorac Cardiovasc Surg 2010; 139: 366-78.
13. Bommart S, Berthet JP, Durand G, Ghaye B, Pujol JL, Marty-Ane C et al. Normal postoperative appearances of lung cancer. Diagn Interv Imaging 2016; 97: 1025-35.
14. Ventura L, Zhao W, Chen T, Wang Z, Feng J, Gu Z, et al. Significant diaphragm elevation suggestive of phrenic nerve injury after thoracoscopic lobectomy for lung cancer: an underestimated problem. Transl Lung Cancer Res 2020; 9: 1822-31.
15. Hamer OW, Sirlin CB, Strotzer M, Brisch I, Zorger N, Feuerbach S et al. Chest radiography with a flat-panel detector: image quality with dose reduction after copper filtration. Radiology 2005; 237: 691-700.
16. Nason LK, Walker CM, McNeeley MF, Burivong W, Fligner CL, Godwin JD. Imaging of the diaphragm: anatomy and function. Radiographics 2012; 32: E51-70.
17. Shah-Mirany J, Schmitz GL, Watson RR. Eventration of the diaphragm. Physiologic and surgical significance. Arch Surg 1968; 96: 844-50.
18. Agarwal AK, Lone NA. Diaphragm Eventration. StatPearls 2024; http://www.ncbi.nlm.nih.gov/books/NBK560497/.
19. Kokatnur L, Rudrappa M. Diaphragmatic Palsy. Diseases 2018; 6: 16.

This article is an open access article distributed under the terms and conditions of the Creative Commons Attribution (CC BY) license (http://creativecommons.org/licenses/by/4.0/).

To cite this article: Tanrıkulu G, Sevinc TE, Melek H, Yenturk E, Ozer E, Acet Ozturk NA, Ursavas A, Gebitekin C, Bayram AS. 22 years of surgical experience in non-cystic fibrosis bronchiectasis; what has changed in the last 10 years? Curr Thorac Surg 2025;10(2):57-63.

Original Article

22 years of surgical experience in non-cystic fibrosis bronchiectasis; what has changed in the last 10 years?

Gamze Tanrıkulu*[1], Tolga Evrim Sevinc[2], Hüseyin Melek[2], Eylem Yenturk[3], Erhan Ozer[4], Nilufer Aylin Acet Ozturk[5], Ahmet Ursavas[5], Cengiz Gebitekin[2], Ahmet Sami Bayram[2]

[1] Department of Thoracic Surgery, Gülhane Training and Research Hospital, Ankara, Turkiye
[2] Department of Thoracic Surgery, Uludag University Faculty of Medicine, Bursa, Turkiye
[3] Thoracic Surgery Clinic, Luleburgaz State Hospital, Tekirdag, Turkiye
[4] Thoracic Surgery Clinic, Cekirge State Hospital, Bursa, Turkiye
[5] Department of Pulmonary Diseases, Uludag University Faculty of Medicine, Bursa, Turkiye

ABSTRACT

Background: This study was conducted to examine the change and results of our experience in bronchiectasis surgery.

Materials and Methods: The records of the patients who were operated for bronchiectasis between January 2000 and January 2022 were analyzed retrospectively. Patients were grouped according to the time of surgery (Group I: Jan 2000- Jan 2012 vs. Group II: Jan 2021- Jan 2022) and surgical approach (thoracoscopy vs. thoracotomy). Demographic and clinical characteristics of the patients, localization of bronchiectasis, surgical interventions and postoperative follow-up results were recorded and analyzed using SPSS 25.

Results: A total of 220 operations were performed. Eighty-six patients (39.1%) were male, mean age was 34.89 ±12.68 years. Bronchiectasis was mostly located in the lower lobes (55.9%). The most frequently performed resection was left lower lobectomy (44.5%). The mean tube extraction time was 4.78 ± 4.13 days, and the mean length of hospital stay was 5.88 ± 3.18 days. Patients who underwent thoracoscopy had significantly shorter hospital stays and lower complication rates compared to those who underwent thoracotomy ($p = 0.001$ and $p = 0.004$, respectively). Patients operated on in the last 10 years (Group II) had significantly fewer complications compared to those operated in the earlier 12-year period (Group I) ($p = 0.028$). Multiple logistic regression analysis revealed that VATS reduced the complication rates by 82.5%. No surgical mortality was observed, and the overall morbidity rate was 26.8%.

Conclusions: Bronchiectasis surgery is very beneficial in patients who do not respond to medical treatment. Due to the effects of developing technology and experience gained, successful results have been achieved with minimally invasive approaches in recent years.

Keywords: videothoracoscopy, non-cystic fibrosis bronchiectasis, thoracotomy, logistic regression

Corresponding Author*: Gamze Tanrıkulu, MD. Gülhane Training and Research Hospital, Department of Thoracic Surgery, Ankara, Turkiye.
E-mail: gamzece019@hotmail.com Phone: +90 5077046416
Doi: 10.26663/cts.2025.012
Received 07.05.2025 accepted 11.08.2025

Introduction

Bronchiectasis is a progressive disease that develops as a result of impaired mucociliary clearance, accompanied by abnormal obstruction or dilatation in the bronchi, often due to chronic persistent infections [1]. Patients commonly present with cough, purulent sputum, halitosis, dyspnea, chest pain or recurrent episodes of hemoptysis. The primary goals of treatment are to prevent exacerbations, relieve symptoms, improve quality of life and halt disease progression [2].

Surgical intervention is considered a highly effective treatment option for patients with localized disease or those unresponsive to medical therapy [3]. In recent years, with advances technology, the use of video-assisted thoracoscopic surgery (VATS) in the treatment of bronchiectasis has become increasingly widespread. VATS is often preferred due to its association with improved patient comfort and acceptable complication rates and shorter hospital stays [4].

Although thoracotomy remains a well-established approach in bronchiectasis surgery and has been widely discussed in the literature, studies directly comparing thoracotomy with minimally invasive methods such as VATS are still relatively limited.

In this study, we aimed to present our surgical experience in the management of bronchiectasis, highlight the evolution of our perioperative approach, and evaluate the clinical outcomes of VATS and thoracotomy over a 22-year period.

Materials and Methods

The medical records of patients who underwent surgery for bronchiectasis at our thoracic surgery clinic between 1st January 2000 and 1st January 2022 were retrospectively reviewed. A total of 223 operations were performed. Two patients with cystic fibrosis who were operated for massive hemoptysis and one patient with a positive sweat test were excluded. The final study cohort included 220 patients.

To assess the clinical effects of the surgical approaches, patients were divided into two groups: those who underwent thoracotomy and those who underwent video-assisted thoracoscopic surgery (VATS). In a secondary analysis, patients were grouped based on the time of surgery: those operated on during the last 10 years (Jan 2012-Jan 2022) and those operated on in the preceding decade (Jan 2000-Jan 2012) to reveal how clinical experience was reflected in the results.

All patients were diagnosed based on high resolution computed tomography (HRCT) following detailed medical history and physical examination findings. Surgical treatment requirements were evaluated in the council held jointly with the pulmonologists. In the preoperative period, complete blood counts, biochemical parameters and pulmonary function tests (PFTs) were observed in all patients. In our clinic, attention was paid to ensure that the FEV1 (Forced expiratory volume in the first second) value was above 2L in patients who were planned for pneumonectomy, and lobectomy was avoided below 1.5L FEV1 level.

Indications for surgery included localized disease unresponsive to adequate medical treatment, hemoptysis, infections requiring hospitalization, and a history of more than three infections per year. In cases presenting with massive hemoptysis, embolization was the preferred initial intervention; elective surgery was scheduled once bleeding was controlled.

Patients with adequate functional capacity, as determined by radiological findings and PFTs were deemed eligible for surgery. Particularly over the past 10 years, patients with systemic symptoms underwent surgery after treatment of acute exacerbations. Routine sputum culture was taken from asymptomatic patients 2-4 weeks before the operation. Flexible/rigid bronchoscopy was performed in patients when deemed necessary, and sputum acid-fast bacilli (AFB) testing was studied. Among patients treated prior to 2012; sputum cultures were taken only if symptoms were present in the preoperative period. Antibiotic therapy was initiated two weeks prior to surgery based on culture results.

Surgical approaches included posterolateral thoracotomy or biportal VATS via the 4th and 7th intercostal spaces were preferred as incisions. The extent of resection -wedge resection, segmentectomy, lobectomy or pneumonectomy- was determined by disease severity. All patients were monitored in the surgical intensive care unit for 24 hours postoperatively before being transferred to the ward. Postoperative histopathological confirmation of bronchiectasis was obtained in all patients.

Patients were scheduled for outpatient follow-up on the 10th day after discharge. Subsequent annual check-

ups were conducted by pulmonologists. Clinical status and symptoms were documented during follow-up visits or by telephone interviews. The study was approved by the Ethics Committee of the Uludağ University Experimental Medicine Research Institute (2011-KAEK-26/553).

Statistical Analysis

Statistical analysis was performed using Statistical Package for the Social Sciences (SPSS) for Windows version 25.0. The Shapiro Wilk test was used to assess normality of distribution. A p-value of <0.05 was considered statistically significant. Normally distributed variables were analyzed using Student's t-test, while non-normally distributed variables were using the Mann-Whitney U test. Categorical variables were compared using the chi-square test. When interpreting the results, p value <0.05 was considered statistically significant with a 95% confidence interval (CI). Preoperative deaths occurring within 90 days were classified as surgical mortality.Logistic regression analysis was used to identify independent risk factors for postoperative. In the logistic regression analysis, the postoperative complication was taken as the dependent variable and gender, age, FEV1 levels, VATS, pneumonectomy, presence of frequent infections, hemoptysis, cough and sputum as independent variables.

Results

The surgical outcomes and perioperative data of 220 patients who underwent bronchiectasis surgery were analyzed to assess the impact of different surgical approaches and changes over time.

Eighty-six of the patients (39.1%) were male, with a mean age was 34.89 ± 12.68 years. The mean duration of chest tube drainage was 4.78 ± 4.13 days, and the mean length of hospital stay was 5.88 ± 3.18 days. Histopathological examination confirmed the diagnosis of bronchiectasis in all resected specimens.

The most common symptoms were cough and sputum (66.4%), while 28.2% of patients underwent surgery due to hemoptysis. A history of infections (≥3 per year) was present in 39.1% of patients (Table 1). Bronchiectasis was mostly located in the lower lobes (55.9%) and in the left lung (51.4%), with bilateral disease observed in 25% of cases. Bilateral surgical intervention was performed in 9.4% of the patients (Table 1).

Table 1. Demographic data of the patients.

Age (Mean±SD) (Min-max)	34.89±12.68(11-69)
0-17 n (%)	16(7.3)
18-40	133(60.5)
41-64	70(31.8)
>65	1(0.5)
Gender	n(%)
Male	86(39.1)
Female	134(60.9)
FEV1 (L) (Mean±SD)	2.35±0.80
FEV1 (%)	75.19±19.93
DLCO (%)	75.65±13.59
Affected side	n(%)
Left	113(51.4)
Right	32(39.2)
Bilateral	55(9.4)
Symptoms	n(%)
Recurrent infection	86(39.1)
Cough, sputum	146(66.4)
Hemoptysis	62(28.2)
Childhood pneumonia attacks	31(14.09)
Smoking history	n(%)
Yes	55(25)
No	165(75)

Abbrev.; FEV1: Forced expiratory volume in 1 second, DLCO: Diffusing capacity of the lungs for carbon monoxide

While the patients were preparing for the operation in the preoperative period, flexible/rigid bronchoscopy was performed to detect the bleeding focus in 15 patients who presented with the complaint of hemoptysis and had bilateral bronchiectasis on thorax CT. One patient with AFB positivity was operated after antituberculosis treatment. Emergency thoracotomy and right lower lobectomy were performed in one patient due to massive hemoptysis. Other patients with hemoptysis were operated under elective conditions after the bleeding was stopped with medical treatment or embolization.

Thoracotomy was performed in 166 patients (75.7%), and VATS in 54 patients (24.3%), with conversion to thoracotomy required in six patients due to pleural adhesions (n = 4) or vascular injury (n = 2). In the last two years, all 18 VATS cases were completed successfully without conversion.

The most frequently performed procedure was lobectomy (79.1%), particularly left lower lobectomy. Pneumonectomy was required in nine patients (Table 2). Completion resections were performed in seven patients due to recurrence or progression. No perioperative or 90-day mortality was observed; late mortality occurred in seven patients, three of whom died due to pneumonia.

Table 2. Surgical data of the patients.	
Surgical Technique	n(%)
Thoracotomy	172(78.2)
VATS	48(21.8)
Conversion to thoracotomy from VATS	6(2.7)
Comorbidity	63(28.6)
Asthma	19(8.6)
Hypertension	15(6.8)
Diabetes	14(6.4)
İmmotile Cilia Syndrome	10(4.5)
COPD	3(1.4)
CAD	3(1.4)
Other	12(5.4)
Complication	62(26.8)
PAL	23(37.10)
Expansion deficit	9(14.52)
Hematoma	5(8.06)
Pneumothorax	3(4.84)
Atelectasis	10(16.13)
Pneumonia	6(9.68)
Surgical site infection	4(6.45)
Empyema, BPF	2(3.22)
Drain removal, day	4.78±4.13(1-40)
Hospitalization, day	5.88±3.18(3-23)
90 day mortality	0(0)
Late mortality	7(%3.2)
Postoperative complaints	
None	164(74.5)
Lessened	47(21.4)
Recurrence	9(4.1)

Abbrev.; COPD: Chronic obstructive pulmonary disease, CAD: Coronary Artery Disease, PAL: Prolonged air leak; persists for more than 5 days postoperatively, BPF: Bronchopleural fistula

Postoperative complication rates of the patients are presented in Table 3. Bronchoscopy was performed in cases with secretion-related atelectasis. Five patients required surgical exploration for hematoma.

Drain extraction times and hospital stays of patients who underwent resection with thoracotomy and patients who underwent resection with VATS were compared. Patients undergoing VATS had significantly shorter hospital stays (4.8 ± 1.8 vs. 6.2 ± 3.4 days, p = 0.001) and chest tube durations (3.3 ± 1.4 vs. 5.3 ± 4.6 days, p < 0.001), and lower complication rates (p = 0.004) compared to thoracotomy (Table 4).

Since 2012, a total of 106 bronchiectasis operations have been performed. During the preoperative preparation period, 41 patients with acute exacerbations were referred to the pulmonology department for treatment. Among 65 asymptomatic patients tested preoperatively, sputum culture positivity was detected in 27 cases (41.54%). Pseudomonas aeruginosa was isolated in 10 patients, while Haemophilus influenzae was identified in 9 patients. Following targeted antimicrobial therapy, no postoperative complications were observed in these patients, except for one case of prolonged air leak.

Compared to the earlier decade, the last 10 years showed significantly improved outcomes, with shorter chest tube durations (p = 0.013) and reduced complication rates (p = 0.028) (Table 5).

Table 3. Frequency distribution table of the resection characteristics of the patients.	
Resection	n(%)
Wedge	9(4.1)
Segmentectomy	16(7.3)
Lobectomy	186(84.5)
Pneumonectomy	9(4.1)
Lung resection type	
LLL1	98(44.5)
LUL2	7(3.2)
RUL3	11(5)
RML4 / LML5	39(17.7)
RLL6	19(8.6)
LP7	7(3.2)
RP8	2(0.9)
Segmentectomy	16(7.3)
Wedge	9(4.1)
Bilobectomy	12(5.5)

1: Left lower lobectomy, 2: Left upper lobectomy, 3: Right upper lobectomy, 4: Right middle lobectomy, 5: Left middle lobectomy, 6: Right lower lobectomy, 7: Left pneumonectomy, 8: Right pneumonectomy

Table 4. Comparison of patients by surgical technique.			
	VATS (n=48)	Thoracotomy (n=172)	p
Age, year (Mean±SD)	34.69±13.47	34.95±12.49	0.81
Gender, n(%)	15(31.25)	71(41.28)	0.21
FEV1 (L) (Mean±SD)	2.32±0.86	2.40±0.75	0.69
FEV1 (%)	79.13±19.26	72.47±20.10	0.11
DLCO (%)	76.33±12.57	74.71±15.14	0.66
Resection	n(%)	n(%)	
Wedge	1(2.1)	8(4.7)	
Segmentectomy	5(10.4)	11(6.4)	
Lobectomy	42(87.5)	144(83.7)	0.56
Pneumonectomy, n(%)	0(0.0)	9(5.2)	
Comorbidity	19(39.5)	44(25.6)	0.045
Smoking	10(20.8)	45(26.2)	0.29
Complication	6(12.5)	56(32.56)	0.004*
Drain removal, day(Mean±SD)	3.3±1.37	5.25±4.6	0.001*
Hospitalization, day(Mean±SD)	4.8±1.8	6.2±3.4	0.001*

Table 5. Last 10 years of experience vs. previous years.

	First 12 years (n=114) (Group I)	Last 10 years (n=106) (Group II)	P
Age (Mean±SD)	34.1±11.8	35.7±13.6	0.48
Gender, n (%)	50(43.9)	36(33.96)	0.086
FEV (L) (Mean±SD)	2.29±0.95	2.38±0.72	0.54
FEV1 (%)	68.26±19.60	78.66±19.32	0.03*
DLCO (%)	75±5.65	75.7±13.84	0.94
Surgical Technique	n(%)	n(%)	
Thoracotomy VATS Conversion to thoracotomy	113(99.1) 1(0.9) 0(0.0)	59(55.7) 47(44.3) 6(5.7)	0.001*
Resection	n(%)	n(%)	
Wedge Segmentectomy Lobectomy Pneumonectomy	7(6.1) 7(6.1) 93(81.6) 7(6.1)	2(1.9) 6(4.7) 93(87.7) 2(1.9)	0.16
Complications, n (%)	39(34.2)	23(21.7)	0.028*
Drain removal, days (Mean±SD)	4.96±3.1	4.63±4.85	0.013*
Hospitalization (Mean±SD)	6.03±3.1	5.75±3.3	0.1
Mortality, n (%)	7(6.1)	0	0.01*
Postop symptoms	n(%)	n(%)	
None Lessened Recurrence	82(71.9) 26(22.8) 6(5.3)	82(77.4) 21(19.8) 3(2.8)	0.28

The sweat test performed in the preoperative period was negative in all patients in the pediatric age group. Ten patients (4.5%) were diagnosed with immotile cilia syndrome, including eight with Kartagener's syndrome. Although their complication rates were higher, the difference was not statistically significant (p = 0.091). Drain removal times and hospital stays were comparable to those without the syndrome.

Considering the changes in postoperative patient symptoms; 74.5% of patients became asymptomatic, and 21.4% had partial symptom improvement. However, recurrence occurred in nine patients, seven of whom underwent completion surgical procedures (pneumonectomy or lobectomy).

Factors affecting postoperative complications were examined. The independent variables: based on a multiple logistic regression analysis, where independent variables were gender, age, FEV1, VATS, pneumonectomy, frequent knowledge of the etiology, hemoptysis attacks, productive cough and abundant purulent sputum, the odds of postoperative complications were 82.5% lower in those who underwent VATS than in those who did not (R = 0.192, p = 0.005, nagelkerke R = 0.281). The patients who had frequent infections were 4.3 times more likely to have postoperative complications with those who did not (R = 0.192, p = 0.021, Nagelkerke R = 0.281).

Discussion

Bronchiectasis is a disease that occurs as a result of the effects of infectious, congenital, acquired, autoimmune or environmental causes, often as an irreversible result of histopathological changes [5]. This disease, which significantly reduces a person's quality of life, is an important public health problem in developing countries, including Turkey [1]. As reported in our cohort, two-thirds of patients presented with chronic cough and sputum, while nearly one-third required surgery for hemoptysis, mirroring previous series [6].

The main goals in the treatment of non-cystic fibrosis bronchiectasis; involves identifying acute exacerbations, using antibiotics to suppress microbial load, treating underlying disorders, reducing excessive inflammatory response, maintaining bronchial hygiene, controlling hemoptysis, and surgical removal of segments that may be a focus of infection or bleeding [7]. In our clinic, surgical treatment decisions were made in a joint council with chest diseases in patients who could not respond to medical treatment in line with these goals. In our multidisciplinary council, surgery was reserved for patients experiencing ≥3 pneumonia episodes per year, recurrent hospitalizations, hemoptysis, or persistent symptoms despite optimal medical therapy.

As it is known, bronchiectasis is one of the most common causes of life-threatening hemoptysis. In recent years, the primary treatment is bronchial artery embolization. Success rates reaching 99% in the acute period have been reported in the literature [8]. In our clinic, the first option after medical treatment is embolization therapy in patients who apply for massive hemoptysis due to bronchiectasis. The operations were performed under elective conditions, since acute massive hemorrhage could be relieved in most of our patients after embolization. In our series, there is only one patient who underwent emergency thoracotomy due to massive hemoptysis.

In this study an important difference in the preoperative preparation period is that sputum cultures, which were previously taken only in symptomatic patients, are

now also taken in asymptomatic patients as much as possible, and antibiotherapy is applied to these patients in the preoperative period at the treatment dose specific to the isolated pathogen. The purpose here is to ensure a 'dry period' before surgery for optimal surgical success. Therefore, surgical treatment may be delayed until infection control is optimized [9]. In our study, we found that asymptomatic patients with sputum culture positivity and patients with frequent infections were positively correlated. Moreover, multiple logistic regression analysis demonstrated that a history of frequent infections independently increased the odds of postoperative complications by 4.3-fold (OR = 4.3, p = 0.021). For this reason, we think that sputum cultures should be routinely taken in patients with a history of frequent infections, even if they do not have any symptoms during the preoperative preparation period. As a matter of fact, in the study by Hiramitsu et al, it is reported that pseudomonas colonization increases the risk of surgical morbidity [10]. Also in the study by Yu-xing Jin et al, it is reported that gram-negative bacteria colonization is risk factor for successful treatment [11]. Another study emphasizing that bacterial colonizations should be clarified in the preoperative period was by Eren et al. This study states that one of the risk factors for postoperative complications is the lack of bronchoscopy in the preoperative period [12].

In our study, we observed that postoperative complication rates significantly decreased in the last decade compared to the earlier years (26.4%-17.0%, p = 0.028), along with shorter chest tube durations (5.3 ± 4.6 days-4.1 ± 2.2 days, p = 0.013). However, a direct year-by-year comparison for the entire 22-year period is limited by the lack of standardized preoperative protocols during the first decade. For example, routine sputum culture sampling in asymptomatic patients was not implemented in the early years, making direct comparisons with the later period less reliable. Since 2012, the adoption of standardized preoperative preparation - including routine sputum cultures and targeted antibiotic therapy - as well as the increased use of VATS, appears to have contributed substantially to these improved outcomes.

Surgical mortality has been reported very rarely in the literature [6, 13-16]. In our study, as in the study of Gülhan et al, no mortality was observed within the postoperative 90 days [1]. The early complications that can be seen after the surgical treatment of bronchiectasis may vary depending on whether the patient is adequately prepared for the operation in the preoperative period, comorbidities, perioperative performance and the extent of the resection performed, and the quality of the follow-up and treatment applied in the postoperative period. As in all thoracic surgical interventions, atelectasis, hemothorax, prolonged air leakage, pneumonia, wound infection, bronchopleural fistula, empyema, expansion defect, pleural effusion, chylothorax and cardiac rhythm disorders can be seen in patients after bronchiectasis surgery. Morbidity rates have been reported in the range of 0-25% in studies [17]. In our study, this rate was found to be 26.4%. The most important reason why morbidity is above the literature data is that the most common complication in our study, prolonged air leak, was not 7 days, unlike other studies; It is accepted after 5 days. However, there has been a statistically significant decrease in our complication rates in the last 10 years. Undoubtedly, increasing surgical experience has a great importance in this.

In addition, with the developments in VATS in recent years, we can say that the complication rates are gradually decreasing due to the fact that VATS is preferred more and more in major surgical procedures in our clinic. According to the literature, VATS is considered advantageous due to its low morbidity and mortality rates, rapid recovery, early relief of postoperative pain and cosmetic results [9, 16]. However, the effect of thoracotomy on postoperative morbidity was not investigated in these studies. In this respect, our study emphasizes an important point.

This study has some limitations. Although we have analyzes covering a long period of 22 years; this study was conducted retrospectively. Since detailed files could not be reached in hospital records due to its long duration, investigation of etiology and comorbidities was incomplete. In addition, since an objective scoring system cannot be used to determine the quality of life of the patients, long-term postoperative assessments are based on subjective data.

In conclusion, this study shows that; in the surgical treatment of bronchiectasis; thoracotomy is an important reason that increases the risk of complications. We think that VATS is a very safe method due to its low mortality and morbidity rates and should be preferred in every possible patient. We also recommend routinely obtaining sputum cultures from all asymptomatic patients to detect colonizations and reduce the risk of complications. This study also supports the literature; it reveals that surgical treatment is very effective for a curative outcome in bronchiectasis patients, however,

the surgery must be performed as anatomical lung resection. And, this study also highlights that clinical experience and effective preoperative patient preparation can be as effective as the minimally invasive approach at low complication rates.

Declaration of conflicting interests

The authors declared no conflicts of interest with respect to the authorship and/or publication of this article.

Funding

The authors received no financial support.

Ethics approval

The study was approved by the Ethics Committee of the Uludağ University Experimental Medicine Research Institute (2011-KAEK-26/553).

Authors' contribution

GT; Study design, data collection, statistical analysis, interpretation of data, manuscript writing, final approval of the version to be published, TES; Patient records management, ethics approval coordination, HM; Contribution to surgical cases, EY,EO; Patient follow-up, clinical data validation, NAAO; Statistical consultation, data modeling, AU; Data interpretation, literature review, CG; Operative technique design, critical revision of the manuscript, ASB; Critical revision of the manuscript, final approval of the version to be published

References

1. Gülhan SŞE, Acar LN, Güven ES, Bıçakçıoğlu P, Aydın E, Karasu S et al. Surgical treatment of bronchiectasis: Our 23 years of experience. Turk Gogus Kalp Damar Cerrahisi Derg 2020; 28: 629-37.
2. Polverino E, Goeminne PC, McDonnell MJ, Aliberti S, Marshall SE, Loebinger MR et al. European Respiratory Society guidelines for the management of adult bronchiectasis. Eur Respir J 2017 9; 50: 1700629.
3. Fan LC, Liang S, Lu HW, Fei K, Xu JF. Efficiency and safety of surgical intervention to patients with non-cystic fibrosis bronchiectasis: a meta-analysis. Sci Rep 2015; 5: 17382.
4. Hao X, Dazhong L, Lei Y, Jiaying Z, Linyou Z. SurAgical treatment of bronchiectasis: 5 years of experience at a single institution. J Laparoendosc Adv Surg Tech A 2019; 29: 826-30.
5. Chalmers JD, Goeminne P, Aliberti S, McDonnell MJ, Lonni S, Davidson J et al. The bronchiectasis severity index. An international derivation and validation study. Am J Respir Crit Care Med 2014; 189: 576-585.
6. Caylak H, Genc O, Kavakli K, Gurkok S, Gozubuyuk A, Yucel O et al. Surgical management of bronchiectasis: a collective review of 339 patients with long-term follow-up. Thorac Cardiovasc Surg 2011; 59: 479-83.
7. Pasteur MC, D. Bilton D, Hill AT. British Thoracic Society guideline for non-CF bronchiectasis. Thorax 2010; 65: i1-i58.
8. Prey B, Francis A, Williams J, Krishnadasan B. Evaluation and Treatment of Massive Hemoptysis. Surg Clin 2022; 102: 465-81.
9. Ocakcioglu I. Uniportal thoracoscopic treatment in bronchiectasis patients: preliminary experience. Wideochir Inne Tech Maloinwazyjne 2019; 14: 304-310.
10. Hiramatsu M, Shiraishi Y, Nakajima Y, Miyaoka E, Katsuragi N, Kita H et al. Risk factors that affect the surgical outcome in the management of focal bronchiectasis in a developed country. Ann Thorac Surg 2012; 93: 245-50.
11. Jin YX, Zhang Y, Duan L, Yang Y, Jiang GN, Ding JA. Surgical treatment of bronchiectasis: a retrospective observational study of 260 patients. Int J Surg 2014; 12: 1050-4.
12. Eren S, Esme H, Avci A. Risk factors affecting outcome and morbidity in the surgical management of bronchiectasis. J Thorac Cardiovasc Surg 2007; 134: 392-8.
13. Zhang P, Jiang G, Ding J, Zhou X, Gao W. Surgical treatment of bronchiectasis: a retrospective analysis of 790 patients. Ann Thorac Surg 2010; 90: 246-50.
14. Özkan M., Sakallı MA, Yenigün BM, Kocaman G, Yüksel C, Enön S. Surgical Treatment in Bronchiectasis: Results of 191 Patients. Journal of Ankara University Faculty of Medicine 2019; 72: 241-6.
15. Balci AE, Balci TA, Özyurtkan, MO. Current surgical therapy for bronchiectasis: surgical results and predictive factors in 86 patients. Ann Thorac Surg 2014; 97; 211-7.
16. Baysungur V, Dogruyol T, Ocakcioglu I, Misirlioglu A, Evman S, Kanbur S et al. The feasibility of thoracoscopic resection in bronchiectasis. urg Laparosc Endosc Percutan Tech 2017; 27: 194-6.
17. Hiramatsu M and Shiraishi Y. Surgical management of non-cystic fibrosis bronchiectasis. J Thorac Dis 2018; 10: 3436-45.

This article is an open access article distributed under the terms and conditions of the Creative Commons Attribution (CC BY) license (http://creativecommons.org/licenses/by/4.0/).

To cite this article: Ulas AB, Aydin Y, Eroglu A. Pulmonary metastasectomy: indications, surgical principles, prognosis and outcomes. Curr Thorac Surg 2025;10(2):64-80.

Review Article

Pulmonary metastasectomy: indications, surgical principles, prognosis and outcomes

Ali Bilal Ulas*, Yener Aydin, Atilla Eroglu

Department of Thoracic Surgery, Ataturk University, Medical Faculty, Erzurum, Turkey

ABSTRACT

Surgical resection of pulmonary metastases is now widely considered for patients who meet the following criteria: controlled primary disease, absence of extensive extrapulmonary disease, fully resectable lung metastases, sufficient cardiopulmonary reserves, and lack of superior systemic treatment alternatives. Since the development of these selection criteria, additional prognostic factors have been proposed to better predict survival and optimize the selection of surgical candidates. Factors such as the disease-free interval (DFI), completeness of resection, surgical approach, number and laterality of lung metastases, and lymph node involvement play a dynamic role in determining patient outcomes.

Pulmonary metastasectomy is a common practice among thoracic surgeons, accounting for approximately 15% of all lung resections. While it is widely believed that pulmonary metastasectomy from a primary tumor elsewhere improves survival in selected patients, evidence for the additional benefit provided by surgery remains weak.

For patients with untreated metastatic disease, the five-year survival rate is less than 5–10%. Pulmonary metastasectomy often represents the best hope for treatment in cases of isolated metastatic disease to the lungs. It is a safe and effective treatment that offers potential recovery for selected patients. Regardless of the primary tumor, achieving complete resection is the key to improving survival. Low morbidity and mortality rates justify the aggressive surgical approach in the absence of effective systemic oncologic treatments. Thoracoscopic resection is a valid option for selected patients with a small number of peripherally located metastases. In cases of recurrent pulmonary disease, surgery should be repeated if the patient continues to meet the initial criteria for pulmonary metastasectomy. Postoperative aggressive follow-up is mandatory. Patients should be treated in close collaboration between medical oncologists, diagnostic radiologists, and thoracic surgeons.

Keywords: pulmonary metastasectomy, surgical resection, disease-free interval, thoracoscopic surgery, survival outcomes, thoracic oncology

Corresponding Author: Ali Bilal Ulas, MD. Department of Thoracic Surgery, Faculty of Medicine, Ataturk University, 25240 Erzurum, Turkey.
Email: dralibilalulas@gmail.com Phone: +90 442 3448440
Doi: 10.26663/cts.2025.018
Received 31.01.2025 accepted 29.04.2025

Introduction

This review examines the evaluation of pulmonary metastases, criteria for suitability for resection, outcomes for different tumor histologies, the feasibility of surgical resection, alternative approaches, and prognostic factors.

Approximately one-third of patients with malignant diseases develop pulmonary metastases [1-4]. Pulmonary metastasectomy (PM) is an established treatment that can improve long-term survival in patients with metastatic lung cancer originating from various primary solid tumors. Surgery is generally recommended for cases in the oligometastatic stage and for all patients who can tolerate the procedure.

The most common primary solid tumors causing pulmonary metastases include colorectal, renal, breast, prostate, and oropharyngeal carcinomas. Other tumors that primarily metastasize to the lungs include choriocarcinoma, osteosarcoma, soft tissue sarcomas, testicular tumors, Ewing sarcoma, and thyroid carcinoma [4].

Historically, systemic therapy has been considered the standard of care for stage IV cancer due to the systemic nature of the disease. However, local treatment options for metastatic pulmonary nodules are expanding, providing significant evidence for optimal local control to prolong life, delay recurrence, and relieve patients from ongoing chemotherapy [5].

While there is no absolute upper limit to the number of resectable nodules, having more than three during the first metastasectomy increases recurrence risk (especially in CRC). Nevertheless, larger numbers of lesions have been resected safely with good outcomes. The total number of metastases is less significant than the ability to achieve an R0 resection with a lung volume that the individual patient can tolerate [5].

The patient's comorbidities are particularly important in determining the recommended form of local treatment for pulmonary metastases. In some cases, systemic therapy before surgery can reduce tumor volume, increase the effectiveness of subsequent radiation or ablative treatments, and decrease the amount of parenchyma required for resection [5].

The role of pulmonary metastasectomy has been extensively studied since the 1970s and was highlighted in a landmark publication in 1997 reporting the results of the International Registry of Lung Metastases. This study provided critical data supporting the role of surgery in selected patients and identified key prognostic factors influencing survival [6].

The lungs are the most common site for metastatic malignancies [7]. Once primary tumors metastasize, treatment becomes more challenging, leading to significantly higher morbidity and mortality. However, pulmonary metastasectomy can be performed with curative intent in selected patients. Complete surgical excision is technically feasible, usually with low perioperative morbidity and mortality. Pulmonary resection is only suitable for patients whose primary disease is controlled, who have no widespread or uncontrolled extrapulmonary metastases, whose lung metastases can be fully resected, and who have adequate cardiopulmonary reserves to tolerate surgery [7].

The first pulmonary metastasectomy was reported in 1882. As chest imaging became available, planned resections of lung metastases were introduced. Criteria for pulmonary metastasectomy have since been defined and updated. These include control or apparent controllability of the primary disease, feasibility of complete resection of metastatic lung disease, patient tolerance for planned procedures, and the absence of better alternative treatments [8].

The Expert Consensus Document on Pulmonary Metastasectomy emphasizes the importance of multidisciplinary approaches and standardized criteria for optimizing surgical outcomes [9]. Minimally invasive techniques, such as VATS, have increasingly demonstrated improved perioperative outcomes in selected patient populations [10,11].

For patients with untreated metastatic disease, the five-year survival rate is less than 5-10%. In cases of isolated metastatic disease to the lungs, pulmonary metastasectomy often represents the best hope for treatment [12,13].

Preoperative evaluation

Preoperative evaluation consists of obtaining a detailed history, performing a physical examination, conducting physiological tests, and utilizing radiological imaging. Radiological investigations are essential for determining the differential diagnosis of pulmonary nodules, assessing the exact number, location, and characteristics of the nodules, and identifying any extrathoracic metastases. Advanced techniques like PET-CT have been

instrumental in enhancing the detection and staging of metastatic disease, aiding in precise treatment planning [14,15]. Mediastinal lymph node evaluation through systematic dissection or sampling remains critical for prognostic and diagnostic accuracy [16,17]. Indications for pulmonary metastasectomy should be evaluated from both physiological and oncological perspectives [2,13]. Nichols et al highlighted the critical role of imaging in determining surgical candidacy for pulmonary metastasectomy, ensuring all nodules are resectable and systemic disease is controlled [18].

Patient selection

When pulmonary metastatic disease is encountered, and surgical options are being considered, several key criteria must be evaluated to determine the most appropriate treatment plan for the patient. First, all pulmonary nodules should be resectable, or if not, they should be amenable to management using a hybrid approach that includes additional local therapies. Second, the primary tumor must either be fully controlled or controllable with appropriate treatment. Third, any extrathoracic disease present must also be under control or manageable to ensure that surgery can provide meaningful benefits. Fourth, it is essential that complete resection (R0) is feasible, as achieving clear surgical margins is critical for improving survival outcomes. Finally, the patient must have an acceptable preoperative risk profile, ensuring that they can safely tolerate the procedure and its associated recovery process. These considerations are vital for optimizing surgical outcomes and ensuring that the benefits of the procedure outweigh the risks for each individual case.

Studies have documented that surgical resection provides significant survival benefits in properly selected patients, particularly when criteria for complete resection are met [19]. Furthermore, redo metastasectomy has shown comparable outcomes to initial surgeries, particularly in sarcoma patients [20,21]. Laser-assisted surgical techniques have also been highlighted as promising approaches for achieving precise resections while preserving lung parenchyma [22,23]. If these criteria are met, the decision regarding surgery should then consider whether the patient has an acceptable operative risk. For patients with prohibitive surgical risks, nonoperative techniques such as radiofrequency ablation or stereotactic body radiation therapy may be considered. If the outlined criteria cannot be achieved, a nonoperative or hybrid approach may still be considered if the patient's condition allows [5,6].

Guidelines for patient selection for pulmonary metastasectomy were established after the publication of a landmark retrospective study in 1997, which analyzed data from 5,206 cases in the International Registry of Lung Metastases. This study identified four key prognostic factors that significantly influence survival outcomes. These factors include the number of metastases present in the lungs, the disease-free interval between the treatment of the primary tumor and the emergence of pulmonary metastases, the feasibility of completely resecting all visible lesions, and the histology of the primary tumor [24]. Pulmonary metastases are generally asymptomatic, and specific symptoms may indicate advanced disease. However, 15-20% of patients may present with symptoms such as cough, hemoptysis, chest pain, or post-obstructive pneumonia [1].

Detailed information on the treatment history of the primary tumor, including tumor stage, histological type, the interval between treatment of the primary tumor and detection of pulmonary metastases, presence of other metastatic sites, and chemotherapy regimen, is required. These factors serve as significant prognostic indicators [2].

For patients undergoing cytotoxic chemotherapy, pulmonary resection should be scheduled after the white blood cell count normalizes (typically around four weeks). In cases treated with bevacizumab, pulmonary resection should be delayed until at least six weeks after the last dose to minimize the risk of postoperative pulmonary fistulas. While most candidates for pulmonary metastasectomy are asymptomatic, it is essential to investigate respiratory symptoms that may indicate endobronchial involvement or centrally located bulky lesions [2].

When pulmonary nodules are detected in patients with a history of malignancy, a differential diagnosis is crucial. Multiple nodules are likely to be metastatic disease from the primary tumor, but distinguishing pulmonary metastases from primary lung cancer can be challenging when there is only a single nodule. For solitary pulmonary nodules (SPN), the decision on whether to proceed with an invasive diagnostic procedure depends on the treatment strategy for the SPN, which should consider factors such as the type of primary tumor, the type of resection performed (if applicable), and the patient's overall condition [2].

When preoperative imaging reveals mediastinal and hilar lymph nodes, their assessment is critical. Lymph node involvement, regardless of histology, is a significant negative prognostic factor for patients undergoing

pulmonary metastasectomy. Therefore, patients with mediastinal adenopathy should undergo invasive mediastinal staging (e.g., mediastinoscopy or endobronchial ultrasound-guided fine-needle aspiration) before undergoing pulmonary metastasectomy. Although the presence of hilar or mediastinal lymph node involvement correlates with poorer survival compared to patients without nodal involvement, documented nodal metastases are not an absolute contraindication for metastasectomy, as some patients with lymph node involvement have achieved long-term survival following surgery [8].

Radiologic studies

Radiologic evaluation is a critical component of the preoperative assessment for pulmonary metastasectomy, serving several essential purposes. It helps differentiate pulmonary nodules, assesses their number, location, and characteristics, and identifies the presence of extrathoracic metastases [2]. High-resolution computed tomography (CT) scans with 1-2 mm slices are considered the gold standard for evaluating pulmonary nodules. In addition, positron emission tomography (PET) scans complement CT by staging metastatic disease and ruling out distant metastases, with the sensitivity of PET varying based on the histology of the metastases [1].

Additional imaging modalities may also be utilized in specific scenarios. Bone scans are often used to detect osseous metastases, particularly in patients with sarcomas. Brain imaging, such as magnetic resonance imaging (MRI) or CT, is employed to exclude central nervous system involvement in symptomatic patients or those with high-risk tumor histologies [25]. These imaging techniques collectively provide a comprehensive evaluation, enabling effective surgical planning and optimized patient outcomes.

Mediastinal and hilar lymph node evaluation

Mediastinal and hilar lymph node metastases are associated with worse prognosis. Enlarged or hypermetabolic nodes identified on imaging warrant invasive staging through mediastinoscopy or endobronchial ultrasound (EBUS)-guided fine-needle aspiration [1,25].

While CT scans detect more nodules than chest radiographs, they may still underestimate the total number of metastatic lesions compared to manual palpation during surgery. Studies suggest that up to 20-25% of nodules remain undetected by imaging but can be found intraoperatively [25]. Advances in CT technology, including the ability to detect nodules as small as 1 mm, have reduced this discrepancy, although manual palpation remains valuable for certain histologies like osteosarcoma [25].

Indications and contraindications for pulmonary metastasectomy

Pulmonary metastasectomy is a well-established treatment option for patients with metastatic lung disease, provided that certain conditions are met. Patients considered for surgery must be in good overall health and have no significant operative risks. Most importantly, the primary tumor should either be controlled or manageable through additional treatment. While the absence of extrathoracic disease is ideal, metastases in other organs may still allow for surgery if they are resectable or have already been effectively treated [1,6].

Complete surgical resection (R0 resection) is critical for improving survival outcomes. Incomplete resections (R1 or R2) are strongly associated with poor prognosis, making the ability to fully remove all visible metastases a key criterion. Furthermore, the decision to perform metastasectomy must consider the availability of systemic or alternative therapies. Recent advancements in targeted treatments and immunotherapy have introduced new options that must be weighed against surgical intervention [1,26].

Despite these criteria, not all patients are suitable candidates for metastasectomy. Uncontrolled primary tumors, unresectable pulmonary disease, or severe comorbidities often disqualify patients. Mediastinal lymph node involvement (N2 disease) and widespread extrathoracic metastases, although not absolute contraindications, require careful evaluation. Multidisciplinary discussions are essential to determine whether surgery is the best option in these complex cases [19,26].

Pulmonary metastasectomy principles

Pulmonary metastasectomy is primarily performed with curative intent, aiming to improve survival in carefully selected patients. The key objective of the procedure is to completely resect all visible metastases while preserving as much pulmonary parenchyma as possible. Achieving this balance requires tailoring the surgical approach to the location and characteristics of the metastases [1,3,4]. Hornbech et al discussed the evolving practices in metastasectomy, with a focus on achieving complete resection while minimizing morbidity [12].

For peripheral lesions, wedge resections are commonly used, often with the aid of surgical tools such as staplers or laser devices. These techniques ensure minimal tissue loss while achieving clear surgical margins. For central or larger lesions, more extensive procedures such as segmentectomy, lobectomy, or even pneumonectomy may be necessary to achieve complete resection [1,4].

The International Registry of Lung Metastases, which analyzed over 5,000 cases, reported that wedge resection was the most frequently performed procedure, accounting for 67% of cases. Lobectomy, segmentectomy, and pneumonectomy followed at 21%, 9%, and 3%, respectively. These findings underscore the importance of individualized surgical planning based on the size, location, and number of metastases [3,4].

Minimally invasive techniques, such as video-assisted thoracoscopic surgery (VATS), are increasingly used for patients with small, peripherally located nodules. These approaches offer advantages such as reduced pain, shorter hospital stays, and quicker recovery. However, VATS may not always allow complete assessment of the lung, and manual palpation through open thoracotomy remains the gold standard for detecting smaller or occult nodules [4,13].

In cases of recurrent pulmonary disease, repeat metastasectomy can be performed if the patient continues to meet the criteria for surgery. Repeat procedures have been shown to provide survival benefits comparable to initial resections, particularly when complete resection is achievable [12,13].

Thoracotomy or a minimally invasive approach?

Open thoracotomy has historically been the standard surgical approach for pulmonary metastasectomy due to its ability to allow thorough manual palpation of the lung parenchyma. This method is particularly valuable for detecting nodules that are not visible on imaging. Even with advances in high-resolution computed tomography (CT), 20-25% of nodules may remain undetected preoperatively but can be identified through manual palpation during surgery [11,27]. This is especially critical in cases involving tumors like osteosarcoma, where small, occult metastases are more common [26].

However, video-assisted thoracoscopic surgery (VATS) has emerged as a minimally invasive alternative, offering significant advantages in perioperative outcomes. VATS is associated with reduced pain, shorter hospital stays, quicker recovery, and better tolerance for adjuvant therapies. Retrospective studies comparing VATS and thoracotomy have shown comparable overall survival rates, particularly in patients with small, peripherally located metastases [10,11,27]. Despite these benefits, VATS is not without limitations, particularly its inability to allow comprehensive manual palpation. This limitation can lead to undetected metastases and potentially compromise surgical outcomes in certain patients [22,28].

Recent studies and meta-analyses have examined the long-term outcomes of VATS versus thoracotomy. One meta-analysis found that VATS is associated with superior overall survival (OS) compared to thoracotomy, while recurrence-free survival (RFS) rates were similar between the two groups. Additionally, VATS has been shown to provide equivalent outcomes for patients with colorectal cancer metastases [10,22]. The advantages of VATS, such as improved postoperative mobility and reduced morbidity, make it an attractive option for selected patients [11,23]. Nichols highlighted the trade-offs between open thoracotomy and VATS, particularly in terms of manual palpation and patient recovery [13].

For patients with centrally located lesions, multiple metastases, or histologically aggressive tumors, open thoracotomy remains the preferred approach. It ensures complete exploration and resection of all lesions, thereby maximizing the likelihood of achieving R0 resection [22,26]. In practice, the choice between VATS and thoracotomy should be individualized, taking into account the patient's clinical condition, the characteristics of the metastases, and the surgeon's expertise [27,28].

Complete vs incomplete resection

Achieving a complete resection (R0) is critical for improving survival in patients undergoing pulmonary metastasectomy. Studies have consistently shown that patients who undergo incomplete resections (R1 or R2) have significantly worse survival outcomes compared to those with R0 resections [19,12]. The importance of complete resection is underscored by data from the International Registry of Lung Metastases, which demonstrated that survival rates are substantially higher in patients with R0 resection, regardless of tumor histology [27].

In cases where complete resection is not feasible due to the extent of disease or the location of metastases, surgical intervention should be avoided. Incomplete resections

not only fail to improve survival but also expose patients to unnecessary surgical risks [19,26]. The only exception may involve specific palliative scenarios, such as controlling life-threatening complications like hemoptysis or pneumothorax caused by metastatic lesions [12,26].

Timing of pulmonary metastasectomy

The timing of pulmonary metastasectomy is a critical consideration in treatment planning and is influenced by the status of the primary tumor, the presence of extrathoracic disease, and the overall clinical context. Surgery is generally performed after the primary tumor has been controlled and any extrathoracic metastases have been adequately treated or stabilized. However, certain clinical circumstances may warrant deviations from this sequence [5].

In cases where patients present with synchronous metastases or a short disease-free interval (DFI), it may be prudent to delay surgery and monitor disease progression with serial imaging, such as CT scans performed every 6-8 weeks. This approach can help identify patients with rapid extrathoracic disease progression, sparing them from unnecessary surgical interventions. Conversely, patients with isolated pulmonary lesions and no active extrathoracic disease may benefit from earlier resection, particularly when systemic therapy options are limited [19,12,26].

The surgical approach can also influence timing decisions. For instance, minimally invasive techniques like VATS may allow for earlier interventions due to shorter recovery times, while patients requiring open thoracotomy for more complex resections might benefit from a longer observation period to fully assess disease progression [19,29].

Ultimately, the timing of metastasectomy should be determined through a multidisciplinary approach that considers the patient's overall condition, tumor biology, and the available systemic therapy options. Tailoring the timing to the individual clinical scenario ensures that patients derive the maximum benefit from surgery [29].

Margins

The surgical margin plays a crucial role in determining the success of pulmonary metastasectomy. Achieving tumor-free margins (R0 resection) significantly reduces the risk of local recurrence and is strongly associated with improved survival outcomes. While there is no universal agreement on the ideal margin size, most studies recommend a margin of at least 10 mm for wedge resections to minimize the risk of recurrence. However, for larger tumors, wider margins may be necessary [3,19].

Recent studies have emphasized the importance of the tumor-to-margin ratio. A ratio greater than 1.7 has been linked to better outcomes, as it reflects sufficient clearance of the tumor from surrounding healthy tissue. This finding is particularly relevant for patients with small peripheral nodules undergoing wedge resection [3,26].

Advances in surgical techniques have introduced tools such as curved staplers, which facilitate achieving uniform and adequate margins while preserving lung parenchyma. These devices are especially useful in cases involving deep or central lesions where maintaining consistent margins can be technically challenging [22,26].

Failure to achieve adequate surgical margins is associated with a higher risk of local recurrence and poorer survival. This is particularly evident in aggressive histologies, such as sarcomas and colorectal cancer metastases, where even small residual disease can significantly impact outcomes [19,23]. Therefore, ensuring appropriate margins is a critical aspect of surgical planning and execution.

Number of lung metastases

The number of pulmonary metastases is a well-established prognostic factor in patients undergoing metastasectomy. Although patients with fewer metastases generally exhibit better survival outcomes, the absolute number of nodules is not necessarily a strict determinant for surgery. The feasibility of achieving a complete resection (R0) is a more critical consideration [3,26].

Studies have consistently shown that patients with solitary metastases achieve the best survival outcomes, reflecting limited disease burden. However, patients with multiple metastases can still benefit from surgery, provided that all visible lesions can be completely resected. For instance, data from the International Registry of Lung Metastases suggest that even patients with three or more nodules can achieve long-term survival if R0 resection is feasible [26,27].

It is essential to emphasize that the ability to resect all visible disease outweighs the absolute number of nodules. For patients with extensive metastatic disease, modern imaging techniques, such as high-resolution CT and PET scans, are crucial for preoperative planning. Additionally, intraoperative palpation can help identify smaller nodules that might be missed during imaging, particularly in cases involving histologies like osteosarcoma or soft tissue sarcomas [19,22].

Ultimately, surgical decision-making should be individualized, taking into account not only the number of metastases but also the patient's overall health, tumor biology, and the likelihood of achieving a complete resection. When these factors align, even patients with multiple metastases can derive significant survival benefits from metastasectomy [3,26].

Pulmonary metastasectomy for specific histologies

Each histological type behaves differently, making it logical to assume that the effectiveness and role of surgery depend on the primary tumor's histology. Independent of histology, factors such as incomplete resection, the number and size of resected tumors, lymph node (LN) metastases, and short disease-free intervals (DFI) are recognized as predictors of poor prognosis. In contrast, certain prognostic indicators are specific to individual histological types [3].

Colorectal cancer (CRC)

Colorectal cancer is the most frequent primary malignancy among patients undergoing pulmonary metastasectomy (PM). Key prognostic factors include the number of pulmonary metastases, carcinoembryonic antigen (CEA) levels, and the disease-free interval (DFI). Patients with a longer DFI, fewer nodules, and normal preoperative CEA levels exhibit significantly better survival outcomes [2,3,12].

Additionally, the location and timing of metastases play a crucial role. Synchronous liver and lung metastases are not a contraindication for surgery if both sites are resectable. Data indicate that combined hepatic and pulmonary metastasectomy can yield five-year survival rates of approximately 30% in carefully selected cases. However, the presence of mediastinal lymph node involvement or elevated preoperative CEA levels are associated with worse outcomes [26,30].

Renal cell carcinoma

Renal cell carcinoma (RCC) is the second most common primary tumor in patients undergoing PM. Achieving R0 resection is vital, as incomplete resections (R1 or R2) do not provide survival benefits. Prognostic factors include tumor burden, lymph node involvement, and the disease-free interval. Shorter DFIs and nodal metastases are associated with poorer outcomes, while patients with solitary nodules and long DFIs fare better. Five-year survival rates for RCC patients after PM range from 20% to 74%, depending on these variables [2,12,26].

Osteosarcoma

Osteosarcoma frequently metastasizes to the lungs, with up to 30–40% of patients developing pulmonary nodules during the course of their disease. Pulmonary metastasectomy offers significant survival benefits, particularly in young patients with solitary or limited nodules and longer DFIs. Achieving complete resection is critical, as residual disease negatively impacts survival. Studies report five-year survival rates ranging from 20% to 40% for osteosarcoma patients undergoing PM [6,26].

Histological factors also influence outcomes. Subtypes like chondroblastic osteosarcoma tend to exhibit worse prognoses. Moreover, patients who develop metastases during chemotherapy generally experience poorer survival compared to those whose metastases develop after completing treatment [6,31].

Soft tissue sarcoma

Soft tissue sarcomas predominantly metastasize to the lungs, making PM the primary curative option for many patients. Prognostic factors include tumor grade, disease-free interval, and the number of pulmonary nodules. Lower-grade tumors, longer DFIs, and fewer metastases are associated with improved survival. Studies suggest that achieving R0 resection is crucial, as incomplete resections fail to provide survival benefits [6,26,31].

For patients with multiple metastases or recurrent disease, repeat metastasectomy has shown to improve survival, highlighting the importance of tailored surgical strategies [26].

Germ cell cumors

Nonseminomatous germ cell tumors (NSGCTs) are highly responsive to chemotherapy. However, for patients with residual or recurrent disease after systemic treatment, pulmonary metastasectomy can significantly enhance survival. Five-year survival rates after R0 resection range from 73% to 94%, depending on the extent of disease and the success of systemic therapy [6,32].

In cases where nodal or extrathoracic disease is present, careful patient selection is necessary. Achieving complete resection remains the most important factor influencing survival. Patients with incomplete resection or unresectable disease have significantly worse outcomes compared to those who undergo R0 resection [6,33].

Head and neck cancers

Pulmonary metastases are a common occurrence in pa-

tients with head and neck cancers, as the lungs are the most frequent site of distant metastases for these malignancies. Despite the poor prognosis associated with metastatic head and neck cancers, pulmonary metastasectomy (PM) has been shown to improve survival in selected patients [6]. Evidence also supports the role of pulmonary metastasectomy in improving outcomes for head and neck cancers, as shown in systematic analyses [34,35].

Several factors influence the outcomes of PM in head and neck cancers. A disease-free interval (DFI) longer than 12 months is associated with significantly better survival rates. Similarly, patients with a limited number of metastases and no evidence of mediastinal lymph node involvement fare better. In contrast, patients with squamous cell carcinoma histology, shorter DFIs, and metastases originating from oral cavity cancers often have worse prognoses [2,3,6].

Five-year survival rates following PM for head and neck cancers vary widely, ranging from 20% to 60% depending on the tumor's histology, the extent of metastases, and the completeness of resection. Patients with adenoid cystic carcinoma, for example, tend to have much better survival outcomes compared to those with squamous cell carcinoma. Documented mediastinal lymph node involvement and plevral infiltration are associated with worse outcomes [6,31].

Complete resection (R0) remains the most critical determinant of improved survival. For patients presenting with a higher metastatic burden or additional risk factors, multidisciplinary discussions are essential to evaluate the potential benefits of surgery. While PM is often recommended for isolated metastases, patients with extensive disease may benefit more from systemic therapies [6].

Gynecologic cancers

Pulmonary metastases from gynecologic cancers, though less common, present unique challenges in patient management. The lungs are the most frequent site of distant metastases for cervical, endometrial, and ovarian carcinomas, as well as choriocarcinoma and uterine sarcomas. While systemic therapies are often the first line of treatment, pulmonary metastasectomy (PM) can provide survival benefits in selected cases [6,26].

The prognosis of patients undergoing PM for gynecologic cancers depends on several factors, including the histology of the primary tumor, disease-free interval (DFI), and the number of metastases. Patients with squamous cell carcinoma of the cervix generally exhibit poorer outcomes compared to those with endometrial carcinoma. A longer DFI, limited number of pulmonary nodules, and absence of mediastinal lymph node involvement are associated with improved survival [6,31].

Encouraging results have been reported for patients undergoing PM for gynecologic cancers. Five-year survival rates vary significantly by histology, ranging from 40% for cervical carcinoma to 76% for endometrial carcinoma. In one study involving patients with uterine malignancies, a five-year survival rate of 69% was reported for those with isolated pulmonary metastases who underwent complete resection [12].

For patients with choriocarcinoma, systemic chemotherapy is often curative [31], but PM may be considered for those with persistent pulmonary nodules after treatment. Similarly, for patients with uterine sarcomas, PM is reserved for isolated metastases and cases where systemic options have been exhausted.

Complete resection remains the cornerstone of successful surgical outcomes. Patients with incomplete resections or widespread disease have significantly worse survival rates. Therefore, patient selection and multidisciplinary decision-making are critical when considering PM for gynecologic cancers [6,31,36].

Breast cancers

Pulmonary metastases are a frequent manifestation in advanced or recurrent breast cancer, with an estimated incidence of 7–24%. Although systemic therapies, including chemotherapy, hormonal treatment, and targeted therapies such as trastuzumab for HER2-positive tumors, are the cornerstone of management, pulmonary metastasectomy (PM) has demonstrated potential survival benefits in appropriately selected patients [1,3].

The prognosis of breast cancer patients undergoing PM is influenced by several factors. A longer disease-free interval (DFI), particularly exceeding three years, has consistently been associated with improved survival outcomes. Hormone receptor status also plays a critical role, with hormone receptor-positive tumors responding better to therapy and correlating with a more favorable prognosis. Additionally, patients with a limited number of pulmonary metastases tend to achieve better long-term outcomes compared to those with extensive disease [1,3,31].

Meta-analyses indicate that the five-year survival rate for breast cancer patients undergoing PM is approximately

45–46%. However, factors such as incomplete resection (R1 or R2), short DFI, and negative hormone receptor status significantly worsen survival. Achieving complete resection (R0) remains paramount to improving outcomes, particularly in cases of oligometastatic disease [12,26].

One of the challenges in managing pulmonary metastases in breast cancer lies in the difficulty of distinguishing metastatic lesions from primary lung cancers based on imaging alone. Solitary pulmonary nodules, in particular, require pathological confirmation to differentiate between metastatic breast cancer and primary lung malignancies. Accurate diagnosis is essential for guiding treatment strategies and ensuring optimal outcomes [31,37].

Patients with HER2-positive breast cancer or those who respond well to systemic therapy may benefit from a combined approach integrating surgery with ongoing systemic treatments. Multidisciplinary evaluation is crucial in determining the timing and appropriateness of PM, especially in patients with isolated metastases and stable systemic disease. In such cases, PM can offer meaningful survival benefits, highlighting its role as a vital component of the treatment plan for selected breast cancer patients [31].

Hepatocellular cancer

Pulmonary metastases are the most common form of extrahepatic recurrence in hepatocellular carcinoma (HCC), with an incidence ranging from 6% to 56%. Despite advances in systemic therapies, effective treatment options for metastatic HCC remain limited, making pulmonary metastasectomy (PM) a valuable intervention for selected patients [31,38].

The prognosis of patients undergoing PM for HCC is influenced by several factors. A longer disease-free interval (DFI), typically exceeding 12 months, is associated with significantly improved survival outcomes. Additionally, patients with fewer and smaller metastases, normal preoperative alpha-fetoprotein (AFP) levels, and no evidence of uncontrolled intrahepatic disease tend to achieve better long-term survival. By contrast, patients with extensive pulmonary disease, higher AFP levels, or concurrent active liver disease often experience worse outcomes [31,48].

Reported five-year survival rates for patients undergoing PM for HCC vary widely, ranging from 12% to 67%, depending on the extent of disease and the completeness of resection. Complete resection (R0) is critical, as incomplete resections do not provide survival benefits. For patients with extensive disease, surgery is typically contraindicated unless performed with palliative intent to address complications like hemoptysis or airway obstruction [48].

Careful patient selection is essential when considering PM for HCC. Multidisciplinary evaluation involving hepatologists, oncologists, and thoracic surgeons ensures that patients most likely to benefit from surgery are identified. While PM may not be suitable for all HCC patients with pulmonary metastases, it remains a valuable tool in the management of select cases where systemic therapies alone are insufficient [31,48].

Gastric cancers

Pulmonary metastases from gastric cancer are relatively rare, with an incidence of 0.3% to 6%. Most cases involve lymphangitic spread or pleural dissemination, while isolated nodular metastases to the lungs are uncommon. For selected patients with limited metastatic disease, pulmonary metastasectomy (PM) can provide survival benefits, but the role of surgery remains controversial [6,39].

The prognosis of patients with pulmonary metastases from gastric cancer is generally poor. However, certain factors are associated with better outcomes. Patients with longer disease-free intervals (DFI), smaller and fewer pulmonary nodules, and no evidence of systemic progression tend to achieve better survival rates. Studies have reported five-year survival rates ranging from 9% to 45% for patients undergoing PM, with the best outcomes observed in those who achieve complete resection (R0) [31,39].

Despite these findings, systemic chemotherapy remains the mainstay of treatment for metastatic gastric cancer, and surgery is rarely performed. PM is typically reserved for highly selected cases, such as patients with long DFIs, isolated pulmonary nodules, and no active extrathoracic disease. In such cases, the potential for prolonged survival justifies the risks associated with surgery [31,39].

Given the aggressive nature of gastric cancer and its propensity for widespread dissemination, careful patient selection is critical. Multidisciplinary discussions involving oncologists, thoracic surgeons, and gastroenterologists are essential to determine the feasibility and timing of PM. For most patients, systemic therapy remains the primary treatment modality, with surgery reserved for rare cases where it can provide meaningful survival benefits [39].

Malignant melanoma

Pulmonary metastases are a common manifestation of malignant melanoma, as the lungs are the most frequent site of visceral spread. Metastatic melanoma has historically been associated with poor survival outcomes; however, pulmonary metastasectomy (PM) has emerged as a potential option for improving survival in selected patients [1,6].

The prognosis of patients with pulmonary metastases from melanoma is influenced by several factors. A disease-free interval (DFI) of more than 12 months, a limited number of pulmonary nodules (typically fewer than three), and the absence of extrathoracic or lymph node metastases are associated with better outcomes. Achieving complete resection (R0) is critical, as incomplete resections are linked to significantly worse survival rates. In addition, patients who respond well to systemic immunotherapy or chemotherapy before surgery tend to achieve more favorable results [6,31].

Despite the aggressive biology of melanoma, several studies have reported promising results for patients undergoing PM. Five-year survival rates range from 4% to 40%, depending on the extent of disease, DFI, and the completeness of resection. Patients with solitary pulmonary nodules and no evidence of systemic progression are the best candidates for surgery [31].

One of the primary challenges in managing pulmonary metastases from melanoma is the high likelihood of recurrence. Even after complete resection, many patients experience disease recurrence, underscoring the need for close postoperative surveillance. For recurrent disease, repeat metastasectomy or systemic therapies, including immunotherapy with immune checkpoint inhibitors, can be considered [1,6].

Multidisciplinary evaluation is essential in determining the role of PM in metastatic melanoma. While surgery alone is unlikely to cure the disease, it can provide meaningful survival benefits for selected patients, particularly when integrated with modern systemic therapies. For patients with limited disease and good systemic control, PM remains an important component of the treatment strategy [31].

Lung cancer

Pulmonary metastasectomy (PM) is occasionally considered in patients with non-small cell lung cancer (NSCLC) who develop secondary lung lesions. Differentiating whether these lesions represent metastases from the primary lung cancer or new primary tumors is critical, as it significantly impacts treatment strategies. For selected patients, PM can serve both diagnostic and therapeutic purposes [31].

In patients with oligometastatic NSCLC, local therapies such as PM have been shown to delay disease progression and, in some cases, improve survival. However, the role of PM in NSCLC is limited to carefully selected patients with controlled primary disease and isolated secondary lesions. Surgical resection is most beneficial when complete resection (R0) is achievable and the patient has no extrathoracic disease [26,31].

For small cell lung cancer (SCLC), systemic therapy remains the primary treatment modality. Metastatic or recurrent SCLC rarely benefits from surgical interventions due to its aggressive nature and widespread dissemination. In exceptional cases, where disease progression is slow and localized, PM may be considered, but such instances are exceedingly rare [31].

A significant challenge in managing pulmonary metastases in lung cancer lies in distinguishing metastatic lesions from second primary lung cancers. This is especially relevant for patients with solitary nodules or lesions in the contralateral lung. In such cases, PM can provide a definitive pathological diagnosis and guide subsequent treatment decisions. Achieving R0 resection remains crucial for maximizing potential survival benefits [31].

Although PM is not a standard treatment for metastatic lung cancer, studies have reported five-year survival rates ranging from 15% to 30% in carefully selected NSCLC patients. These outcomes underscore the importance of patient selection and the need for multidisciplinary discussions to assess the feasibility of surgery. For SCLC, however, survival outcomes with PM remain poor, reinforcing the importance of systemic therapies [26,31].

Pediatric cancers

Pulmonary metastases are a common occurrence in pediatric cancers, particularly in solid tumors such as osteosarcoma, Ewing sarcoma, hepatoblastoma, and Wilms tumor. These metastases are often associated with poor prognosis, but pulmonary metastasectomy (PM) has proven to be a valuable component of multimodal therapy for selected pediatric patients [6,40].

Osteosarcoma and Ewing sarcoma are among the most frequent pediatric cancers to metastasize to the lungs. In osteosarcoma, approximately 30–40% of patients develop pulmonary metastases, often during or after initial treatment. PM offers significant survival benefits for patients with limited disease and a longer disease-free interval (DFI). Studies on surgical morbidity and survival outcomes in osteosarcoma patients emphasize the critical role of pulmonary metastasectomy in improving long-term survival [41-43]. Five-year survival rates for these patients range from 20% to 40%, provided that R0 resection is achieved. Similarly, in Ewing sarcoma, PM combined with systemic therapy and, in some cases, radiotherapy has been shown to improve long-term outcomes [6,40].

Hepatoblastoma frequently metastasizes to the lungs, particularly in advanced cases. For patients with persistent pulmonary nodules following chemotherapy, PM can provide a pathway to long-term survival. Studies report five-year survival rates of 50-65% for patients undergoing PM after initial systemic therapy. Complete resection is critical, as incomplete resections do not offer survival benefits [40].

Approximately 10% of children with Wilms tumor present with pulmonary metastases. Advances in chemotherapy and radiotherapy have significantly improved outcomes for these patients, but PM remains an important option for those with residual disease following systemic therapy. In selected cases, PM has been associated with five-year survival rates as high as 88% [40].

The decision to perform PM in pediatric patients requires a multidisciplinary approach involving pediatric oncologists, thoracic surgeons, and radiation oncologists. Factors such as the number of metastases, the response to systemic therapy, and the feasibility of achieving complete resection are critical in determining the suitability of surgery. Repeat metastasectomy may also be considered for recurrent disease, provided that the patient's overall condition allows for additional surgical intervention [6,40,44].

Lymph node status

Lymph node involvement plays a pivotal role in determining the prognosis and treatment outcomes of patients undergoing pulmonary metastasectomy (PM). Studies consistently demonstrate that intrathoracic lymph node metastases are associated with worse survival outcomes, regardless of tumor histology. As such, evaluating lymph node status is a crucial step in the preoperative assessment and surgical decision-making process [2-5,12]. Systematic lymphadenectomy has been shown to provide prognostic value, though its therapeutic benefit remains under discussion [16]. Meta-analyses have demonstrated the prognostic significance of lymph node assessment during metastasectomy, underscoring its importance in surgical planning [17].

Patients without lymph node involvement (N0) experience significantly better survival outcomes compared to those with lymph node metastases (N1 or N2). While hilar lymph node involvement (N1) negatively affects survival, mediastinal lymph node metastases (N2) are particularly associated with poor outcomes. Data suggest that the five-year survival rate for node-negative patients ranges from 40% to 50%, whereas it drops below 20% for patients with node-positive disease [17,26,29].

Preoperative imaging, including computed tomography (CT) and positron emission tomography (PET), is essential for identifying suspicious lymph nodes. Hypermetabolic or enlarged lymph nodes on imaging warrant further investigation through invasive staging techniques, such as mediastinoscopy or endobronchial ultrasound (EBUS)-guided fine-needle aspiration. Accurate staging not only refines patient selection but also informs postoperative management and adjuvant therapy decisions [14,26].

The role of systematic lymph node dissection during PM remains controversial. While lymph node sampling or dissection provides valuable prognostic information, its therapeutic benefit is less clear. Recent studies suggest that systematic dissection does not significantly improve overall survival but helps guide postoperative strategies. For patients with documented lymph node involvement, complete resection of both pulmonary and nodal disease is essential to achieve potential survival benefits [16,26,29].

The impact of lymph node involvement varies depending on tumor histology. For instance, renal cell carcinoma patients with lymph node metastases may still benefit from PM, provided that complete resection is achievable. In contrast, node-positive patients with aggressive histologies, such as colorectal cancer or sarcoma, often have worse outcomes. These cases require careful evaluation, as incomplete resection does not provide meaningful survival benefits [16,26,29].

Given the substantial prognostic implications of lymph node involvement, multidisciplinary discussions are crucial in determining the appropriateness of PM. Comprehensive staging and thorough surgical planning can optimize outcomes for patients with node-positive disease [14,26].

Repeated metastasectomy

Pulmonary metastasectomy (PM) is frequently performed in patients who experience disease recurrence following an initial surgery. Recurrence rates can reach as high as 50-70%, depending on the primary tumor type. Despite these high recurrence rates, repeated metastasectomy has consistently been shown to provide meaningful survival benefits in selected patients. Recent systematic reviews highlight that repeat metastasectomy in sarcoma and colorectal cancer patients is associated with substantial survival benefits [28,34-36]. Studies report five-year survival rates of 30% to 50% for patients undergoing repeat resections, particularly when complete resection (R0) is achieved. The International Registry of Lung Metastases highlights the importance of achieving R0 resection during repeat surgeries, as it remains a key determinant of survival outcomes [12,26,27]. In colorectal cancer, combined hepatic and pulmonary resections have been associated with improved survival in carefully selected cases [47].

The suitability of repeat metastasectomy depends on multiple clinical factors. Patients with a longer disease-free interval (DFI), limited recurrent lesions, and good overall health are more likely to benefit from the procedure. Conversely, patients with aggressive tumor biology, rapid recurrence, or short DFIs may have less favorable outcomes. Thorough preoperative evaluation is essential to assess the feasibility of surgery and to determine whether complete resection is achievable [16,19,26].

Planning for repeat metastasectomy requires a multidisciplinary approach involving thoracic surgeons, oncologists, and radiologists. Advanced imaging techniques, such as high-resolution computed tomography (CT) and positron emission tomography (PET), are indispensable for evaluating the extent of recurrent disease and assessing resectability. Accurate imaging and staging are critical to optimizing surgical outcomes and avoiding unnecessary procedures [16,26].

While repeat metastasectomy offers significant survival benefits, it is not without challenges. Adhesions and scarring from previous surgeries can complicate the procedure, requiring meticulous surgical planning and technique. Despite these technical difficulties, repeat resections provide an opportunity for prolonged survival and improved quality of life for patients who meet the criteria for surgery [16,20].

Bilateral pulmonary metastasectomy

Bilateral pulmonary metastasectomy poses unique challenges, as it requires addressing metastatic disease in both lungs while preserving adequate pulmonary function and minimizing perioperative risks. Despite the technical complexities, the procedure offers comparable survival benefits to unilateral resections when complete resection is achieved.

Comprehensive preoperative evaluation is essential for determining the feasibility of surgery. High-resolution imaging techniques, such as computed tomography (CT) and positron emission tomography (PET), play a crucial role in identifying the number, size, and location of metastatic lesions in both lungs. Intraoperative assessment, including manual palpation or thoracoscopic evaluation, ensures that smaller or undetected nodules are not missed during the procedure.

The timing and approach for bilateral resections are highly individualized. Simultaneous bilateral resections, performed via median sternotomy or clamshell thoracotomy, enable the removal of all detectable lesions in a single operation. However, this strategy may carry higher perioperative risks and requires careful planning to ensure sufficient postoperative pulmonary function. Alternatively, staged resections addressing one lung at a time are often preferred for patients with higher surgical risks or more extensive disease.

Long-term outcomes for patients undergoing bilateral pulmonary metastasectomy depend on factors such as the extent of disease, the feasibility of achieving complete resection, and the biology of the primary tumor. While technically demanding, the procedure remains a viable and effective option for patients with resectable disease in both lungs. Postoperative care, including close surveillance for recurrence and pulmonary rehabilitation, is critical to optimizing outcomes and ensuring long-term survival.

Prognostic factors for overall survival

Treasure and Macbeth emphasized the importance of patient selection in ensuring the credibility and benefits of pulmonary metastasectomy [45]. Several prognostic factors significantly influence overall survival outcomes for patients undergoing pulmonary metastasectomy (PM). These include the histology of the primary tumor, completeness of resection, disease-free interval (DFI), number and distribution of metastases, and lymph node

status. Understanding these factors is essential for optimizing patient selection and tailoring surgical interventions. Emerging evidence highlights the role of molecular and radiological markers in improving patient selection and refining prognostic predictions [48].

The histology of the primary tumor remains one of the strongest determinants of survival. Favorable outcomes have been observed in patients with germ cell tumors and colorectal cancer metastases, where five-year survival rates often exceed 40%. Conversely, more aggressive tumor types, such as sarcomas and melanomas, are associated with poorer outcomes, emphasizing the need for careful patient selection [7,25].

Achieving a complete resection (R0) is paramount to improving survival. Incomplete resections (R1 or R2) are strongly associated with poor outcomes and are generally considered a contraindication unless performed for palliative reasons. Studies consistently show that patients undergoing R0 resection have significantly better survival outcomes compared to those with residual disease [7,12].

The disease-free interval (DFI) also plays a critical role. Longer DFIs, particularly those exceeding 12 or 36 months, correlate with improved survival. Patients with synchronous metastases or shorter DFIs may still benefit from surgery, but their prognosis tends to be less favorable. For example, patients with DFIs shorter than 12 months generally have lower five-year survival rates compared to those with longer intervals [7].

The number and distribution of pulmonary metastases also impact outcomes. While patients with solitary metastases tend to have the best results, survival benefits can still be achieved in patients with multiple nodules if complete resection is feasible. Modern imaging techniques and intraoperative palpation are indispensable for detecting all metastases, particularly in patients with smaller or deeper lesions.

Lymph node involvement remains a major prognostic factor. Patients without lymph node metastases (N0) have superior outcomes compared to those with hilar (N1) or mediastinal (N2) involvement. While N1 disease carries a moderate impact on survival, N2 involvement is associated with significantly worse outcomes. Accurate preoperative staging using advanced imaging and, when necessary, invasive techniques is crucial for determining surgical eligibility.

Overall, the literature reports five-year survival rates following pulmonary metastasectomy ranging from 20% to 48%, and 10-year survival rates from 15.8% to 37.7%, across all primary tumor types [7,25]. These survival outcomes highlight the potential benefits of PM in carefully selected patients, even in cases with a high metastatic burden.

The laterality of metastases also influences survival outcomes. Patients with unilateral disease generally achieve better results than those requiring bilateral resections. However, bilateral resections can still provide survival benefits when complete resection is achievable and sufficient pulmonary reserve is preserved.

In summary, a comprehensive understanding of these prognostic factors enables clinicians to better identify patients who are most likely to benefit from pulmonary metastasectomy. Multidisciplinary collaboration remains critical in optimizing patient selection and maximizing the therapeutic potential of surgery.

Alternative local therapies to metastasectomy

For most tumor histologies, pulmonary metastasectomy (PM) remains the primary local treatment option, as no proven medical alternatives offer equivalent survival benefits. Exceptions to this include patients with nonseminomatous germ cell tumors or, potentially, metastatic breast cancer, where systemic therapies may achieve curative outcomes without surgical risks. In such cases, consultation with a medical oncologist is essential before proceeding with surgery [25].

For patients who do not meet the criteria for metastasectomy or are unable to tolerate surgery, ablative therapies provide an alternative. These nonoperative options include stereotactic body radiation therapy (SBRT), radiofrequency ablation (RFA), and microwave ablation (MWA), which have been increasingly employed in the management of pulmonary metastases [1,22].

Stereotactic ablative body radiation

Traditionally, radiation therapy has been used for palliation in patients with pulmonary metastases. However, retrospective studies have shown promising local control rates with SABR in select patients. Three-year control rates range from 75% to 90%, with particularly high success observed in small, well-defined lesions. Institutions typically use criteria such as poor surgical candidacy, centrally located lesions, or short disease-free intervals to identify appropriate candidates for SABR [1,9].

SABR is an excellent noninvasive alternative to surgery, delivering high-dose, highly conformal radiation while minimizing exposure to surrounding healthy tissues. Meta-analyses of colorectal cancer (CRC) patients undergoing SABR report local control rates of 81% at one year, 66% at two years, and 60% at three years. These outcomes highlight the expanding role of SABR as both a primary treatment and a consolidative therapy following surgery [49].

Transthoracic ablation

Radiofrequency ablation (RFA) and microwave ablation (MWA) are widely used transthoracic techniques that cause thermal necrosis of tumor tissue. RFA, which uses alternating current to induce coagulative necrosis, is particularly effective for lesions smaller than 3 cm and located away from critical structures. MWA uses higher frequencies and greater thermal energy, allowing it to treat larger tumors or those near vascular structures [1,9].

These techniques are most often employed in patients who are ineligible for surgery but meet specific criteria, such as controlled extrapulmonary disease, three or fewer nodules per hemithorax, and nodules ideally smaller than 2 cm. Studies on colorectal pulmonary metastases have shown that tumor size greater than 2 cm is associated with poorer survival and local control, while low carcinoembryonic antigen (CEA) levels (<10 ng/mL) predict better outcomes [49].

While PM remains the gold standard for patients eligible for surgery, SABR, RFA, and MWA are valuable alternatives for non-surgical candidates. The choice of treatment depends on tumor size, location, patient condition, and prior therapies. Emerging evidence suggests that MWA may offer improved local control compared to RFA, but further data from large cohorts are needed to validate these findings.

Future

Recent advancements in surgical techniques and perioperative management have expanded the possibilities for pulmonary metastasectomy (PM). Innovations such as radial staplers, near-infrared (NIR) imaging, and laser-assisted surgery are at the forefront of these developments, offering potential improvements in precision, safety, and outcomes.

Radial staplers, although not yet widely adopted, represent a promising innovation in thoracic surgery. Compared to conventional linear staplers, radial staplers allow for more precise wedge resections while preserving lung parenchyma and maintaining adequate surgical margins. Their role in PM is expected to grow as evidence supporting their benefits becomes more robust [3].

Laser-assisted surgery (LAS) is another emerging technique that offers distinct advantages in cases with multiple pulmonary metastases. LAS enables surgeons to perform precise and tissue-sparing resections, allowing for the removal of a higher number of metastases compared to stapler resections. Furthermore, its ability to preserve parenchyma makes it particularly valuable in patients with limited pulmonary reserve or recurrent disease requiring multiple resections. However, comparative studies evaluating LAS versus conventional methods remain limited, and further data are needed to validate its long-term safety and efficacy [3].

Near-infrared (NIR) spectroscopy, used alongside minimally invasive techniques like video-assisted thoracoscopic surgery (VATS) and robotic-assisted thoracoscopic surgery (RATS), is transforming the landscape of pulmonary metastasectomy. NIR imaging, often guided by the intravenous administration of indocyanine green (ICG), allows for real-time identification of intersegmental planes during segmentectomy. This technology enhances the precision of anatomical resections, reducing the risk of incomplete resection and improving outcomes [3].

As systemic therapies continue to evolve, their integration with surgical interventions is becoming increasingly relevant. Immunotherapy and targeted treatments, such as checkpoint inhibitors and tyrosine kinase inhibitors, have shown promise in reducing metastatic burden before surgery or preventing recurrence after metastasectomy. Future studies are needed to optimize the sequencing and combination of systemic therapies with PM to maximize survival [3,49].

While PM remains the gold standard for many patients, non-surgical options such as stereotactic ablative radiotherapy (SABR) and percutaneous ablation techniques are gaining traction. These approaches, which offer minimally invasive alternatives for non-surgical candidates, are continuously being refined with the advent of new technologies and improved imaging. Ongoing clinical trials are evaluating their role in extending survival and reducing complications in patients with pulmonary metastases [49].

The future of PM lies in the personalization of care. Advances in genomic and molecular profiling will enable clinicians to better predict which patients are most likely to benefit from surgery. Additionally, the identification of biomarkers for treatment response and recurrence risk will further refine patient selection, ensuring that interventions are tailored to individual tumor biology and patient characteristics [49].

Pulmonary metastasectomy is an ever-evolving field, driven by technological innovation, improved systemic therapies, and a deeper understanding of tumor biology. As these advancements continue, they hold the potential to further improve outcomes and expand treatment options for patients with metastatic lung disease.

In conclusion, pulmonary metastasectomy (PM) remains a cornerstone of treatment for selected patients with metastatic lung disease, offering a potential survival benefit in carefully chosen cases. The procedure's success is largely dependent on a multidisciplinary approach that incorporates the expertise of thoracic surgeons, oncologists, radiologists, and other specialists. This collaboration ensures that patients are appropriately selected based on key prognostic factors, such as histology, disease-free interval (DFI), number of metastases, and lymph node status.

The primary goals of PM are to achieve complete resection (R0), prolong survival, and, in some cases, improve quality of life by alleviating symptoms caused by metastatic lesions. Achieving clear surgical margins is critical, as incomplete resections (R1 or R2) fail to provide survival benefits and may expose patients to unnecessary risks.

Despite the significant advances in systemic therapies, including immunotherapy and targeted treatments, PM continues to play a vital role in the management of metastatic lung disease. For patients with isolated pulmonary metastases and controlled primary disease, surgery offers a unique opportunity for long-term survival that may not be achievable through systemic treatments alone.

Future research should focus on integrating metastasectomy with evolving systemic therapies to further enhance outcomes. The development of novel imaging techniques, more precise surgical tools, and predictive biomarkers will also help refine patient selection and optimize surgical planning. Ultimately, a personalized approach that considers tumor biology, patient condition, and treatment goals will be essential to maximizing the benefits of PM.

Pulmonary metastasectomy remains a valuable intervention in the multidisciplinary management of metastatic lung disease. By leveraging the latest advancements in surgery and systemic therapy, clinicians can continue to improve outcomes and provide meaningful survival benefits to selected patients.

Declaration of conflicting interests

The authors declared no conflicts of interest with respect to the authorship and/or publication of this article.

Funding

The authors received no financial support.

Authors' contribution

All authors contributed significantly to the drafting and revision of the manuscript and approved the final version.

References

1. Sudarshan M, Murthy SC. Current Indications for Pulmonary Metastasectomy. Surg Oncol Clin N Am 2020; 29: 673-83.
2. Kanzaki R, Fukui E, Kanou T, Ose N, Funaki S, Minami M et al. Preoperative evaluation and indications for pulmonary metastasectomy. J Thorac Dis 2021; 13: 2590-602.
3. Mangiameli G, Cioffi U, Alloisio M, Testori A. Pulmonary Metastases: Surgical Principles, Surgical Indications, and Innovations. In: Sergi CM, editor. Metastasis [Internet]. Brisbane (AU): Exon Publications; 2022 May 3. Chapter 4. PMID: 35679451.
4. Mangiameli G, Cioffi U, Alloisio M, Testori A. Lung Metastases: Current Surgical Indications and New Perspectives. Front Surg 2022; 9: 884915.
5. Eisenberg M, Deboever N, Antonoff MB. Pulmonary Metastasectomy: Indications, Best Practices, and Evolving Role in the Future. Thorac Surg Clin 2023; 33: 149-58.
6. Petrella F, Diotti C, Rimessi A, Spaggiari L. Pulmonary metastasectomy: an overview. J Thorac Dis 2017; 9(Suppl 12): S1291-8.
7. Cheung FP, Alam NZ, Wright GM. The Past, Present and Future of Pulmonary Metastasectomy: A Review Article. Ann Thorac Cardiovasc Surg 2019; 25: 129- 41.
8. Ripley RT, Downey RJ. Pulmonary metastasectomy. J Surg Oncol 2014; 109: 42-6.
9. Handy JR, Bremner RM, Crocenzi TS, Detterbeck FC, Fernando HC, Fidias PM et al. Expert Consensus Document on Pulmonary Metastasectomy. Ann Thorac Surg 2019; 107: 631-49.

10. Meng D, Fu L, Wang L, Dai Y, Lv W, Zhang J et al Video-assisted thoracoscopic surgery versus open thoracotomy in pulmonary metastasectomy: a meta-analysis of observational studies. Interact Cardiovasc Thorac Surg 2016; 22: 200-6.

11. Cheang MY, Herle P, Pradhan N, Antippa P. Video-assisted thoracoscopic surgery versus open thoracotomy for pulmonary metastasectomy: a systematic review. ANZ J Surg 2015; 85: 408-13.

12. Hornbech K, Ravn J, Steinbrüchel DA. Current status of pulmonary metastasectomy. Eur J Cardiothorac Surg 2011; 39: 955-62.

13. Nichols FC. Pulmonary metastasectomy: role of pulmonary metastasectomy and type of surgery. Curr Treat Options Oncol 2014; 15: 465-75.

14. Reinersman JM, Wigle DA. Lymphadenectomy During Pulmonary Metastasectomy. Thorac Surg Clin 2016; 26: 35-40.

15. Sihag S, Muniappan A. Lymph Node Dissection and Pulmonary Metastasectomy. Thorac Surg Clin 2016; 26: 315-23.

16. Welter S, Gupta V, Kyritsis I. Lymphadenectomy in pulmonary metastasectomy. J Thorac Dis 2021; 13: 2611-7.

17. Minervini F, Li A, Qu M, Nilius H, Shargall Y. Prognostic significance of lymph nodes assessment during pulmonary metastasectomy: a systematic review and meta-analysis. J Thorac Dis 2023; 15: 6447-58.

18. Nichols FC. Pulmonary metastasectomy. Thorac Surg Clin 2012; 22: 91-9.

19. Jaklitsch MT, Jett JR, Singh A. Surgical resection of pulmonary metastases: Benefits, indications, preoperative evaluation and techniques. In: Friedberg JS, editor. UpToDate. Vallières E: UpToDate; 2024.

20. Ambrogi V, Tamburrini A, Tajé R. Results of redo pulmonary metastasectomy. J Thorac Dis 2021; 13: 2669-85.

21. Li Y, Zhang W, Li S, Tu C. Clinical efficiency of repeated pulmonary metastasectomy in sarcoma patients with recurrent pulmonary metastasis: A meta-analysis. J Cancer Res Ther 2018; 14(Supplement): S457-62.

22. Grapatsas K, Papaporfyriou A, Leivaditis V, Ehle B, Galanis M. Lung Metastatectomy: Can Laser-Assisted Surgery Make a Difference? Curr Oncol 2022; 29: 6968-81.

23. Mammana M, Baldi M, Melan L, Dell'Amore A, Rea F. Laser-assisted lung metastasectomy: a systematic review. Updates Surg 2023; 75: 1783-93.

24. Van Raemdonck D. Pulmonary metastasectomy: common practice but is it also best practice? Future Oncol 2015; 11(2 Suppl): 11-4.

25. Erhunmwunsee L, Tong BC. Preoperative Evaluation and Indications for Pulmonary Metastasectomy. Thorac Surg Clin 2016; 26: 7-12.

26. Higashiyama M, Tokunaga T, Nakagiri T, Ishida D, Kuno H, Okami J. Pulmonary metastasectomy: outcomes and issues according to the type of surgical resection. Gen Thorac Cardiovasc Surg 2015; 63: 320-30.

27. Downey RJ, Bains MS. Open Surgical Approaches for Pulmonary Metastasectomy. Thorac Surg Clin 2016; 26: 13-8.

28. Boyer MJ, Ricardi U, Ball D, Salama JK. Ablative Approaches for Pulmonary Metastases. Thorac Surg Clin 2016; 26: 19-34.

29. Krüger M, Schmitto JD, Wiegmann B, Rajab TK, Haverich A. Optimal timing of pulmonary metastasectomy--is a delayed operation beneficial or counterproductive? Eur J Surg Oncol 2014; 40: 1049-55.

30. Gkikas A, Kakos C, Lampridis S, Godolphin PJ, Patrini D. Preoperative prognostic factors for 5-year survival following pulmonary metastasectomy from colorectal cancer: a systematic review and meta-analysis. Eur J Cardiothorac Surg 2023; 63: ezad059.

31. Jaklitsch MT, Kehl KL, Jett JR. Surgical resection of pulmonary metastases: Outcomes by histology. In: Drews RE, editor. UpToDate. Vallières E: UpToDate; 2024.

32. Raveglia F, Rosso L, Nosotti M, Cardillo G, Maffeis G, Scarci M. Pulmonary metastasectomy in germ cell tumors and prostate cancer. J Thorac Dis 2021; 13: 2661-8.

33. Farazdaghi A, Vaughn DJ, Singhal S. Pulmonary Metastasectomy for Germ Cell Tumors. Ann Thorac Cardiovasc Surg 2019; 25: 289-5.

34. Schlachtenberger G, Doerr F, Menghesha H, Lauinger P, Wolber P, Sabashnikov A et al. Patients with Pulmonary Metastases from Head and Neck Cancer Benefit from Pulmonary Metastasectomy, A Systematic Review. Medicina (Kaunas) 2022; 58: 1000.

35. Shiono S. The role of pulmonary metastasectomy for pulmonary metastasis from head and neck cancer. J Thorac Dis 2021; 13: 2643-8.

36. Radulescu IM, Popescu R, Cirstoiu MM, Cordos I, Mischianu D, Cirstoiu CF. Surgical treatment for pulmonary metastases in urogenital cancers. J Med Life 2014; 7: 358-62.

37. Soh J, Komoike Y, Mitsudomi T. Surgical therapy for pulmonary metastasis of breast cancer. Transl Cancer Res 2020; 9: 5044-52.

38. Wang C, Yang L, Liang Z, Liu Y, Liu S. Long-Term Survival and Prognostic Factors of Pulmonary Metastasectomy in Liver Cancer: A Systematic Review and Meta-Analysis. World J Surg 2018; 42: 2153-63.

39. Aurello P, Petrucciani N, Giulitti D, Campanella L, D'Angelo F, Ramacciato G. Pulmonary metastases from gastric cancer: Is there any indication for lung metastasectomy? A systematic review. Med Oncol 2016; 33: 9.

40. Karpelowksy J, Seitz G. A Surgical Approach to Pulmonary Metastasis in Children. Surg Oncol Clin N Am 2021; 30: 389-9.

41. Shell D. Improving survival after pulmonary metastasectomy for sarcoma: analysis of prognostic factors. Gen Thorac Cardiovasc Surg 2023; 71: 263-71.

42. Kuo C, Malvar J, Chi YY, Kim ES, Shah R, Navid F et al. Survival outcomes and surgical morbidity based on surgical approach to pulmonary metastasectomy in pediatric, adolescent and young adult patients with osteosarcoma. Cancer Med 2023; 12: 20231-41.

43. Boam T, Rogoyski BG, Jawaid W, Losty PD. Do children with Osteosarcoma benefit from Pulmonary Metastasectomy? - A Systematic Review Of Published Studies and 'Real world' Outcomes. Ann Surg. 2024; 280: 235-40.

44. Croteau NJ, Heaton TE. Pulmonary Metastasectomy in Pediatric Solid Tumors. Children (Basel). 2019; 6:6.

45. Treasure T, Macbeth F. Pulmonary metastasectomy: limits to credibility. J Thorac Dis 2021; 13: 2603-10.

46. Williams NR, Patrick H, Fiorentino F, Allen A, Sharma M, Milošević M et al. Pulmonary Metastasectomy in Colorectal Cancer (PulMiCC) randomized controlled trial: a systematic review of published responses. Eur J Cardiothorac Surg 2022; 62: ezac253.

47. van Dorp M, Bousema JE, Torensma B, Dickhoff C, van den Broek FJC, Schreurs WH et al. Pulmonary metastasectomy with lymphadenectomy for colorectal pulmonary metastases: A systematic review. Eur J Surg Oncol 2022; 48: 253-60.

48. Schweiger T, Lang G, Klepetko W, Hoetzenecker K. Prognostic factors in pulmonary metastasectomy: spotlight on molecular and radiological markers. Eur J Cardiothorac Surg 2014; 45: 408-16.

49. Antonoff MB, Sofocleous CT, Callstrom MR, Nguyen QN. The roles of surgery, stereotactic radiation, and ablation for treatment of pulmonary metastases. J Thorac Cardiovasc Surg 2022; 163: 495-502.

This article is an open access article distributed under the terms and conditions of the Creative Commons Attribution (CC BY) license (http://creativecommons.org/licenses/by/4.0/).

Current Thoracic Surgery

To cite this article: Kış A, Zenci E, Öztürk G. Management of recurrent spontaneous pneumothorax in twin pregnancy after IVF: a case report. Curr Thorac Surg 2025;10(2):81-84.

Case Report

Management of recurrent spontaneous pneumothorax in twin pregnancy after IVF: a case report

Argün Kış*, Eren Zenci, Gökhan Öztürk

Department of Thoracic Surgery, Pamukkale University, School of Medicine, Denizli, Turkey

ABSTRACT

Background: Spontaneous pneumothorax during pregnancy is a rare condition that can pose significant risks to both the mother and the fetus. This report presents the case of a 35-year-old woman with twin pregnancy resulting from in vitro fertilization who developed recurrent pneumothorax on the right side. The patient was initially treated with tube thoracostomy; however, due to prolonged air leakage, video-assisted thoracoscopic surgery with wedge resection was performed. This case underscores the necessity of a multidisciplinary approach for managing pneumothorax during pregnancy and evaluates optimal treatment strategies in light of current literature.

Keywords: spontaneous pneumothorax, pregnancy, in vitro fertilization, surgery, video-assisted thoracoscopic surgery

Corresponding Author*: Argün Kış, MD. Kınıklı Mah., Pamukkale Üniversitesi Hastanesi Göğüs Cerrahisi Ana Bilim Dalı, Pamukkale, Denizli, Turkey.
E-mail: akis@pau.edu.tr Phone: +90 5389759870
Doi: 10.26663/cts.2025.013
Received 02.03.2025 accepted 29.04.2025

Introduction

Spontaneous pneumothorax (SP) during pregnancy represents a highly uncommon clinical entity, with fewer than 100 cases documented in the extant literature [1-3]. In pregnancy, increased oxygen demand, reduced functional residual capacity, and higher intra-abdominal pressure may predispose individuals to SP [2]. Managing SP in pregnancy poses challenges due to the dual concern for maternal and fetal safety. Although mild cases may be adequately addressed through supplemental oxygen therapy and vigilant monitoring, surgical intervention becomes necessary in instances of recurrent or persistent air leakage [3].

During pregnancy, elevated progesterone levels act as a respiratory stimulant by increasing the sensitivity of the respiratory center to carbon dioxide, leading to enhanced ventilatory drive. Additionally, progesterone induces bronchodilation by relaxing the smooth muscles of the airways and contributes to mucosal hyperemia and edema, which may cause nasal congestion. These hormonal influences collectively alter pulmonary function during gestation [4].

In twin pregnancies resulting from in vitro fertilization (IVF), respiratory complications are hypothesized to be more frequent due to increased intra-abdominal pressure and hormonal changes. However, the relationship between IVF and pneumothorax remains unclear. This case report discusses the management of recurrent pneumothorax in a twin pregnancy following IVF.

Case Report

A 35-year-old pregnant woman with twin pregnancy achieved through IVF was admitted to the emergency department during her second trimester with sudden-onset dyspnea. On initial evaluation, the patient's oxygen saturation was 92% on room air, heart rate was 105 beats per minute, and blood pressure was 129/74 mmHg. Fetal heart rates were confirmed to be normal for both fetuses via bedside ultrasound performed by the obstetrics team. No signs of uterine contractions or vaginal bleeding were noted. She had no history of smoking, underlying lung disease, or trauma. On physical examination, breath sounds were markedly diminished on the right hemithorax. The chest X-ray revealed a right-sided pneumothorax (Figure 1a), and an emergency tube thoracostomy was performed. On the third day of chest tube placement, after 24 hours without air leakage, the chest tube was removed upon confirmation of full lung expansion. The patient was discharged the following day.

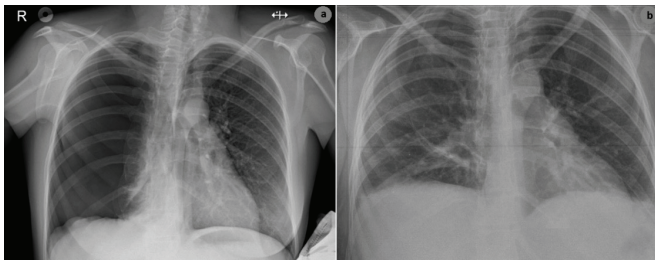

Figure 1. Chest X-ray showing right-sided pneumothorax **(a)**, postoperative chest X-ray showing full lung expansion before discharge **(b)**.

A recurrent pneumothorax was detected on chest X-ray one week after hospital discharge. Tube thoracostomy was performed again. Nevertheless, surgical management was planned due to persistent air leakage and lung expansion failure. Conservative treatment was initially attempted, but due to the failure of lung re-expansion and continued air leakage, it was decided that the conservative treatment should not be extended, considering the risk of infectious and respiratory complications. Bullous structures in the right upper and middle lobes were identified using video-assisted thoracoscopic surgery (VATS) (Figure 2), and wedge resection and pleural abrasion were achieved.

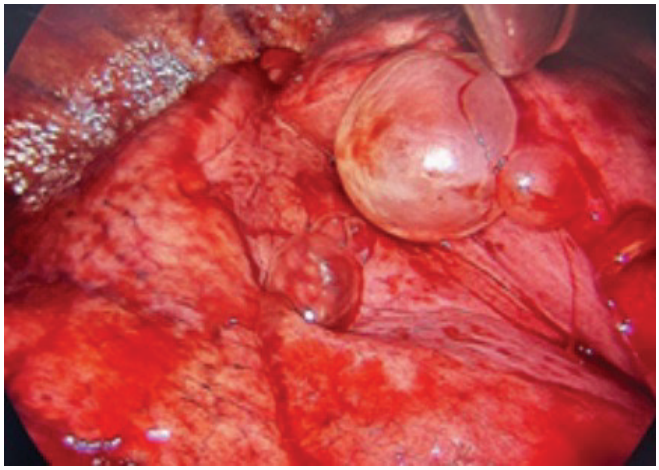

Figure 2. The image during VATS showing bullous lesions in the right upper and middle lobe.

The postoperative period was uneventful, and no obstetrical complications were observed. During hospitalization, analgesic management was provided with paracetamol, and prophylactic antibiotics were administered according to institutional protocols (cefazolin). No deviations from standard obstetric or thoracic surgical anesthesia protocols were required. The chest tube was removed on the third postoperative day. The control chest X-ray after removal confirmed full lung expansion (Figure 1b). Both infants were delivered healthy with no obstetric or neonatal complications observed. The patient underwent an elective cesarean section under

epidural anesthesia. Epidural anesthesia during delivery was chosen to minimize hemodynamic fluctuations and maternal respiratory strain, in accordance with best practices for pregnant patients with prior pulmonary complications. No recurrence or respiratory complications were noted during follow-up. Written informed consent was obtained from the patient for the use of the medical data in academic studies.

Discussion

The patient was monitored by the gynecology and obstetrics department throughout hospitalization, with daily consultations for fetal and maternal assessment and necessary medical adjustments. The obstetric council approved proceeding with pneumothorax surgery. This case highlights the challenges of managing spontaneous pneumothorax during pregnancy and underscores the necessity of a multidisciplinary approach. In this case, a coordinated effort between thoracic surgery, obstetrics, and anesthesiology teams ensured optimal care. Preoperative planning with the anesthesiology team allowed for stable maternal hemodynamics throughout surgery. Simultaneously, the obstetrics team provided daily assessments to monitor fetal development and viability. This collaborative approach enabled effective management of maternal and fetal risks both before and after surgery, contributing to a favorable outcome for both the mother and the fetuses.

SP in pregnancy is extremely rare, with fewer than 100 cases reported in the literature [1]. Although pneumothorax is most commonly observed in the third trimester, cases have also been reported in the first and second trimesters [2,3,5]. Risk factors include pre-existing lung diseases, bullous formations, smoking history, respiratory infections, and increased intrathoracic pressure during labor [6]. In this case, a prior history of pneumothorax and the presence of bullous lesions observed in the right upper and middle lobes during surgery are consistent with the known risk factors for spontaneous pneumothorax. Additionally, conditions such as twin pregnancy following IVF may further contribute to pneumothorax development due to increased intra-abdominal pressure and hormonal changes [3,5,6], although the exact mechanism remains unclear.

For the diagnosis of pneumothorax during pregnancy, a maternity lead apron chest X-ray is recommended as the primary imaging modality [3]. Thoracic ultrasound serves as a safe alternative due to its lack of radiation exposure [2]. High-resolution computed tomography (HRCT) may be considered in recurrent cases; however, radiation exposure should be minimized during pregnancy [5]. The chest x ray was obtained after tube insertion, just before chest tube removal and after removal to confirm the lung expansion; and the day after surgery for potential complications. Lead apron was used to shield the fetus. A thorax computed tomography is planned after pregnancy for evaluation of lung parenchyma.

Treatment strategies depend on the pneumothorax size and the patient's symptoms. In small pneumothoraces (<20%), oxygen support and close monitoring may suffice for asymptomatic patients [6]. Larger pneumothoraces or symptomatic cases require tube thoracostomy [5]. In cases of prolonged air leakage (typically exceeding 5-7 days) or recurrent pneumothorax, surgical intervention becomes necessary [1]. VATS, with wedge resection and pleurodesis, offers significant advantages over open surgery, including less postoperative pain, shorter hospital stays, and lower recurrence rates [2,6]. In this case, VATS was preferred over thoracotomy not only for its minimally invasive advantages but also due to its more favorable hemodynamic profile, which is particularly important during pregnancy.

When planning surgical intervention during pregnancy, maternal and fetal safety should be prioritized. Throughout the patient's hospital stay, daily fetal monitoring was conducted in collaboration with obstetric specialists. In cases of maternal respiratory failure, cesarean delivery may be considered [3], although spontaneous vaginal delivery is generally deemed safe [5]. Epidural anesthesia may be preferred during delivery to minimize maternal exertion [3]. In this case, the patient delivered via elective cesarean section under epidural anesthesia, which was well tolerated and contributed to maternal-fetal stability. At the time of the initial pneumothorax diagnosis, the patient was at 24 weeks of gestation. Delivery occurred electively at 36 weeks of gestation. Despite the episodes of pneumothorax and surgical intervention, no evidence of preterm labor or intrauterine growth restriction was observed, and fetal development progressed appropriately throughout the pregnancy. No complications arose, eliminating the need for additional interventions.

In conclusion, this case underscores that, although infrequent, spontaneous pneumothorax may arise in twin pregnancies conceived via in vitro fertilization.

Expeditious diagnosis, judicious surgical intervention when warranted, and interdisciplinary collaboration are imperative to optimize outcomes for both the mother and the fetuses.

Declaration of conflicting interests

The authors declared no conflicts of interest with respect to the authorship and/or publication of this article.

Funding

The authors received no financial support.

Authors' contribution

AK; organized the article and wrote the paper, AK,EZ; contributed to the data collection, AK,EZ,GÖ; revised the article. All authors revised the manuscript. The authors read and approved the final manuscript.

References

1. VanWinter JT, Nichols FC 3rd, Pairolero PC, Ney JA, Ogburn PL Jr. Management of spontaneous pneumothorax during pregnancy: case report and review of the literature. Mayo Clin Proc 1996; 71: 249-52.
2. Nwaejike N, Aldam P, Pulimood T, Giles R, Brockelsby J, Fuld J, et al. A case of recurrent spontaneous pneumothorax during pregnancy treated with video assisted thoracoscopic surgery. BMJ Case Rep 2012; 2012: bcr0520114282.
3. Akçay O, Uysal A, Samancılar O, Ceylan KC, Sevinc S, Kaya SO. An unusual emergency condition in pregnancy: pneumothorax. Case series and review of the literature. Arch Gynecol Obstet 2013; 287: 391-4.
4. LoMauro A, Aliverti A. Respiratory physiology of pregnancy: Physiology masterclass. Breathe (Sheff). 2015; 11: 297-301.
5. Kavurmacı Ö, Akçam Tİ, Kavurmacı SA, Turhan K, Çağırıcı U. Pneumothorax: A Rare Entity During Pregnancy. Turk Thorac J 2019; 20: 206-8.
6. Hakimi AA, Sellers MM, Morton AP. Spontaneous Recurrent Pneumothorax during Pregnancy Secondary to Ectopic Deciduosis. Thorac Cardiovasc Surg Rep 2022; 11: e67-e69.

This article is an open access article distributed under the terms and conditions of the Creative Commons Attribution (CC BY) license (http://creativecommons.org/licenses/by/4.0/).

Current Thoracic Surgery

To cite this article: Ekici MA, Turan O, Metin B, Özsoy İE, Tezcan MA. Successful treatment of an endobronchial schwannoma by bronchoscopic application of electrocautery: a case report. Curr Thorac Surg 2025;10(2):85-88.

Case Report

Successful treatment of an endobronchial schwannoma by bronchoscopic application of electrocautery: a case report

Mehmet Akif Ekici, Oğuzhan Turan, Bayram Metin*, İbrahim Ethem Özsoy, Mehmet Akif Tezcan

Department of Thoracic Surgery, Kayseri Education and Research Hospital, Kayseri, Turkey

ABSTRACT

Schwannomas, also referred to as neurilemmomas, are benign neoplasms arising from Schwann cells within the peripheral nervous system. These tumors may develop at various anatomical sites, including the respiratory system, most commonly involving the chest wall and posterior mediastinum. Primary tracheobronchial schwannomas are exceedingly rare. In this report, we present the case of a 22-year-old male patient with an endotracheal schwannoma originating from the carina and extending into the trachea.

Keywords: schwannoma, endobronchial lesion, bronchoscopy

Corresponding Author*: Bayram Metin, MD. Kayseri Şehir Eğitim Araştırma Hastanesi, Göğüs Cerrahi Eğitim Kliniği, Kayseri, Turkey.
E-mail: drbaymet@hotmail.com Phone: +90 5072385361
Doi: 10.26663/cts.2025.014
Received 08.05.2025 accepted 08.07.2025

Introduction

Schwannomas are well-circumscribed, benign neoplasms originating from Schwann cells in the peripheral nervous system. These tumors are most frequently observed in the mediastinum, retroperitoneum, paraspinal nerve roots, and cerebellopontine angle. Schwannomas located within the endotracheal or endobronchial spaces are exceedingly rare [1]. Due to the atypical clinical presentation and the scarcity of such cases in the literature, we present the case of a 22-year-old male with endotracheal schwannoma arising from the carina and extending into the trachea.

Case Report

A 22-year-old male patient was referred from an external medical facility with complaints of cough, wheezing, fever, purulent sputum production, and dyspnea. The patient was evaluated upon presentation to the emergency department. Laboratory investigations demonstrated a leukocyte count of 25.87 × 10^9/L, a neutrophil-to-lymphocyte ratio of 93.5, a hemoglobin concentration of 14.6 g/dL, and a platelet count of 361,000/μL, as well as CRP 353. The patient exhibited cyanosis, and arterial blood gas analysis revealed a pH of 7.45, paCO2 of 38 mm Hg, paO2 of 48.5 mm Hg, and sO2 of 84%. Computed tomography of the trachea demonstrated a 15 × 14 mm soft tissue mass extending from the right lateral wall into the lumen of the distal trachea, in addition to localized pneumonic infiltrates in both lower lung lobes (Figure 1).

The patient was hospitalized, and antibiotic treatment was initiated due to cyanosis and evidence of infection. Rigid bronchoscopy revealed a mass lesion at the distal end of the trachea, resulting in approximately 80% luminal narrowing. The mass was manipulated using a bronchoscopic cautery aspirator. The lesion was mobile and demonstrated a pedicle originating from the right lateral aspect of the carina. The mass was excised and removed in fragments using forceps. The pedicle of the coagulated lesion was ablated with cautery forceps, and complete luminal patency was achieved to prevent residual tumor tissue. Secretions were aspirated from both bronchial systems. Upon re-examination of the endobronchial site with an optical camera, it was confirmed that the lesion had been completely excised, with no evidence of residual tumor tissue (Figure 2).

The patient's cyanosis improved in the early postoperative period, and acute phase reactants decreased rapidly. The patient was discharged with significant recovery of consolidation in the lower lobes on radiologic follow-up. Histopathological examination of the excised tissue confirmed the diagnosis of schwannoma, characterized by spindle-shaped cells arranged in intersecting fascicles, the presence of Antoni A and Antoni B areas, and strong S-100 protein positivity on immunohistochemical staining.

At the fourth-month follow-up after discharge, the patient reported no complications or complaints (Figure 3). Written informed consent was obtained from the patient for the use of the medical data in academic studies.

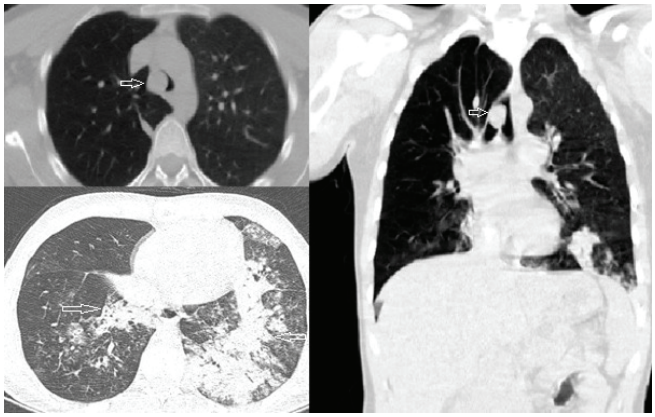

Figure 1. Thoracic CT images showing the appearance of the mass at the carina level and the appearance of obstructive pneumonia in bilateral lower lobes.

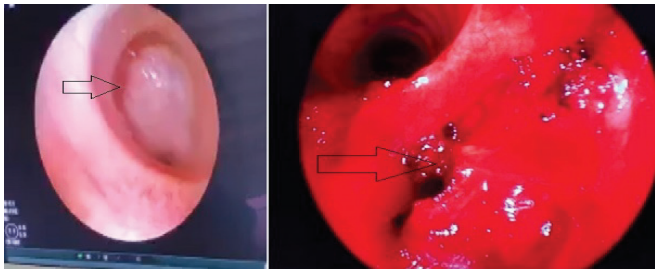

Figure 2. Bronchoscopic images of the mass before excision and during excision with electrocautery.

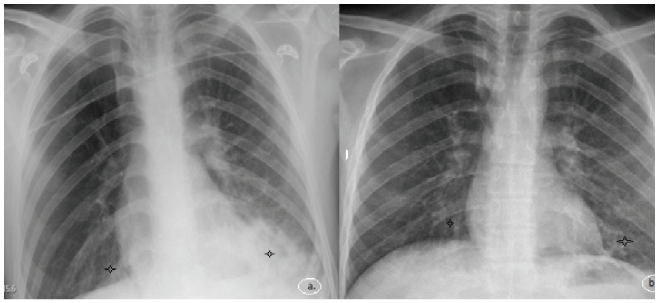

Figure 3. Preoperative PA radiograph images **(a)**, postoperative PA radiograph images **(b).**

Discussion

Schwannomas, also known as neurilemmomas, are benign tumors that develop in the peripheral nervous system from Schwann cells [1]. Schwann cell, named after Theodor Schwann, is a type of glia cell in the peripheral nervous system. Glia cells are in charge of providing support to neurons in the peripheral nervous system. There are two types of Schwann cells: one is in charge of myelination, while the other does not participate in it. The myelin sheath is formed by Schwann cells that wrap around the axons of motor and sensory neurons. Myelin-sheathed nerve fibers allow for rapid transmission of action potentials [2].

Schwannomas can occur anywhere in the body, but they are most common in the mediastinum, retroperitoneum, spinal nerve, legs, and cerebellopontine angle. They can be found in the respiratory system, particularly the chest wall and posterior mediastinum. Primary tracheobronchial schwannomas are extremely rare, accounting for 0.2% of all bronchopulmonary tumors, as in our study [1].

The neural structures in the trachea containing Schwann cells are the pulmonary plexus structures with parasympathetic and sympathetic denervation, where Schwannomas develop. The parasympathetic part of this structure is derived from vagus nerve branches, while the sympathetic part is derived from paravertebral sympathetic trunks. The pulmonary plexus is responsible for a variety of functions, including bronchial smooth muscle tone, submucosal glandular mucus secretion, vascular permeability, and blood flow [3].

The first case of bronchial schwannoma was described as a smooth and nodular endobronchial lesion in 1951 [4]. Although it has been reported that primary tracheal schwannomas are observed at a high incidence in adult females of the Asian population, there are also cases reported in childhood and older ages in the literature [1,5].

Although the etiology of schwannomas is unknown, it has been reported that loss and change in the NF2 (neurofibromatosis type 2) gene product of the 22nd chromosome may be related to neurofibromatosis and radiation exposure may play a role in the etiology [2].

Due to their slow growth, most endobronchial schwannomas remain asymptomatic for many years and are usually discovered incidentally during radiological examinations. As in this case, symptomatic patients experience obstruction and obstructive pneumonia symptoms such as cough, hemoptysis, fever, and dyspnea due to the mass obstructing the trachea or main bronchi [6,7].

Tracheobronchial malignant squamous cell carcinomas and adenoid cystic carcinomas are common lesions in the differential diagnosis of endobronchial schwannomas. Carcinoid tumors, malignant fibrosis tumors, rhabdomyosarcomas, hemangioma, laryngotracheal chondroma, granular cell tumors, benign fibrosis tumors, and inflammatory myofibroblastic tumors are also differential diagnoses [1,5,8].

Radiologically, primary endobronchial schwannomas are seen as a sharply circumscribed round, ovoid, or lobule homogenous mass. Thoracic CT examination may reveal the size and location of the mass, as well as whether it has spread outside the lumen [7,8].

Since primary malignant schwannomas are rare and have no specific radiologic or clinical symptoms or findings, it is not possible to predict the exact diagnosis by clinical and radiologic evaluations. However, the histopathologic examination of the tissue obtained by bronchoscopy may provide a definitive diagnosis [2,5,8]. There were radiological interpretations suggesting mucocele or carcinoid tumor in our case. A rigid bronchoscopy excisional biopsy revealed Schwannoma.

Surgery is the gold standard treatment for primary tracheal schwannomas. Surgical treatment options include a wide range of surgical procedures, ranging from sleeve bronchial resection to lung resection, depending on the lesion's location and invasion status, as well as the state of destruction of the distal lung. Similarly, depending on the location of the lesion, whether or not the lesion has a pedicle or not, blood supply, and the presence of co-morbid conditions in the patient, endobronchial treatment modalities should be considered in certain cases. Successful results have been reported in the literature with local radiotherapy applications in cases that cannot be treated surgically or endobronchially [7-9]. Surgery is the gold standard treatment for primary tracheal schwannomas, as emphasized in previous studies on the management of primary tracheal tumors [10]. The lesion in our case was a lesion that almost completely obstructed the trachea at the level of the main carina. Bronchoscopy revealed that the mass grew upwards from a pedicle on the right main bronchial side of the carina to the trachea. It was mobile when touched and provided a lumen opening with its movement. This

showed that the patient was breathing. Since the lesion had a pedicle and was mobile, the lesion was firstly coagulated using a cautery aspirator via electrocautery to stop and control the bleeding. It was then excised completely using rigid bronchoscopy forceps. There was no residual tumor in our patient, so no additional intervention or surgical procedure was required. In the third month following the procedure, the patient, whom we closely monitored, had no active complaint.

In conclusion, primary tracheal schwannomas represent rare benign neoplasms of the trachea with a low risk of malignant transformation. This report underscores that endobronchial electrocautery using rigid bronchoscopy, when performed in centers experienced in endobronchial interventions, may constitute a safe and effective therapeutic approach for the management of endobronchial schwannomas.

Declaration of conflicting interests

The authors declared no conflicts of interest with respect to the authorship and/or publication of this article.

Funding

The authors received no financial support.

Author contribution

BM; radiological assesment and radiological image arrangement, BM,MAE,OT; surgical assesment and detailed patient information collection, İEÖ; Haematological assesment, MAT; general consideration and approval of the whole paper. All authors revised the manuscript. The authors read and approved the final manuscript.

References

1. Lina G, Pengguo H, Zhihua X, Jianxin W, Baoqin B, Mingyue Z, Junping S. Tracheobronchial schwannoma: a case report and literature review. J Int Med Res 2023; 51: 3000605221149891.
2. Fallon M, Tadi, P Histology, Schwann Cells. 2023. In StatPearls. Treasure Island (FL): StatPearls Publishing: 2025. PMID: 31335036.
3. Gibbins IL. Peripheral autonomic pathways. In The Human Nervous System, 2nd edn, ed. Paxinos G, Mai JK. Amsterdam, San Diego, London: Elsevier Academic Press, 2004; pp. 134–189.
4. Straus GD, Guckien JL. Schwannoma of the tracheobronchial tree. A case report. Ann Otol Rhinol Laryngol 1951; 60: 242–6.
5. Zhang L, Tang W, Hong QS, Lv PF, Jiang KM, Du R. Case report: A tracheobronchial schwannoma in a child. Respir Med Case Rep 2020; 30: 101047.
6. Liao H, Song W, Chen N, Chen F, Liu C, Lin F. Left lower lobe sleeve resection for endobronchial schwannoma. Ann Transl Med 2019; 7: 50.
7. Lee BR, Choi YD, Kim YI, Lim SC, Kwon YS. Endobronchial schwannoma treated by rigid bronchoscopy with argon plasma coagulation. Tuberc Respir Dis (Seoul) 2012; 73: 174-7.
8. Imen T, Sadok BM, Raoudha A, Ksissa S, Yosra B, Yosr BA et al. Endobronchial schwannoma in adult: A case report. Respir Med Case Rep 2021; 33: 101396.
9. Nishi Y, Handa H, Tsuruoka H, Inoue T, Naruki S, Abe T, Mineshita M. Successful Treatment with Radiation Therapy in an Older Patient with Endobronchial Schwannoma. Case Rep Oncol 2022; 15: 212-7.
10. Grillo HC, Mathisen DJ. Primary tracheal tumors: treatment and results. Ann Thorac Surg 1990; 49: 69-77.

This article is an open access article distributed under the terms and conditions of the Creative Commons Attribution (CC BY) license (http://creativecommons.org/licenses

Current Thoracic Surgery

To cite this article: Arramach I, Harmouchi H, El Amraoui K, Tachaouine M, Lakranbi M, Ouadnouni Y, Smahi M, Maaroufi M. Adult ganglioneuroblastoma of the posterior mediastinum: case report. Curr Thorac Surg 2025;10(2):89-93.

Case Report

Adult ganglioneuroblastoma of the posterior mediastinum: case report

Ikram Arramach[1]*, Hicham Harmouchi[1,2], Khaoula El Amraoui[1], Maha Tachaouine[1], Marouane Lakranbi[1,2], Yassine Ouadnouni[1,2], Mohamed Smahi[1,2], Mustapha Maaroufi[2,3]

[1]Department of Thoracic Surgery, Hassan II University Hospital, Fès, Morocco
[2]Faculty of Medicine, Pharmacy, and Dental Medicine, Sidi Mohamed Ben Abdellah University, Fès, Morocco
[3]Department of Radiology, Hassan II University Hospital, Fès, Morocco

ABSTRACT

Nodular ganglioneuroblastoma is an exceptionally rare neuroblastic neoplasm in the adult population. This report details a highly unusual case of posterior mediastinal ganglioneuroblastoma in a 55-year-old male who presented solely with posterior chest pain. Radiological investigations, including computed tomography and magnetic resonance imaging, demonstrated an encapsulated, highly cellular tumor in the left costovertebral groove at the D7 level, with no evidence of distant metastasis on positron emission tomography. The patient underwent successful surgical resection following preoperative embolization and experienced an uneventful postoperative recovery. Histopathological analysis confirmed the diagnosis of nodular ganglioneuroblastoma. In summary, ganglioneuroblastoma should be considered in the differential diagnosis of posterior mediastinal tumors, even in adult patients.

Keywords: ganglioneuroblastoma, neuroblastic tumor, case report, mediastinal tumor, surgery

Corresponding Author*: Ikram Arramach, MD. Department of Thoracic Surgery, Hassan II University Hospital, Fès, Morocco.
Email: ikramarra@gmail.com
Doi: 10.26663/cts.2025.015
Received 28.04.2025 accepted 08.07.2025

Introduction

Nodular ganglioneuroblastoma (GNB) is a neuroblastic tumor of the sympathetic nervous system that derives from primordial neural crest cells [1]. It is the most common solid tumor in childhood. In the adult population, it is extremely rare, with less than 50 cases have been reported in the English literature [2]. According to the International Neuroblastoma Pathology Classification (INPC), it is defined as a stroma-rich or stroma-dominant tumor (such as ganglioneuroma or intermixed GNB) that contains one or more macroscopic nodules of stroma-poor neuroblastoma [3-5]. We present the clinical course and a review of adult-onset posterior mediastinal nodular ganglioneuroblastoma.

Case Report

A 55-year-old man presented with a chief complaint of posterior chest pain radiating to the sternum. He had a recent history of hypertension and a history of tobacco use, having quit smoking 30 years ago after smoking for 2 years. He was otherwise in good health with no other significant symptoms. His surgical history was unremarkable, and there was no family history of tumors or neuroblastoma.

Chest radiography and computed tomography (CT) revealed a 7 cm heterogeneous posterior mediastinal tumor with contrast enhancement (Figures 1,2). Magnetic resonance imaging (MRI) further demonstrated an encapsulated, highly cellular tumor located in the left costovertebral groove at the level of D7, with a cystic component and intense contrast enhancement. There was no evidence of extension or invasion of the aorta.

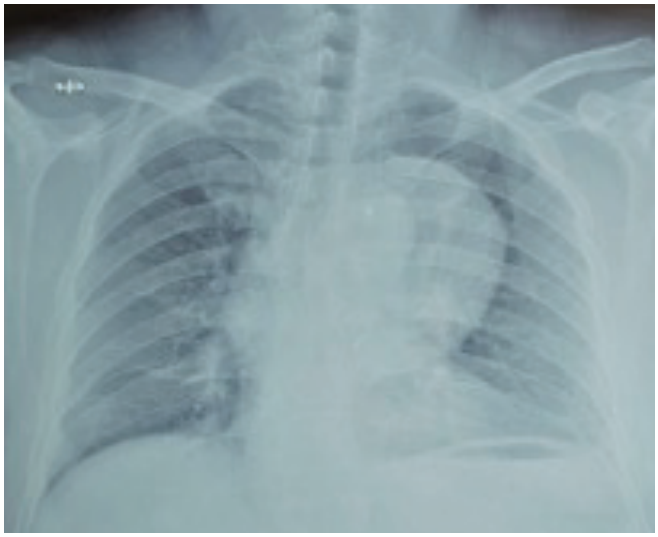

Figure 1. The chest X-ray showing a giant posterior mass on the left side.

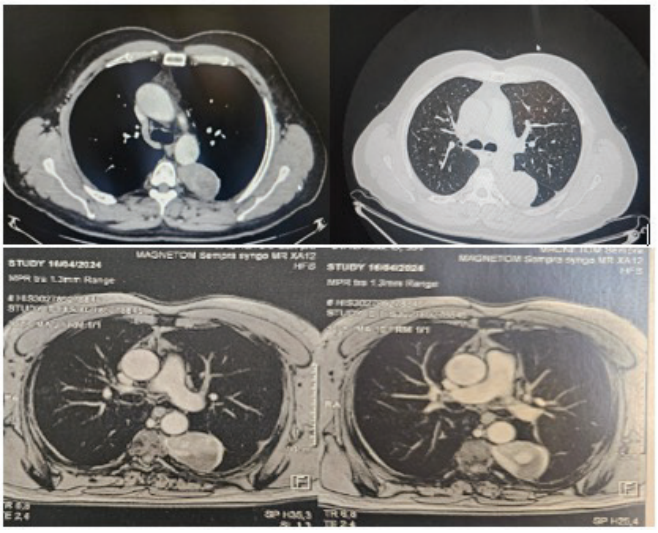

Figure 2. Computed tomography (CT) and magnetic resonance imaging (MRI) revealed a 7 cm heterogeneous, encapsulated, and highly cellular posterior mediastinal tumor located in the left costovertebral groove at the level of D7, with a cystic component and intense contrast enhancement.

After a multidisciplinary discussion, the decision was made to perform laboratory analysis of catecholamine metabolites, PET scan and a preoperative embolization. Laboratory findings showed urine normetadrenaline at 269 nmol/24 h (normal range < 281 nmol/24 h), urine metadrenaline at 59 nmol/24 h (normal range < 159 nmol/24 h), and urine 3-ortho-methyldopa at 1981 nmol/24 h (normal range < 329 nmol/24 h). Positron emission tomography with fluorodeoxyglucose-computed tomography (FDG-PET/CT) revealed positive FDG uptake in the mediastinal mass lesion with areas corresponding to those enhanced on contrast CT (SUVmax: 6.03) (Figure 3). No abnormal FDG uptake was observed in other organs.

The patient underwent angiography and preoperative embolization of the 4th, 6th, and 7th intercostal arteries using coil placement to reduce blood inflow and minimize the risk of recanalization, with identification of the artery of Adamkiewicz originating from the 9th intercostal artery (Figures 4,5). The surgery was done 24 hours later.

The tumor was removed via a conservative thoracotomy approach. The mass was encapsulated and relatively easy to excise, except near the D7 paraspinal region, where dissection was more challenging (Figure 6). There were no perioperative complications, including blood loss or neurological complications. We discharged the patient on the third postoperative day.

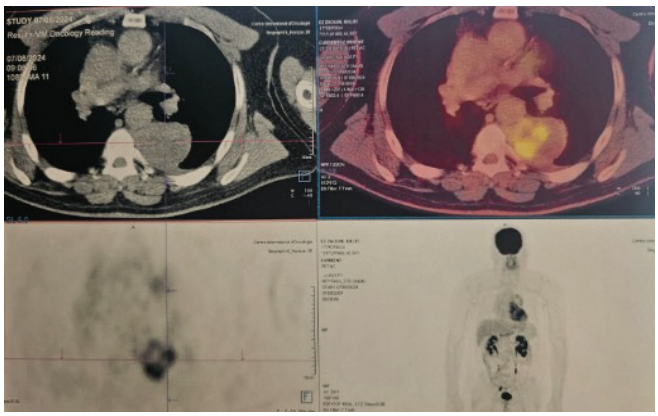

Figure 3. PET/CT showing areas of increased FDG uptake within the tumor (SUVmax: 6.03).

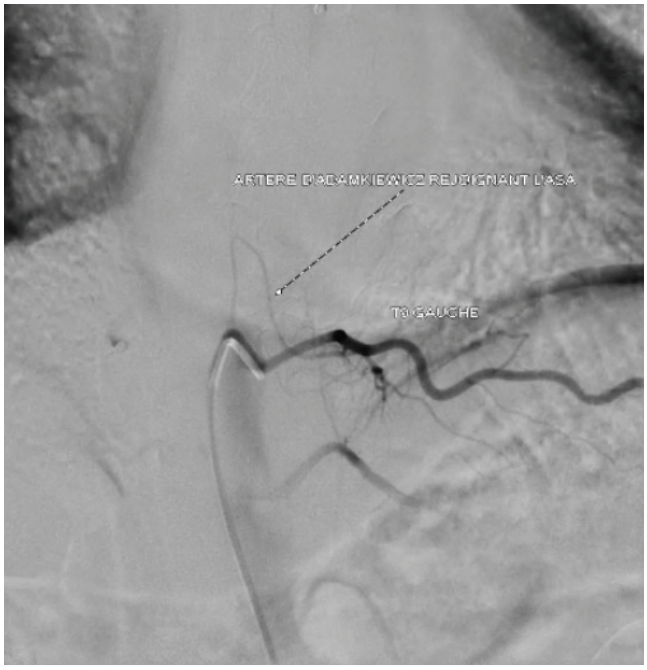

Figure 4. Endovascular treatment; anastomotic network perfusing the mediastinal mass **(A)**, complete embolization of T7 after coil placement **(B)** (Radiology Department, Hassan II University Hospital, Fès).



Figure 5. Identification of the artery of Adamkiewicz originating from the 9th intercostal artery (Radiology Department, Hassan II University Hospital, Fès).

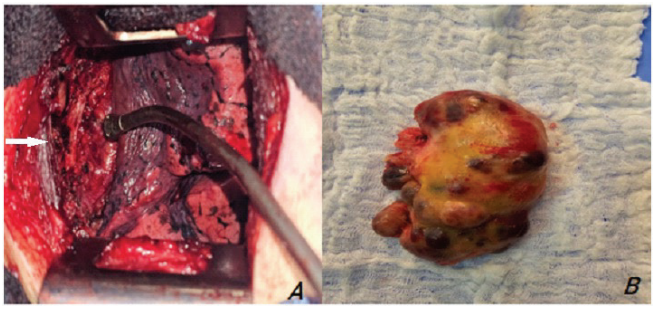

Figure 6. An intraoperative image showing the tumor implantation site (white arrow) **(A)**, the excised left mediastinal-paravertebral mass **(B)**.

The pathological findings of the resected mass contained grossly visible neuroblastomatous nodules including ganglioneuromatous components. Immunohistochemical staining revealed tumor cells positive for chromogranin A, and synaptophysin. Ki-67 labeling index was 30% in the area. The patient underwent a thoraco-abdomino-pelvic CT scan three months after surgery, which returned normal. He is currently under close clinical follow-up (24 months) during which no recurrence or complications have been observed. Written informed consent was obtained from the patient for the use of the medical data in academic studies.

Discussion

Neuroblastic tumors generally occur in very young children, with a median age at diagnosis of 17 months. In adults, these tumors are extremely rare, with an incidence of less than 0.3 cases per million people annually [6-8]. They arise from tissues of the sympathetic nervous system, typically in the adrenal medulla or paraspinal ganglia, and can present as mass lesions in the neck, chest, abdomen, or pelvis [5]. According to the International Neuroblastoma Pathology Classification four types of NTs are distinguished: neuroblastoma, ganglioneuroblastoma-nodular, ganglioneuroblastoma-intermixed, and ganglioneuroma [4-8]. Based on the International Neuroblastoma Risk Group (INRG) analysis, the nodular subtype is associated with a poorer prognosis compared to other neuroblastic pathologies, such as neuroblastoma or the intermixed subtype of GNB [9]. Angelini et al identified two subgroups of patients with a very favorable prognosis: children younger than 547 days and those with non-stage 4 disease. In contrast, patients with stage 4 (distant metastases) nodular ganglioneuroblastoma demonstrated significantly worse outcomes (5-years EFS of 23%, and OS 35%) [10].

The clinical presentation of neuroblastic tumors is highly variable, ranging from an asymptomatic mass to

a primary tumor causing severe illness due to local invasion, widespread metastatic disease, or both. CT and MRI are the most commonly used imaging modalities for evaluating ganglioneuroblastoma. On CT, the appearance of these tumors ranges from well-marginated, oblong paravertebral masses with homogeneous enhancement to irregular, cystic, hemorrhagic, or locally invasive lesions [11,12]. On MRI, ganglioneuroblastoma appears hypointense or isointense on T1-weighted images, and hyperintense with a heterogeneous appearance on T2-weighted images [13]. PET/CT is an additional tool that can aid in diagnosing distant metastasis [12]. Elevated levels of serum neuron-specific enolase (NSE) and urinary catecholamine metabolites are observed in 90% of pediatric neuroblastoma (NB) cases. However, their elevation is rarely observed in adolescents, making them less reliable in this age group [14], which is the case for our patient.

In our experience, preoperative embolization is often recommended to optimize both preoperative and intraoperative conditions during extensive resective surgery. This technique minimizes blood flow to hypervascular tumors by targeting feeder vessels, which facilitates tumor shrinkage and alters its consistency. However, surgery should be performed within 24 hours of embolization. Identifying radiculomedullary arteries (RMAs), such as the artery of Adamkiewicz, is critical to prevent inadvertent embolization of spinal arteries and avoid severe complications [15,16].

Preoperative embolization of large mediastinal tumors with complex blood supplies is a well-established approach. Puma et al. reported three cases of highly vascularized giant thoracic sarcomas treated with preoperative embolization. In all cases, tumor size was reduced, and the resulting perilesional edema facilitated surgical dissection [17,18].

Biopsy can be useful for establishing a preoperative diagnosis [19] however, false-negative results may occur. Ganglioneuroblastomas can look like a neuroblastoma in a partial ganglioneuroma stroma [20].

Early and radical surgery is the best treatment available for mediastinal GNBs [21,22]. In adults, prognosis depends on surgical margin resection. According to Koike et al, adult patients with ganglioneuroblastomas that were only partially resected (R1 or R2) or left unresected had a survival period of less than 24 months [23]. In addition, tumor size at diagnosis may be associated with prognosis in adult GNB. Tumors larger than 8 cm in diameter tend to metastasize to distant organs [24].

There is no established evidence regarding the effectiveness of chemotherapy or radiotherapy in the survival of patients with GNB or neuroblastic tumor. This may be related to the fact that adults have a poorer tolerance to chemotherapy compared to that of children [25]. Further studies are required to confirm these observations.

In conclusion, patients with nodular GNB tumors represent a small subgroup characterized by significant heterogeneity in outcomes, similar to the overall neuroblastoma (NB) population. GNB should be considered a potential posterior mediastinal tumor, even in adult patients. The curative treatment is complete surgical resection; however, careful follow-up is necessary to monitor for metastasis and recurrence.

Declaration of conflicting interests

The authors declared no conflicts of interest with respect to the authorship and/or publication of this article.

Funding

The authors received no financial support.

Author contribution

IA,HH,ML; conceptualization, IA,MT,KEA; data collection and patient management, MM; radiological analysis, IA; writing – original draft, HH,ML; co-writing – review & editing:, MS,YO; supervision. All authors contributed significantly to the drafting and revision of the manuscript and approved the final version.

Acknowledgements

The authors wish to thank the Departments of Radiology and Pathology at Hassan II University Hospital in Fès for their support and collaboration in the management of this case.

References

1. Kilton LJ, Aschenbrener C, Burns CP. Ganglioneuroblastoma in adults. Cancer 1976; 37: 974-83.
2. Sekiguchi N, Noguchi T, Fukushima T, Kobayashi T, Ozawa T, Sato Y et al. Posterior mediastinal ganglioneuroblastoma in an adolescent: A case report and review. Thorac Cancer 2020; 11: 451-5.
3. Peuchmaur M, d'Amore ES, Joshi VV, Hata J, Roald B, Dehner LP et al. Revision of the International Neuroblastoma Pathology Classification: confirmation of favorable and unfavorable prognostic subsets in ganglioneuroblastoma, nodular. Cancer 2003; 98: 2274-81.

4. Shimada H, Ambros IM, Dehner LP, Hata J, Joshi VV, Roald B, Stram DO, Gerbing RB, Lukens JN, Matthay KK, Castleberry RP. The International Neuroblastoma Pathology Classification (the Shimada system). Cancer 1999; 86: 364-72.

5. Shimada H, DeLellis RA, Marx A. Neuroblastic tumours of the adrenal gland. In: Lloyd RV, Osamura RY, Kloppel G, Rosai J, editors. WHO Classification of Tumours of Endocrine Organs. 4th ed. Lyon: IARC Press; 2017:196-203.

6. Choi JH, Ro JY. Mediastinal neuroblastoma, ganglioneuroblastoma, and ganglioneuroma: Pathology review and diagnostic approach. Semin Diagn Pathol 2022; 39: 120-30.

7. Esiashvili N, Goodman M, Ward K, Marcus RB Jr, Johnstone PA. Neuroblastoma in adults: Incidence and survival analysis based on SEER data. Pediatr Blood Cancer 2007; 49: 41-6.

8. Lam AK. Update on Adrenal Tumours in 2017 World Health Organization (WHO) of Endocrine Tumours. Endocr Pathol 2017; 28: 213-27.

9. Monclair T, Brodeur GM, Ambros PF, Brisse HJ, Cecchetto G, Holmes K, et ; INRG Task Force. The International Neuroblastoma Risk Group (INRG) staging system: an INRG Task Force report. J Clin Oncol 2009; 27: 298-303.

10. Angelini P, London WB, Cohn SL, Pearson AD, Matthay KK, Monclair T et. Characteristics and outcome of patients with ganglioneuroblastoma, nodular subtype: a report from the INRG project. Eur J Cancer 2012; 48: 1185-91.

11. Lee JY, Lee KS, Han J, Yoon HK, Kim TS, Han BK et al. Spectrum of neurogenic tumors in the thorax: CT and pathologic findings. J Comput Assist Tomogr 1999; 23: 399-406.

12. Mousa AM, Shokouh-Amiri MH, Shah LM, Garzon S, Xie KL. Adult-onset ganglioneuroblastoma of the posterior mediastinum with osseous metastasis. Radiol Case Rep 2020; 15: 1676-82.

13. Jain N, Halbert J, Patel PA, Biassoni L, Anderson J, Sebire N et al. Importance of Magnetic Resonance Imaging With Diffusion-weighted Imaging in Guiding Biopsy of Nodular Ganglioneuroblastoma: A Case Report. J Pediatr Hematol Oncol 2021; 43: e130-e135.

14. Franks LM, Bollen A, Seeger RC, Stram DO, Matthay KK. Neuroblastoma in adults and adolescents: an indolent course with poor survival. Cancer 1997; 79: 2028-35.

15. Ashour R, Aziz-Sultan A. Preoperative tumor embolization. Neurosurg Clin N Am 2014; 25: 607-7.

16. Chatani S, Haimoto S, Sato Y, Hasegawa T, Murata S, Yamaura H, Inaba Y. Preoperative embolization of spinal metastatic tumor: The use of selective computed tomography angiography for the detection of radiculomedullary arteries. Spine Surg Relat Res 2021; 5: 284-291.

17. Liu FY, Wang MQ, Duan F, Wang ZJ. Combined embolization and surgical resection of a giant mediastinal tumor. Thorac Cardiovasc Surg 2014; 62: 265–269.

18. Puma F, Cardini CL, Passalacqua G, Ragusa M. Preoperative embolization in surgical management of giant thoracic sarcomas. Eur J Cardiothorac Surg 2008; 33: 127-9.

19. Brodeur GM, Pritchard J, Berthold F, Carlsen NL, Castel V, Castelberry RP et al. Revisions of the international criteria for neuroblastoma diagnosis, staging, and response to treatment. J Clin Oncol 1993; 11: 1466-77.

20. Alexander N, Sullivan K, Shaikh F, Irwin MS. Characteristics and management of ganglioneuroma and ganglioneuroblastoma-intermixed in children and adolescents. Pediatr Blood Cancer 2018; 65: e26964.

21. Decarolis B, Simon T, Krug B, Leuschner I, Vokuhl C, Kaatsch et al. Treatment and outcome of Ganglioneuroma and Ganglioneuroblastoma intermixed. BMC Cancer 2016; 16: 542.

22. Fatimi SH, Bawany SA, Ashfaq A. Ganglioneuroblastoma of the posterior mediastinum: A case report. J Med Case Rep. 2011; 5: 322.

23. Koike K, Iihara M, Kanbe M, Omi Y, Aiba M, Obara T. Adult-type ganglioneuroblastoma in the adrenal gland treated by a laparoscopic resection: report of a case. Surg Today 2003; 33: 785-90.

24. Mizuno S, Iida T, Fujita S. Adult-onset adrenal ganglioneuroblastoma - bone metastasis two years after surgery: Report of a case. Surg Today. 2010; 40: 482-6.

25. Matthay KK, Maris JM, Schleiermacher G, Nakagawara A, Mackall CL, Diller L, Weiss WA. Neuroblastoma. Nat Rev Dis Primers 2016; 2: 16078.

This article is an open access article distributed under the terms and conditions of the Creative Commons Attribution (CC BY) license (http://creativecommons.org/licenses/by/4.0/).

To cite this article: Ekici MA, Turan O, Çelik EF, Aydoğdu MH. Massive thoracic cystic schwannoma: a rare case occupying half of the hemithorax. Curr Thorac Surg 2025;10(2):94-97.

Case Report

Massive thoracic cystic schwannoma: a rare case occupying half of the hemithorax

Mehmet Akif Ekici*, Oğuzhan Turan, Enes Fatih Çelik, Muhammet Halil Aydoğdu

Department of Thoracic Surgery, Kayseri Education and Research Hospital, Kayseri, Turkey

ABSTRACT

Schwannomas are slow-growing, encapsulated, benign neoplasms originating from Schwann cells. Although these tumors are frequently asymptomatic, the most commonly reported symptoms include chest pain, back pain, dyspnea, and cough. In this report, we present a case of schwannoma treated surgically at our institution, with particular emphasis on the tumor's size and the uncommon occurrence of cystic presentation.

Keywords: schwannoma, cystic schwannoma, thoracic mass

Corresponding Author*: Mehmet Akif Ekici, MD. Kayseri Şehir Hastanesi, Department of Thoracic Surgery, Şeker Mah. Muhsin Yazıcıoğlu Bulvarı No: 77 Kocasinan, 38080, Kayseri, Turkey.
E-mail: ekicimakif@gmail.com
Doi: 10.26663/cts.2025.016
Received 27.01.2025 accepted 24.06.2025

Introduction

Neurogenic tumors located in the mediastinum originate from embryonic neural crest cells. These tumors are most commonly found in the posterior mediastinum, accounting for 71-95% of cases [1]. They are associated with the sympathetic chain, spinal nerves, or intercostal nerves but can also arise in locations where nerve tissue is present, including intraparenchymal, endotracheal, and chest wall sites [2]. In adults, neurogenic tumors constitute approximately 21% of all mediastinal tumors [3].

Schwannomas, a type of neurogenic tumor, originate from Schwann cells and are slow-growing, encapsulated, benign [4]. Although they are typically asymptomatic, schwannomas may present with compression symptoms depending on their location. The most common symptoms include chest and back pain, shortness of breath, and cough [5]. The gold standard treatment for schwannomas is complete excision. In the majority of cases, resection can be successfully performed using thoracoscopic techniques [6].

Herein, we report a case of schwannoma managed surgically at our institution, with particular emphasis on the tumor's size and the uncommon nature of its cystic presentation.

Case Report

A 37-year-old female patient was admitted to the Department of Thoracic Surgery with the primary complaint of dyspnea. Chest radiography demonstrated increased opacity in the left lower zone with well-circumscribed margins. The preoperative chest radiograph is presented in Figure 1.

Thoracic computed tomography (CT) demonstrated a cystic, well-circumscribed lesion containing a fluid collection measuring up to 10 cm, located between the pleural layers on the left side. The preoperative thoracic CT image is shown in Figure 2.

The patient subsequently underwent exploratory thoracotomy. Intraoperatively, the lesion was identified as extrapleural, exerting compressive effects on the diaphragm and the left lower lobe. The mass, which was suspected to be neurogenic in origin, was excised in its entirety along with its capsule (Figure 3).

Histopathological examination of the resected specimen confirmed the diagnosis of cystic schwannoma. The postoperative course was uneventful, and the patient was discharged on the fourth postoperative day (Figure 4). Follow-up is ongoing with evaluations at three-month intervals. Written informed consent was obtained from the patient for the use of the medical data in academic studies.

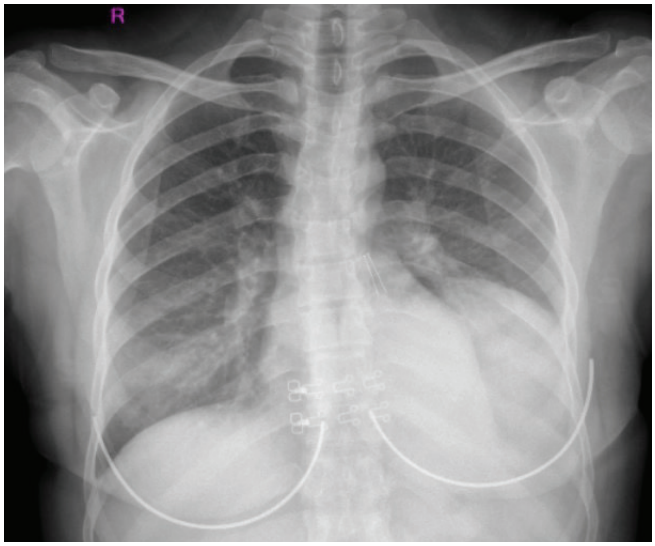

Figure 1. Preoperative chest X-ray.

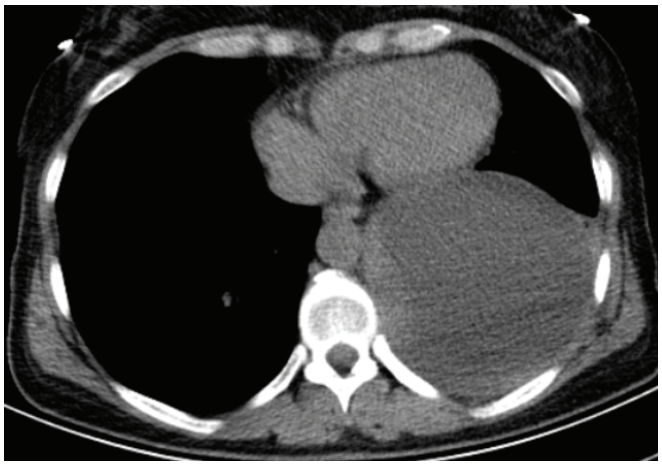

Figure 2. Preoperative thoracic CT image of the lesion.



Figure 3. Intraoperative view of the totally excised cystic lesion.

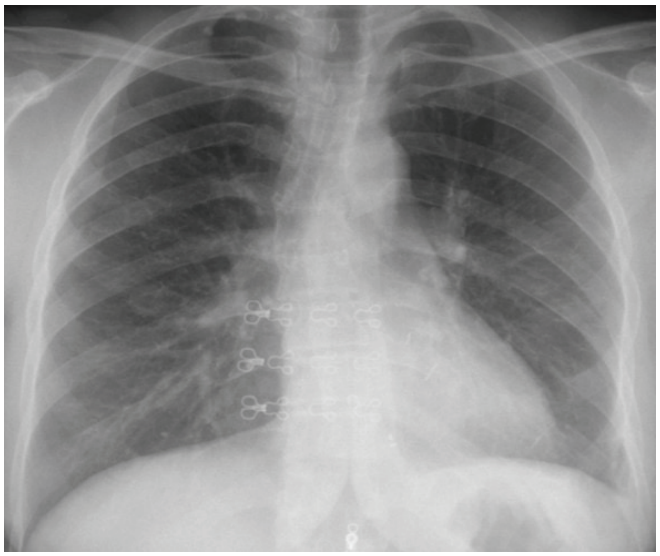

Figure 4. Postoperative chest radiography.

Discussion

Neurogenic tumors located in the mediastinum originate from embryonic neural crest cells. These tumors are most commonly found in the posterior mediastinum, accounting for 71-95% of cases [1]. In adults, neurogenic tumors account for 21% of all mediastinal tumors [3]. Consistent with this, our case involved a neurogenic tumor located in the posterior mediastinum.

Schwannomas typically follow an asymptomatic course. When symptoms occur, they are usually due to compression effects, depending on the tumor's location. The most common symptoms include chest and back pain, shortness of breath, and cough [5]. In this case, our patient presented with shortness of breath.

Cystic schwannomas are exceptionally rare neurogenic tumors [7]. Contrast-enhanced magnetic resonance imaging (MRI) is the preferred imaging modality for evaluating these tumors and is recommended when suspicion arises [8]. However, in our case, thoracic CT imaging was deemed sufficient preoperatively, and an MRI was not performed.

The differential diagnosis of cystic schwannomas includes other mediastinal tumors, infective diseases such as hydatid cysts and tuberculosis, as well as lung cancer [1]. Preoperative radiological imaging methods and intraoperative surgical exploration play an important role in distinguishing cystic schwannomas from other conditions.

Complete surgical excision remains the gold standard treatment method for these tumors. Recurrence after successful excision is exceedingly rare [9]. In our case, the tumor was successfully treated with total excision.

Video-assisted thoracoscopic surgery (VATS) is a safe and effective approach for the removal of mediastinal tumors. In our case, excision was performed via thoracotomy due to the tumor's location and size. However, we also consider VATS exploration to be a clinically appropriate option for mediastinal tumors.

In conclusion, cystic schwannomas are rare entities that pose significant diagnostic challenges in the preoperative setting. Complete surgical excision remains the treatment of choice and is associated with favorable outcomes, as demonstrated in the present case.

Declaration of conflicting interests

The authors declared no conflicts of interest with respect to the authorship and/or publication of this article.

Funding

The authors received no financial support.

Author contribution

MAE,EFÇ; radiological assessment and radiological image arrangement, MAE,OT; surgical assessment and detailed patient information collection, MHA; general consideration of the paper. All authors revised the manuscript. The authors read and approved the final manuscript.

References

1. Boland JM, Colby TV, Folpe AL. Intrathoracic peripheral nerve sheath tumors a clinicopathological study of 75 cases. Human Pathol 2015; 46: 419-25.
2. Kocatürk C. Mediastinal nörojenik tümörler. Toraks Cerrahisi Bulteni. 2011; 2: 106-16.
3. Azarow KS, Pearl RH, Zurcher R, Edwards FH, Cohen AJ. Primary mediastinal masses: a comparison of adult and pediatric populations. J Thorac Cardiovasc Surg 1993; 106: 67-72.
4. Reynolds M, Shields TW. Benign and Malignant Neurogenic tumors of the mediastinum in children and adults. General Thoracic Surgery: Seventh Edition: Wolters Kluwer Health Adis (ESP); 2011. p. 6422-87.

5. Chu EC-P, Trager RJ. Thoracic schwannoma as an unusual cause of sciatic pain in the chiropractic office: a case report. Am J Case Rep 2022; 23: e938448-1.

6. Ishikawa E, Matsumura A, Ishikawa S, Nakamura K, Nose T. Combined minimally invasive approach using microsurgery and thoracoscopic surgery for resecting a dumbbell-type thoracic schwannoma. Minim Invasive Neurosurg 2002; 45: 251-3.

7. Samman A, Bardeesi A, Alzahrani M. Thoracic cystic schwannoma: case report and review of literature. Spinal Cord Ser Cases 2021; 7: 7.

8. Parmar H, Patkar D, Gadani S, Shah J. Cystic lumbar nerve sheath tumours: MRI features in five patients. Australasian Rad 2001; 45: 123-7.

9. Himmiche M, Benzagmout M, Alami B, Benabdellah IS, Chakour K, Chaoui ME. Giant cystic schwannoma of the cauda equina. Ann African Med 2019; 18: 180.

This article is an open access article distributed under the terms and conditions of the Creative Commons Attribution (CC BY) license (http://creativecommons.org/licenses/by/4.0/).

To cite this article: Karaçam V, Karcı E, Mutlu F. Tracheal compression due to straight back syndrome: successful treatment with partial manubrium sterni resection. Curr Thorac Surg 2025;10(2):98-101.

Case Report

Tracheal compression due to straight back syndrome: successful treatment with partial manubrium sterni resection

Volkan Karaçam[1]*, Emrah Karcı[1], Fatma Mutlu[2]

[1]Department of Thoracic Surgery, Dokuz Eylul University Faculty of Medicine, İzmir, Turkey
[2]Department of Thoracic Surgery, Eskisehir City Hospital, Eskişehir, Turkey

ABSTRACT

Straight back syndrome is an uncommon clinical entity characterized by tracheal compression resulting from loss of the normal dorsal curvature of the thoracic vertebrae and a reduced distance between the manubrium and the thoracic vertebrae. Herein, we present a case in which respiratory distress developed secondary to tracheal compression attributable to straight back syndrome, and partial manubrium sterni resection was performed utilizing a minimally invasive technique.

Keywords: straight back syndrome, tracheal stenosis, dyspnea, sternum, tracheal compression

Corresponding Author*: Volkan Karaçam, MD. Department of Thoracic Surgery, Dokuz Eylul University Faculty of Medicine, İnciraltı Mah., Mithatpaşa Cad., No: 1606, Balçova, İzmir, Turkey.
E-mail: volkankaracam@hotmail.com Phone: +90 5326623426
Doi: 10.26663/cts.2025.017
Received 07.04.2025 accepted 24.06.2025

Introduction

The trachea is anatomically situated within the mediastinum, posterior to the sternum. Under normal circumstances, an adequate distance between the trachea and the sternum permits unimpeded tracheal expansion and contraction during respiration. Nevertheless, certain rare chest wall and spinal deformities, traumatic injuries, or malignancies may reduce this distance, resulting in tracheal compression [1,2]. Such compression can lead to airway obstruction and manifest as severe clinical symptoms, including exertional dyspnea, stridor, and, in extreme cases, respiratory failure.

Straight back syndrome (SBS), among these anomalies, is a rare clinical entity characterized by loss of the normal dorsal curvature of the thoracic vertebrae and a decreased distance between the manubrium sterni and the thoracic vertebrae [3,4]. These anatomical alterations may result in cardiac manifestations secondary to compression of the heart and great vessels such as cardiac murmurs, mitral valve insufficiency, and pulmonary hypertension or precipitate respiratory complications due to tracheal compression [5].

Tracheal compression secondary to straight back syndrome (SBS) may significantly impair patients' quality of life. Timely diagnosis and the implementation of appropriate therapeutic interventions are essential for alleviating respiratory symptoms attributable to tracheal compression and for preventing associated complications.

This case report describes a patient who developed respiratory distress as a result of tracheal compression secondary to SBS, and who was managed with partial manubrium resection utilizing a minimally invasive approach.

Case Report

An 18-year-old female patient presented with a two-year history of progressively worsening exertional dyspnea. Her medical history was unremarkable for any known comorbidities. The dyspnea was classified as Grade 1 according to the Modified Medical Research Council (mMRC) Dyspnea Scale. Physical examination revealed no appreciable deformities.

Imaging findings

Thoracic computed tomography (CT) revealed that, distal to the left brachiocephalic artery's origin, the manubrium produced anterior compression of the trachea, thereby decreasing the anteroposterior diameter of the trachea. The minimal anteroposterior diameter was measured at 10 mm, whereas the normative range is 16 to 20 mm. The distance between the posterior cortex of the manubrium and the anterior surface of the vertebral body was 26 mm. The manubrium sterni measured 18 mm in thickness and 60 mm in width (Figures 1,2).

Preoperative evaluation

Fiberoptic bronchoscopy revealed compressive narrowing of the anterior wall starting 2 cm after the tracheal inlet. However, no tracheomalacia was detected.

Surgical method

With the patient in the supine position, a 3 cm incision was performed on the manubrium, commencing at the incisura jugularis. The segment of the manubrium exerting compression on the trachea was excised utilizing a V-shaped wedge resection technique (Figure 3). This intervention alleviated tracheal compression, and the resultant defect was reinforced with a titanium plate. The procedure was concluded upon achieving hemostasis.

Postoperative course

The patient was extubated postoperatively and mobilized two hours postoperatively. Marked improvement in respiratory function was observed promptly.

At the six-month follow-up, computed tomography demonstrated resolution of tracheal compression, with a tracheal diameter of 15.2 mm and a manubrium-to-vertebral distance of 46–47 mm (Figure 4). Written informed consent was obtained from the patient for the use of medical data in academic research.

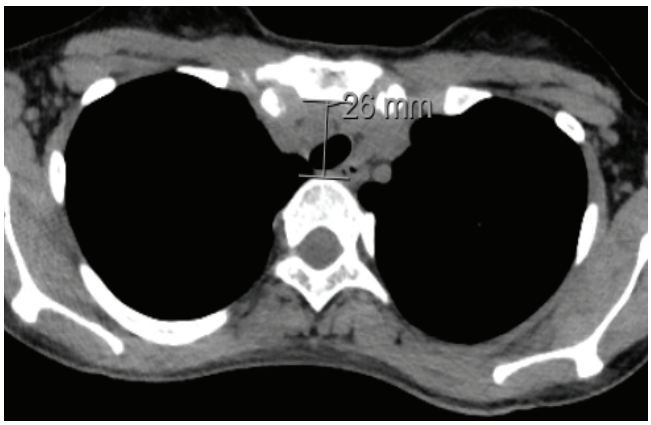

Figure 1. Measurement of the minimal distance between the posterior aspect of the manubrium and the anterior surface of the vertebral body on the axial section of the patient's preoperative thoracic computed tomography (CT) scan.

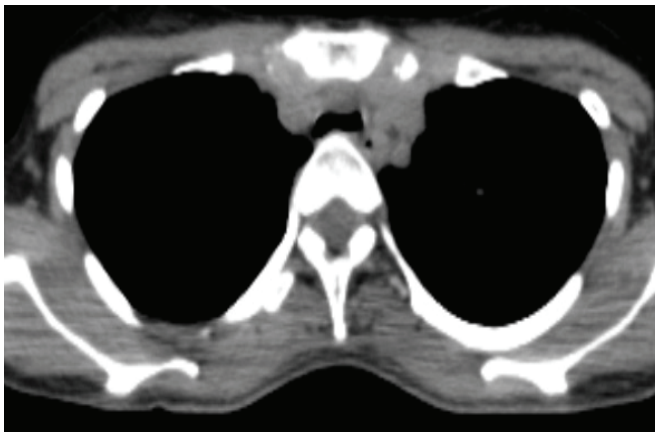

Figure 2. The shortest anterior and posterior diameter of the trachea in the axial section of the thorax CT.



Figure 3. Operative appearance demonstrating compression of the trachea by the manubrium sterni following V-shaped wedge resection.

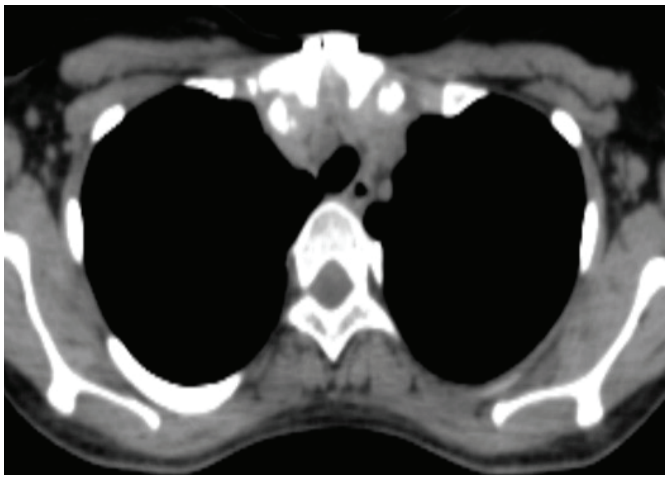

Figure 4. The shortest distance between the posterior manubrium and the anterior vertebra in the axial section of the patient's 6th-month postoperative thorax CT.

Discussion

In cases of tracheal compression secondary to straight back syndrome (SBS), the primary objective is to achieve adequate decompression by creating sufficient mediastinal space. Surgical interventions may include resection of the posterior manubrium, sternoplasty, correction of concomitant pectus excavatum, or displacement and reconstruction of major vessels contributing to the compression, in order to optimize the available space within the upper mediastinum [5].

In a study conducted by Grillo et al, four patients presenting with tracheal compression secondary to SBS were evaluated. Two patients underwent partial manubrial resection in conjunction with re-transposition of the brachiocephalic artery, which was rerouted from the aorta to the right side of the trachea utilizing a graft. Another patient received pectus repair via a modified Ravitch procedure. The remaining patient was managed by placement of a methylmethacrylate plate to preserve the distance between the sternoclavicular joints following partial manubrial resection [6].

Liu et al. reported a case of SBS with tracheal stenosis in which resection of the sternum, costal cartilage, and thymic tissue was undertaken. The resultant chest wall defect was reconstructed, and tracheal compression was alleviated through the application of digitally fabricated material utilizing three-dimensional (3D) technology [7]. In the present case, tracheal compression was similarly attributable to a reduced distance (26 mm) between the posterior aspect of the manubrium and the vertebral bodies. The observation of an abnormally increased transverse diameter of the manubrium indicated that symptomatic relief could be achieved via a less invasive approach, thereby preserving chest wall integrity and avoiding disruption of the sternoclavicular joints. Accordingly, a V-shaped wedge resection of the manubrium was performed. Postoperatively, tracheal compression was effectively resolved. Follow-up computed tomography performed at six months demonstrated an increase in the distance between the posterior surface of the manubrium and the anterior surface of the vertebral bodies to 46-47 mm, as well as an increase in the tracheal anteroposterior diameter to 15.2 mm.

In conclusion, in patients presenting with a decreased anteroposterior thoracic diameter and an increased transverse diameter, tracheal compression should be included in the differential diagnosis of exertional dys-

pnea. Following early diagnosis and appropriate surgical intervention, significant improvement in respiratory function and quality of life may be achieved. In the present case, tracheal compression was effectively alleviated through a V-shaped wedge resection of the manubrium, utilizing a minimally invasive technique that preserved both patient posture and chest wall integrity. This approach may optimize surgical outcomes and contribute to favorable long-term prognoses.

Declaration of conflicting interests

The authors declared no conflicts of interest with respect to the authorship and/or publication of this article.

Funding

The authors received no financial support.

Authors' contribution

VK; organized the article and wrote the paper, EK,FM; contributed to the data collection, VK,EK,FM; revised the article. All authors revised the manuscript. The authors read and approved the final manuscript.

References

1. Mi X. Applied Anatomy and Physiology of Trachea, Bronchus and Esophagus. In: Mu, Z., Fang, J. (eds) Practical Otorhinolaryngology - Head and Neck Surgery. Springer, Singapore, 2021.
2. Winter RB, Lovell WW, Moe JH. Excessive thoracic lordosis and loss of pulmonary function in patients with idiopathic scoliosis. J Bone Joint Surg Am 1975; 57: 972-7.
3. Davies MK, Mackintosh P, Cayton RM, Page AJ, Shiu MF, Littler WA. The straight back syndrome. Q J Med 1980; 49: 443-60.
4. Okorozo A, Chiang V, Kim HS, Vimolratana M, Sadoughi A. A rare case of straight-back syndrome causing airway obstruction. Respir Med Case Rep 2024; 50: 102024.
5. Schmid S, Schibilsky D, Kalbhenn J, Hassan M, Loop T, Passlick B et al. Reconstruction of the Mediastinum and Tracheopexy for Tracheomalacia in Straight Back Syndrome. Ann Thorac Surg 2021; 112: e41-e44.
6. Grillo HC, Wright CD, Dartevelle PG, Wain JC, Murakami S. Tracheal compression caused by straight back syndrome, chest wall deformity, and anterior spinal displacement: techniques for relief. Ann Thorac Surg 2005; 80: 2057-62.
7. Liu Y, Wang W, Long W, Cai B, Chen C, Wang W et al. Chest wall reconstruction with digitally designed materials for straight back syndrome with tracheal stenosis: a case report. Ann Transl Med 2021; 9: 1357.

This article is an open access article distributed under the terms and conditions of the Creative Commons Attribution (CC BY) license (http://creativecommons.org/licenses/by/4.0/).