Volume 10 Number 3 December 2025 eISSN 2548-0316

CURRENT THORACIC SURGERY

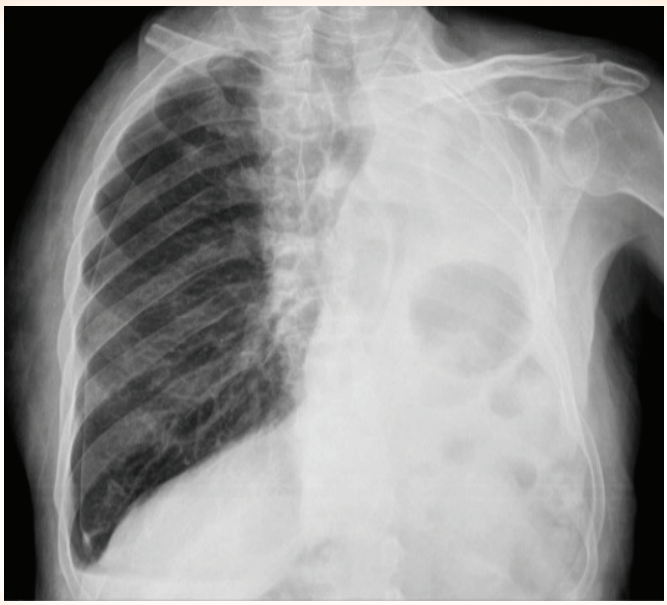

Official e-journal of the Turkish Society of Thoracic Surgery CTS

When you cite this journal, use the following abbreviation

Curr Thorac Surg

There is no article processing charges or submission fees for any submitted articles. All expenses of the journal are covered by Turkish Society of Thoracic Surgery

Table of Contents

Volume 10 Number 3 December 2025 eISSN 2548-0316

Original Articles

102 **Assessment of predictive factors for complicated hemothorax following blunt chest trauma in a tertiary care centre: a retrospective cohort study**
Monisha G, Manikanta K

108 **Evaluation of artificial intelligence chatbots in postoperative thoracic surgery education: comparative analysis of content quality and readability**
Nilay Çavuşoğlu Yalçın, Okan Karataş, Muharrem Özkaya

114 **Intercostal nerve reconstruction for compensatory hyperhidrosis: clinical outcomes of the "Gebitekin technique"**
Gamze Tanrıkulu, Hüseyin Melek, Tolga Evrim Sevinç, Erhan Özer, Eylem Yentürk, Ahmet Sami Bayram, Cengiz Gebitekin

124 **Talc pleurodesis for hepatic pleural effusions: clinical outcomes following serum albumin optimization**
Muhammad Shoaib Nabi, Zeeshan Sarwar

131 **Impact of preoperative pulmonary rehabilitation on postoperative outcomes in patients undergoing lung cancer surgery**
Merve Ezgi Unal, Tevfik İlker Akcam, Funda Elmas Uysal, Ayse Gul Ergonul, Ali Ozdil, Kutsal Turhan, Alev Gurgun, Melike Ülker, Alpaslan Cakan, Ufuk Cagirici

139 **Survival outcomes and prognostic factors in salvage surgery for advanced non-small cell lung cancer: a 10-year single-center experience**
Ozgur Ozturk, Kenan Can Ceylan, Onur Akcay, Seyda Ors Kaya, Ahmet Ucvet, Soner Gursoy, Aysen Evkan Ozturk, Ozgur Samancilar

147 **Evaluation of thoracic injuries resulting from two major earthquakes in Turkey**
Atilla Can, Halil Şen, Muhammet Ali Tiske, Tuba Şahinoğlu, Hüseyin Yıldıran

154 **Prognostic value of the geriatric nutritional risk index in elderly patients undergoing surgery for early-stage non-small cell lung cancer**
Esra Yamansavci Sirzai, Gizem Ozcibik Isik, Ufuk Cicek, Dilekhan Kizir, Yunus Turk, Celal Bugra Sezen, Ozkan Saydam, Ahmet Ucvet

Case Reports

160 **Heterotopic supradiaphragmatic liver tissue mimicking a thoracic tumor: a diagnostic dilemma and VATS management**
Hasan Yavuz, Fatih Yılmaz, Fulden Haşimoğlu

163 **Treatment of contralateral pneumothorax due to metastasis in a left pneumonectomy patient with single-port VATS**
Selime Kahraman, Attila Ozdemir, Saliha Bayraktar, Recep Demirhan

166 **Pleural capillary hemangioma mimicking traumatic hematoma: a rare case of massive hemorrhagic effusion**
Caner İşevi, Mehmet Gökhan Pirzirenli, Feyza Bahar Doğan, Yurdanur Süllü, Burçin Çelik

170 **Bronchobiliary fistula causing gallstone formation in lung parenchyma: a rare case report**
Mustafa Kazar, Tibet Uğur Kurak, Fatma Bağrıaaçık Ekinci, Mehmet Oğuz Köksel

175 **Fibro-osseous lesion of the 11th rib mimicking malignancy: a rare thoracic chest wall tumor**
Muhammad Shoaib Nabi, Zeeshan Sarwar, Khalid Farooq

179 **Giant lung bulla extending to the contralateral hemithorax**
Damla Hasgül, Nurefşan Okyay, Tibet Uğur Kurak, Erhan Ayan

184 **A rare complication of hydrophilic gel filler: intrathoracic migration**
Attila Özdemir, Selime Kahraman, Saliha Bayraktar, Recep Demirhan

Letter to the Editor

187 **Can the thoracic surgery internship and the right learning outcome be a solution to the recognition and problems of thoracic surgery?**
Rasih Yazkan

Editor's Comment

191 **The pivotal role of standardized internship in the future of thoracic surgery**
Berkant Özpolat

To cite this article: Monisha G, Manikanta KS. Assessment of predictive factors for complicated hemothorax following blunt chest trauma in a tertiary care centre: a retrospective cohort study. Curr Thorac Surg 2025;10(3):102-107.

Original Article

Assessment of predictive factors for complicated hemothorax following blunt chest trauma in a tertiary care centre: a retrospective cohort study

Monisha G[1]*, Manikanta KS[2]

[1]Department of Cardiothoracic and Vascular Surgery, Bangalore Medical College and Research Institute, Bangalore, India
[2]Department of General Surgery, Bangalore Medical College and Research Institute, Bangalore, India

ABSTRACT

Background: Hemothorax is a common consequence of blunt chest trauma. A subset progresses to complicated hemothorax requiring repeat procedures. This study aimed to identify predictors of complicated hemothorax.

Materials and Methods: A retrospective cohort study was conducted, including 60 patients with blunt chest trauma and hemothorax managed at a tertiary care center. Patients were grouped into uncomplicated (n = 30) and complicated hemothorax (n = 30, requiring additional procedures). Logistic regression was performed to identify predictors.

Results: On univariate analysis, delay in ICD placement >3 days (OR 5.09, p = 0.015) and loculated/septated collections (OR 21.1, p < 0.001) were associated with complicated hemothorax. In multivariable analysis, only loculated/septated collections remained an independent predictor (adjusted OR 26.5, p = 0.006).

Conclusions: Loculated collections are the strongest predictor of complicated hemothorax. Early identification of septated/loculated collections on imaging should prompt timely surgical referral, preferably VATS, to reduce morbidity and minimize repeat procedures. In delayed-presentation trauma with loculated collections or comorbidities, early surgical intervention should be considered as simple chest drainage is often insufficient.

Keywords: hemothorax, blunt chest trauma, video-assisted thoracoscopic surgery, empyema, chest tubes

Corresponding Author*: Monisha G, MD. Department of Cardiothoracic and Vascular Surgery, Bangalore Medical College and Research Institute, Fort Road, K.R. Market, Bangalore, 560002, Karnataka, India.
Email: gmonishachmc@gmail.com Phone: +91 9884398671
Doi: 10.26663/cts.2025.019
Received 15.09.2025 accepted 12.11.2025

Introduction

Blunt chest trauma is a significant cause of morbidity and mortality worldwide, with reported mortality rates ranging from 4% to 20% [1,2]. While serious, life-threatening thoracic injuries are often detected early through clinical and radiological evaluation and managed promptly with drainage procedures, less obvious injuries, especially those without significant hemothorax on initial imaging, may present later with worsening symptoms such as chest pain and breathlessness. These delayed presentations can lead to serious complications, including clotted hemothorax and empyema, which increase hospital stay and overall morbidity.

Several studies have suggested that factors such as multiple rib fractures [3], high Injury Severity Score (ISS), and inadequate initial chest drainage may contribute to the development of complicated hemothorax. However, evidence on consistent and reliable predictors remains limited and inconclusive, especially in resource-constrained settings. Moreover, variability in the timing and type of interventions, such as early video-assisted thoracoscopic surgery (VATS) versus repeat intercostal drainage (ICD), further complicates the clinical management of these patients. Previous researches have also been limited by methodological issues, including retrospective designs, single-center data, and lack of standardized radiological criteria for diagnosing retained or complicated hemothorax [4].

Complicated hemothorax significantly contributes to prolonged hospitalization, increased healthcare costs, and higher rates of morbidity. Patients with retained or infected hemothorax often require additional interventions, such as repeat drainage or surgical procedures, which can delay recovery and increase the risk of complications like empyema and fibrothorax. These factors not only impact patient quality of life but also place a considerable burden on healthcare resources, emphasizing the importance of early identification and management of at-risk patients [5].

Given the impact of complicated hemothorax on patient outcomes and healthcare resources, identifying early risk factors is essential to guide timely and targeted interventions. This study aims to fill this gap by retrospectively assessing clinical, radiological, and procedural predictors of complicated hemothorax following blunt chest trauma in a tertiary care setting. This study aims to identify early radiological and procedural predictors of complicated hemothorax and guide timely surgical decision-making.

In this report we aimed to identify clinical, radiological, and procedural predictors of delayed, retained, or infected hemothorax following blunt chest trauma in a tertiary care center. Primary endpoint: Identification of predictors for complicated hemothorax requiring additional intervention.

Materials and Methods

This is a retrospective cohort study performed at BMCRI Trauma and Emergency Care Centre between November 2024 and June 2025. The study will include patients with blunt chest trauma who underwent intercostal chest drain (ICD) insertion for hemothorax. Patient data will be collected through: history and clinical evaluation including physical examination and assessment of air entry, and radiological assessment including Chest X-ray, ultrasound of the thorax (USG Thorax), and High-Resolution CT (HRCT) Thorax. Loculated/septated collections were defined as non-homogeneous pleural fluid with internal septations or membranes on USG or CT. Representative CT and ultrasound images demonstrating loculated/septated collections have been included.

Documentation of associated injuries and nature of trauma was done, and the details related to drainage procedures, including: time interval between injury and ICD placement, need for additional interventions such as repeated ICD insertion, therapeutic tapping, and Video-Assisted Thoracoscopic Surgery (VATS).

The inclusion criteria is, patients >18 years, blunt chest trauma, hemodynamically stability, who underwent ICD insertion, and exclusion criteria is immediate intubation/mechanical ventilation on admission, mild hemothorax (<300 mL), mild pneumothorax (<15% collapse) and conservatively managed cases.

Patients were categorized into two groups as the ones managed with a primary ICD only and the ones required further intervention.

Delayed hemothorax is defined as that which develops >24 h after negative initial imaging. Retained hemothorax as persistent pleural blood after 72 h of drainage or ≥500 mL unresolved. Infected hemothorax (empyema) is pus within the pleural space due to infected retained blood. Complicated hemothorax as where an additional intervention was required within 14 days post-trauma or during the same admission.

Duration of hospital stay, adequate lung expansion, and duration of oxygen requirement is also assesed. The study was approved by the Ethics Committee of Bangalore Medical College and Research Institute (25.07.2025, BMCRI/EC/24/25).

Statistical Analysis

Data were tested for normality and analyzed using SPSS version 28.0. Continuous variables were expressed as mean (range), while categorical data were summarized as frequency (%). Group comparisons were performed using chi-square or Fisher's exact test as appropriate. Variables with $p < 0.1$ on univariate analysis were entered into a multivariable logistic regression model to identify independent predictors. Results are presented as odds ratios (OR) with 95% confidence intervals (CI). A p-value < 0.05 was considered statistically significant.

Results

A total of 60 patients with blunt chest trauma and hemothorax were included, with 30 developing complicated hemothorax and 30 successfully managed with primary chest tube drainage. The mean ages were comparable between the two groups (55 years vs 52 years, $p = 0.59$). Male predominance was observed in both groups (83%) (Table 1).

A delay in chest tube insertion beyond three days was significantly higher in the complicated group compared to the primary drainage group (83% vs 7%, $p < 0.001$). Loculated or septated pleural collections were present in 70% of complicated cases but absent in the primary group ($p < 0.001$). Delay in ICD insertion >3 days and loculated/ septated collections were significant predictors of complication. On multivariate analysis, only loculated/ septated collections remained independent predictor (adjusted OR 26.5, $p = 0.006$).

Comorbidities such as diabetes mellitus and prior pulmonary tuberculosis were more common in the complicated group (10% vs 0%), though this difference did not reach statistical significance ($p = 0.11$).

Radiological findings demonstrated that moderate to gross free pleural fluid was more frequent in the primary group (73% vs 40%, $p = 0.018$), while pneumothorax or hemopneumothorax was significantly higher in the primary group (63% vs 7%, $p < 0.001$) (Table 2). Hemopneumothorax was considered an initial presentation, not a complication during follow-up.

All patients in the primary drainage group were managed successfully with a single chest tube. In contrast, 68% of patients in the complicated group required secondary interventions, including repeat drainage, therapeutic tapping, or video-assisted thoracoscopic surgery (VATS) (Table 3). Logistic regression analysis was shown in table 4.

Table 1. Baseline characteristics of patients with complicated hemothorax versus the primary ICD group.

Variable	Complicated hemothorax (n = 30)	Primary ICD (n = 30)	p
Mean age (years)	55 (26–90)	52 (20–85)	0.59 (NS)
Male sex (%)	25 (83%)	25 (83%)	1.00 (NS)
Delay > 3 days (%)	25 (83%)	2 (7%)	<0.001
Comorbidities (%)	3 (10%)	0 (0%)	0.11 (NS)

Table 2. Radiological findings in complicated versus the primary ICD groups.

Imaging feature	Complicated hemothorax (n = 30)	Primary ICD (n = 30)	p
Loculated/septated	21 (70%)	0 (0%)	<0.001
Moderate–gross free fluid	12 (40%)	22 (73%)	0.018
Massive/white-out lung	2 (7%)	1 (3%)	0.55 (NS)
Pneumothorax/ hemopneumothorax	2 (7%)	19 (63%)	<0.001

Table 3. Outcomes of complicated versus the primary ICD groups.

Outcome	Complicated hemothorax (n = 30)	Primary ICD (n = 30)	p
Managed with ICD alone	10 (33%)	30 (100%)	<0.0001
Required VATS/ decortication/ lavage	11 (37%)	0 (0%)	<0.0001
Required tapping/ reinsertion	9 (30%)	0 (0%)	<0.0001

Table 4. Logistic regression analysis.				
Predictor	Univariate OR (95% CI)	p	Multivariable OR (95% CI)	p
Delay > 3 days	5.09 (1.38–18.8)	0.015	0.72 (0.08–6.95)	0.78
Loculated/septated	21.1 (3.92–113.6)	<0.001	26.5 (2.54–276.4)	0.006
Age (years)	1.02 (0.98–1.05)	0.39	–	–
Mode of injury (RTA vs other)	1.36 (0.45–4.06)	0.58	–	–
On univariate analysis, both delay in ICD insertion beyond 3 days (OR 5.09, 95% CI 1.38–18.8, p = 0.015) and the presence of loculated/ septated collections (OR 21.1, 95% CI 3.9–113.6, p < 0.001) were significantly associated with complicated hemothorax. Age and mode of injury were not significant predictors. *In the multivariable model including both delay and loculated collections, loculated/septated collections remained a strong independent predictor (adjusted OR 26.5, 95% CI 2.54–276.4, p = 0.006), whereas the effect of delay >3 days was attenuated (OR 0.72, 95% CI 0.08–6.95, p = 0.78).*				

These findings suggest that while delayed drainage is important, the presence of organized/ loculated collections is the dominant factor driving progression to complicated hemothorax in this cohort.

Discussion

This study demonstrated that delayed ICD insertion (>3 days) and loculated/septated pleural collections were strongly predictive of complicated hemothorax. These findings are consistent with published literature emphasizing that early drainage prevents clot organization and empyema. Comorbidities such as diabetes and prior pulmonary tuberculosis were more frequent among complicated cases, though this did not reach statistical significance, likely due to the limited sample size. Nevertheless, such comorbidities are known to impair pleural healing and increase infection risk. Outcomes analysis showed that all patients in the primary ICD group resolved with a single chest tube, whereas two-thirds of complicated cases required secondary interventions (VATS, lavage, or reinsertion). This aligns with previous studies recommending early surgical referral when retained collections are detected.

Historical and contemporary evidence supports our findings. Churchill et al [6] has advocated early decortication in post-traumatic empyema, emphasizing timely intervention. And Villalba et al [7] had reported delayed diagnosis and inadequate drainage as major contributors to empyema. French et al [8] also showed that limited thoracotomy with enzymatic therapy improved outcomes in early clotted hemothorax. DuBose et al [9] had found that retained hemothorax significantly increased empyema risk, with predictors including rib fractures and high ISS. Navsaria et al [10] also demonstrated that early thoracoscopic evacuation and fibrinolytic therapy reduced complications. The latest supportive evidences have been summarized in the table 5.

Table 5. Summary of recent literature on the predictors and management of complicated hemothorax.		
Study	Key Predictors / Factors	Main Findings / Outcomes
Sharma et al [11]	Delayed ICD, associated abdominal injuries, bilateral hemothorax	Predicted complicated outcomes
Ahmed et al [12]	Early vs delayed VATS (<72 h)	Early VATS reduced empyema rates and ICU stay
Lee et al [13]	Delay >48 h, multiple rib fractures, posterior collections	Predicted need for surgical evacuation
Berardi et al [4]	Septated collections	Strong independent predictor of complicated hemothorax
Aydin et al [5]	Septated collections	Strong independent predictor of complicated hemothorax
Kumar et al [14]	Early VATS (within 72 h)	Significantly reduced complications

In our cohort, loculated/septated collections emerged as the strongest independent predictor of complicated hemothorax, consistent with the pathophysiology of organized clot formation leading to impaired drainage and subsequent infection. While delay in drainage beyond 3 days showed significance on univariate analysis, its effect was attenuated after adjustment, suggesting that delay contributes indirectly by predisposing to loculation. These findings are in line with previous reports that emphasize timely drainage and the early use of VATS in patients with evidence of septations or loculations to prevent progression.

In Indian settings, studies from AIIMS [15] New Delhi and Jodhpur have similarly shown that about 25-30% of hemothorax patients fail initial chest tube drainage, and outcomes are significantly better when VATS is used within 3-7 days of trauma, with shorter hospital stays and fewer additional procedures. Another study from North India[15] found that residual hemothorax identified 48-72 hours post-tube drainage was common, and that tube positioning and early recognition are key to preventing progression.

Clinical implications suggest that early intercostal drainage (ICD) within the first 24 hours has a protective effect and contributes to improved outcomes. In patients presenting with loculated pleural collections or those who arrive later in the disease course, early video-assisted thoracoscopic surgery (VATS) should be prioritized over repeat ICD attempts. This approach can reduce hospital stay and may help prevent the development of empyema by providing more effective and definitive source control.

Limitations of the study

This was a retrospective, single-centre study with a modest sample size. Long-term outcomes, such as pulmonary function and quality of life, were not assessed. Despite these limitations, the study provides useful insights into the risk stratification and management of complicated hemothorax.

In conclusion, delayed chest tube placement and the presence of loculated pleural collections are strong predictors of complicated hemothorax following blunt chest trauma. Comorbidities such as diabetes and prior pulmonary tuberculosis, although not statistically significant, may contribute to poorer outcomes. Early and adequate drainage within 24 hours of injury remains the most effective strategy to prevent retained hemothorax and its complications. When collections persist, timely escalation to surgical management, particularly video-assisted thoracoscopic surgery, can reduce morbidity and the need for multiple procedures. Delayed drainage and loculated pleural collections predict complicated hemothorax. Loculated collections are the dominant independent predictor. Early recognition and prompt surgical referral can improve outcomes.

Declaration of conflicting interests

The authors declared no conflicts of interest with respect to the authorship and/or publication of this article.

Funding

The authors received no financial support for the research and/or authorship of this article.

Ethics approval

This study was approved by the Ethics Committee of Bangalore Medical College and Research Institute (25.07.2025, BMCRI/EC/24/25), and conducted in accordance with the Declaration of Helsinki.

Authors' contribution

MG: Conceptualization, Methodology, Writing - original draft. MKS: Data curation, Formal analysis, Writing - review & editing.

References

1. Ziegler DW, Agarwal NN. The morbidity and mortality of rib fractures. J Trauma 1994; 37: 975-9.
2. Quaday KA. Morbidity and mortality of rib fracture. J Trauma 1995; 39: 617.
3. Chen J, Liu H, Zhang H, Zhao L, Chen Y. Risk factors of hemothorax after rib fracture. Chin J Traumatol 2021; 24: 309-15.
4. Berardi G, Citterio D, Mariani NM, Baisi A, Fumagalli R, Rebuffat C et al. Risk factors for retained hemothorax after trauma: a 10-year monocentric experience from a thoracic surgery referral trauma hub. J Clin Med 2022; 11: 6110.
5. Aydın S, Kahraman Aydın S, Gülmez B, Güneş SG, Kavurmacı Ö, Dadaş ÖF. Rib fracture characteristics increasing the risk of hemothorax: a multicenter study. Sci Rep 2024; 14: 29827.

6. Churchill ED, Belsey R. Early pulmonary decortication in the treatment of post-traumatic empyema. Surgery 1945; 18: 822-30.

7. Villalba M, Lucas CE, Ledgerwood AM, Asfaw I. The etiology of posttraumatic empyema and the role of decortication. J Trauma 1979; 19: 414-21.

8. French SW, Rumer GF. Limited thoracotomy and enzymatic therapy in the treatment of early clotted hemothorax. US Armed Forces Med J 1958; 9: 949-56.

9. DuBose J, Inaba K, Okoye O, Demetriades D, Scalea TM, O'Connor J et al. Development of posttraumatic empyema in patients with retained hemothorax: results of a prospective, observational AAST study. J Trauma Acute Care Surg 2012; 73: 752-7.

10. Navsaria PH, Vogel RJ, Nicol AJ. Thoracoscopic evacuation of retained posttraumatic hemothorax. Ann Thorac Surg 2004; 78: 282-5.

11. Sharma R, Mehta N, Singh K, Bansal R, Verma GR. Predictive factors for retained and complicated hemothorax in blunt chest trauma: a retrospective analysis at a tertiary care hospital in India. Int Surg J 2021; 8: 1521-6.

12. Ahmed N, Wahla AS, Malik SH, Khan M, Yousuf MA. Early versus delayed video-assisted thoracoscopic surgery in the management of retained post-traumatic hemothorax: a prospective comparative study. J Thorac Dis 2020; 12: 2958-66.

13. Lee YJ, Kim YH, Park JH, Moon SW, Kim DH. Predictors of clotted hemothorax in blunt chest trauma: a multicenter retrospective cohort study. J Thorac Cardiovasc Surg 2018; 155: 672-8.

14. Kumar A, Gora D, Bagaria D, Priyadarshini P, Choudhary N, Priyadarshi A, et al. Outcomes of video-assisted thoracic surgery-guided early evacuation of traumatic hemothorax: a randomized pilot study at Level I trauma center. J Emerg Trauma Shock 2024; 17: 73-9.

15. Kumar S, Agarwal N, Rattan A, Rathi V. Does intrapleural length and position of the intercostal drain affect the frequency of residual hemothorax? A prospective study from North India. J Emerg Trauma Shock 2014; 7: 274-9.

This article is an open access article distributed under the terms and conditions of the Creative Commons Attribution (CC BY) license (http://creativecommons.org/licenses/by/4.0/

To cite this article: Çavuşoğlu Yalçın N, Karataş O, Özkaya M. Evaluation of artificial intelligence chatbots in postoperative thoracic surgery education: comparative analysis of content quality and readability. Curr Thorac Surg 2025;10(3):108-113.

Original Article

Evaluation of artificial intelligence chatbots in postoperative thoracic surgery education: comparative analysis of content quality and readability

Nilay Çavuşoğlu Yalçın, Okan Karataş*, Muharrem Özkaya

Department of Thoracic Surgery, University of Health Sciences, Antalya Training and Research Hospital, Antalya, Türkiye

ABSTRACT

Background: To evaluate the scientific accuracy, informational quality, and readability of artificial intelligence (AI) chatbots in providing postoperative education after thoracic surgery.

Materials and Methods: Five publicly available chatbots, GPT-5o, GPT-4o, GPT-4.1, Claude Opus-4, and Gemini Pro were tested using a standardized prompt on postoperative care after lung resection. Each Chatbot's response was independently assessed by a thoracic surgeon using two validated scoring systems: the Modified Ensuring Quality Information for Patients (mEQIP) and the Quality Analysis of Medical Artificial Intelligence (QAMAI). Readability was evaluated by the Average Reading Level Consensus (ARLC) index. Descriptive and comparative analyses were performed. As no human or patient data were used, ethical approval was exempt.

Results: The mean mEQIP score across models was 84.7 ± 5.5 %, indicating high content quality, and the mean QAMAI score was 27.2 ± 2.0 / 30, reflecting high accuracy and completeness. GPT-4.1 and GPT-5o achieved the highest scores, whereas Gemini Pro provided the least comprehensive content. The mean ARLC grade was 11.0 ± 0.6, corresponding to a college reading level.

Conclusion: AI chatbots can produce accurate, guideline-consistent postoperative information after thoracic surgery; however, their language complexity often exceeds that of most patients. Simplifying expressions and improving transparency are essential before chatbots can be safely integrated into postoperative patient education.

Keywords: artificial intelligence, chatbot, thoracic surgery, postoperative care, patient education, readability

Corresponding Author*: Okan Karataş, M.D. Department of Thoracic Surgery, University of Health Sciences, Antalya Training and Research Hospital, Muratpaşa, 07100, Antalya, Türkiye.

E-mail: dr.okankaratas@hotmail.com Phone: +90 5354968983

Doi: 10.26663/cts.2025.020

Received 22.11.2025 accepted 01.12.2025

Introduction

Artificial intelligence (AI) systems and large language models (LLMs), such as ChatGPT, Gemini, Claude, and Copilot, have recently gained prominence in medicine due to their ability to provide on-demand, human-like explanations to complex questions. These models are increasingly explored in patient education, clinical decision support, and medical documentation. However, despite their rapid adoption, questions remain regarding the accuracy, reliability, and readability of the medical information they generate [1].

Thoracic surgery is a field where accurate patient communication is vital for safe recovery. After lung resection surgery (lobectomy or pneumonectomy), patients must understand detailed instructions related to wound and chest-drain care, respiratory exercises, pain management, and early recognition of complications. Effective education at discharge is a key determinant of postoperative outcomes and adherence to Enhanced Recovery After Surgery (ERAS) protocols [2-4]. Unfortunately, existing patient information materials are often written above the average literacy level, leading to misunderstanding, anxiety, and preventable readmissions [5,6].

AI chatbots may fill this communication gap by delivering personalized, interactive, and accessible postoperative instructions. Yet, their use in thoracic surgery remains poorly studied. Recent research has assessed ChatGPT's performance in cardiothoracic and urologic contexts, with promising results but limited readability [7-10]. Yüksel et al [11] evaluated chatbots in cardiac surgery (CABG) patient education, demonstrating good content quality but excessive linguistic complexity.

Similarly, Ferrari-Light et al [8] analyzed chatGPT's responses to patient questions about lung-cancer surgery, noting factual accuracy but lack of source citation and variable comprehensibility. These findings suggest that while AI chatbots can generate medically sound information, their suitability for direct patient education in thoracic surgery has not yet been established.

To the best of our knowledge, this is the first study in Türkiye to evaluate artificial intelligence chatbots in the field of thoracic surgery, focusing specifically on postoperative patient education. Therefore, this study aimed to evaluate the scientific accuracy, content quality, and readability of AI chatbots' educational materials regarding postoperative care after lung resection. Using validated scoring tools-mEQIP, QAMAI, and ARLC-this research provides a comparative analysis of five major AI chatbots to determine their potential role in postoperative patient education within thoracic surgery.

Materials and Methods

This descriptive and comparative observational study evaluated the quality and readability of educational information generated by artificial intelligence chatbots regarding postoperative care after thoracic surgery. Our study was conducted in October 2025 at the Department of Thoracic Surgery, University of Health Sciences Antalya Training and Research Hospital.

Five publicly accessible chatbots were selected for evaluation, representing different AI architectures and versions: GPT-5o, GPT-4o, GPT-4.1, Claude Opus-4, and Gemini Pro. All chatbots were accessed through their official web interfaces between October 5-8, 2025, using standard default settings and no plug-ins or custom instructions. Each Chatbot was provided with an identical standardized prompt to ensure fair comparison.

The following prompt was used for all chatbots in English: "What should patients pay attention to after lung resection surgery (lobectomy or pneumonectomy)? Please provide accurate, evidence-based, and comprehensible information suitable for the general public. Ensure alignment with recent thoracic surgery and postoperative care guidelines. Include sections about pain management, breathing exercises, drain care, warning signs, and follow-up schedule." Each response was copied into plain text format (.txt) immediately after generation and stored for analysis. No post-editing, rephrasing, or manual correction was performed. The study protocol was reviewed by the University of Health Sciences, Antalya Training and Research Hospital Clinical Research Ethics Committee. The committee determined that formal ethics committee approval was not required as the study utilized publicly available artificial intelligence outputs and did not involve human participants or patient data (Date: 07.11.2025, Decision No: 20/30). Our study used only publicly available artificial intelligence (AI) outputs, in accordance with the principles of the Declaration of Helsinki.

Evaluation criteria

1. mEQIP (Modified Ensuring Quality Information for Patients): This validated tool assesses the content, identification, and structure of health information, with a total of 72 possible points (36, 12, and 24, respectively). Scores were recorded as raw totals and percentages (mEQIP%).

2. QAMAI (Quality Analysis of Medical Artificial Intelligence): A 6-item Likert-scale instrument evaluat-

ing accuracy, clarity, relevance, completeness, sources, and usefulness of AI-generated content. Each item was rated 1-5, producing a total score range of 6–30 points.

3. ARLC (Average Reading Level Consensus): Readability was measured by the ARLC formula, which averages eight readability indices (including Flesch-Kincaid, Gunning Fog, and SMOG). Higher scores indicate more difficult reading levels. According to health literacy standards, patient education materials should not exceed grade 8. All evaluations were performed by an experienced thoracic surgeon who independently applied the scoring tools. Scores were double-checked for internal consistency before statistical analysis.

Statistical Analysis

All data were analyzed using SPSS version 26.0 (IBM Corp., Armonk, NY, USA). Descriptive statistics were expressed as mean ± standard deviation (SD). Normality was assessed using the Shapiro-Wilk test. Differences among chatbots were analyzed using one-way ANOVA, followed by Bonferroni post-hoc testing when significant results were obtained. Inter-rater reliability was not applicable, as all ratings were performed by a single evaluator. A p-value < 0.05 was considered statistically significant.

Results

A total of five chatbots (GPT-5o, GPT-4o, GPT-4.1, Claude Opus-4, and Gemini Pro) were analyzed. Each generated an average response length of 530 ± 85 words. All chatbots successfully produced coherent, medically relevant postoperative instructions in response to the standardized prompt. The individual and mean scores for mEQIP, QAMAI, and ARLC are summarized in Table 1.

GPT-4.1 achieved the highest overall content quality with an mEQIP score of 91.7 % and a QAMAI score of 29, followed closely by GPT-5o. Claude Opus-4 and Gemini Pro demonstrated noticeably lower completeness and structural organization. While GPT-based models (4-series and 5-series) maintained a relatively balanced quality-to-readability ratio, Gemini Pro's content was considerably harder to read (ARLC = 11.8, "very difficult").

The variation across platforms was moderate (SD = 5.5 % for mEQIP), indicating general consistency among the chatbots. However, only GPT-4.1 differed significantly from Gemini Pro in total mEQIP score ($p = 0.008$, ANOVA with Bonferroni correction). In terms of readability, all chatbots exceeded the recommended eighth-grade level, with a mean ARLC grade of 11.0 ± 0.6, confirming that even high-quality outputs remained linguistically complex for the average patient.

Example excerpt generated by GPT-4.1 for the standardized prompt: "After lung resection surgery, you should perform deep-breathing and coughing exercises every hour while awake to keep your lungs clear. Use an incentive spirometer, walk frequently, and support your incision with a pillow when coughing. Monitor your wound for redness, swelling, or discharge, and seek medical help if you experience shortness of breath, fever, or chest pain." This representative output demonstrates the accuracy and guideline alignment of Chatbot responses; however, the sentence structure and vocabulary correspond to a college-level reading grade (ARLC ≈ 11), exceeding recommended patient education standards.

The mean mEQIP score across all chatbots was 84.7 ± 5.5 %, corresponding to "good–excellent" quality. The mean QAMAI score was 27.2 ± 2.0 / 30, indicating high overall informational reliability. GPT-4.1 achieved the highest combined total (mEQIP = 91.7 %, QAMAI = 29), followed closely by GPT-5o (mEQIP = 87.5 %). Gemini Pro provided the least comprehensive output (mEQIP = 76.4 %, QAMAI = 24). Analysis of variance revealed a statistically significant difference in total mEQIP scores among the five models ($F(4, 20) = 4.21$, $p = 0.003$). Bonferroni post-hoc testing showed that GPT-4.1 differed significantly from Gemini Pro ($p = 0.008$). There were no significant differences in QAMAI scores across models ($p = 0.12$) (Figure 1).

The mean ARLC grade level was 11.0 ± 0.6, which exceeds the recommended sixth- to eighth-grade range for patient education. All Chatbot responses were therefore classified as "difficult to read" for the general public. No significant correlation was observed between information quality (mEQIP%) and readability ($r = –0.21$, $p = 0.47$), suggesting that higher-quality content did not necessarily correspond to easier readability (Figure 2).

All chatbots produced factually accurate, guideline-consistent educational information. GPT-4.1 and GPT-5o achieved the highest quality scores with well-structured responses. Gemini Pro and Claude Opus-4 showed reduced completeness and fewer guideline references. The overall readability (ARLC ≈ 11) indicates language complexity beyond the average patient level.

Table 1. Comparison of mEQIP, QAMAI, and ARLC scores among chatbots.

Chatbot	mEQIP (%)	QAMAI (0–30)	ARLC grade	Reading level
GPT-4.1	91.7	29	10.2	Somewhat difficult
GPT-5o	87.5	29	10.8	Fairly difficult
GPT-4o	84.7	28	10.9	Fairly difficult
Claude Opus-4	83.3	26	11.4	Difficult
Gemini Pro	76.4	24	11.8	Very difficult
Mean ± SD	84.7 ± 5.5	27.2 ± 2.0	11.0 ± 0.6	—

Abbrev.: mEQIP – Modified Ensuring Quality Information for Patients; QAMAI – Quality Analysis of Medical Artificial Intelligence; ARLC – Average Reading Level Consensus.Values are presented as mean ± standard deviation (SD) unless otherwise indicated.

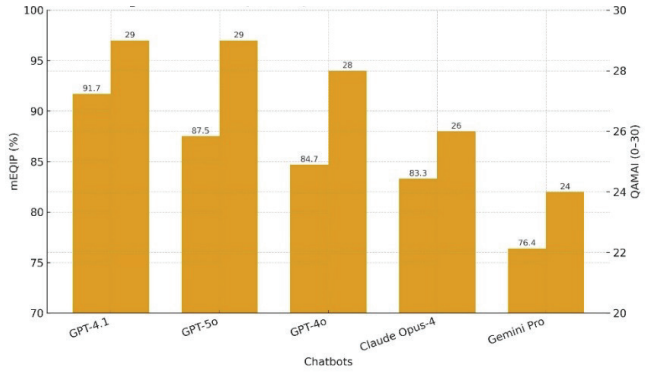

Figure 1. Mean mEQIP and QAMAI scores of evaluated chatbots. (Comparison of information quality (mEQIP %) and overall usefulness (QAMAI / 30) among evaluated chatbots. GPT-4.1 achieved the highest scores, while Gemini Pro demonstrated the lowest).

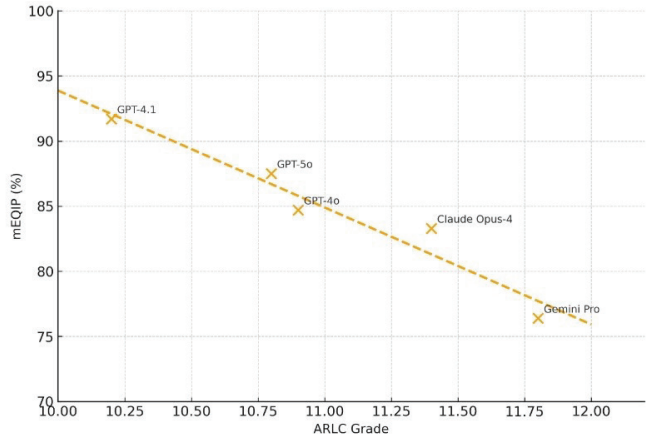

Figure 2. Relationship between readability (ARLC) and information quality (mEQIP). (Scatterplot illustrating the inverse trend between ARLC grade and mEQIP %. Lower ARLC (simpler text) corresponded to slightly higher quality scores).

Discussion

Our study provides a comprehensive evaluation of five artificial intelligence chatbots-GPT-4.1, GPT-5o, GPT-4o, Claude Opus-4, and Gemini Pro regarding the quality, accuracy, and readability of their educational content on postoperative care after thoracic surgery. To our knowledge, this is the first study in the literature to specifically assess chatbots in the field of thoracic surgery using validated scoring tools (mEQIP, QAMAI, and ARLC).

All evaluated chatbots produced coherent, guideline-consistent, and medically relevant responses when asked about postoperative care following lung resection. The mean mEQIP and QAMAI scores (84.7% and 27.2/30, respectively) demonstrate that current large language models (LLMs) can generate text comparable to professional-level educational materials [1]. Among the models, GPT-4.1 and GPT-5o yielded the most accurate and comprehensive responses. This finding aligns with prior studies in other surgical domains. For instance, Yüksel et al [11] reported similar outcomes in coronary artery bypass graft (CABG) education, where chatbots achieved high-quality content but limited readability. Similarly, Shao et al [12] and Platz et al [13] found that chatbots perform reliably in cardiothoracic contexts but lack transparency regarding source citations and evidence hierarchy.

Although the generated content demonstrated strong informational quality, the readability level was found to be well above the recommended range for patient education. The mean ARLC grade was 11.0 ± 0.6, equivalent to college-level text, while medical literacy guidelines recommend content at or below grade 8 [14]. This discrepancy reflects a fundamental limitation of AI-generated patient education materials: advanced linguistic structures and medical terminology reduce accessibility for general readers. Similar results have been reported in oncology [15] and urology [12], where chatbots provided technically accurate but linguistically complex information. Therefore, readability optimization remains a priority before widespread clinical implementation.

Ferrari-Light et al [8] recently assessed chatGPT's performance in lung cancer surgery FAQs, demonstrat-

ing accurate but occasionally incomplete information. Their conclusions parallel our study, which identified high accuracy but variable depth of explanation among chatbots. Furthermore, previous CABG and ophthalmology studies [10,11] confirmed that LLMs maintain factual integrity but inconsistently cite evidence sources. These observations emphasize that AI tools should complement, not replace, clinician-delivered education.

Chatbots could be implemented under supervised frameworks, where thoracic surgeons validate discharge information and multilingual versions assist non-native patients. Such integration would allow safe, standardized, and culturally adapted postoperative education, particularly within ERAS pathways. Future updates of AI models could further support real-time patient communication and remote monitoring under clinical oversight.

From a practical perspective, chatbots can serve as valuable adjuncts for postoperative counseling and discharge education in thoracic surgery. They can reinforce instructions regarding breathing exercises, wound care, and complication warning signs, thus supporting ERAS pathways [2,3]. However, clinicians must remain vigilant, as AI-generated outputs may omit individualized details such as comorbidities, surgical techniques, or medication adjustments. Integrating chatbots into structured, physician-supervised patient education systems could enhance safety, comprehension, and adherence.

Limitations of the study

Our study has several limitations. First, it included only five English-language chatbots and a single standardized prompt, which may not represent real-world variability. Second, the evaluation was conducted by a single thoracic surgeon, so inter-rater reliability could not be assessed. Third, our study focused on text-based outputs, excluding multimodal chatbots capable of generating audio or video instructions. Future research should incorporate multilingual prompts, patient comprehension testing, and comparison across surgical specialties. Additionally, chatbot outputs may evolve over time as models are continuously updated, representing an inherent limitation for reproducibility in AI-based research.

In conclusion, AI chatbots show strong potential for producing accurate and structured educational materials after thoracic surgery. Nevertheless, limited readability remains the foremost barrier to patient-level integration of AI chatbots. The linguistic complexity of their outputs often surpasses the health literacy threshold required for effective clinical adoption. Efforts to simplify language, verify evidence sources, and contextualize information for individual patient needs are crucial before integrating chatbots into postoperative education.

Declaration of conflicting interests

The authors declared no conflicts of interest with respect to the authorship and/or publication of this article.

Funding

The authors received no financial support for the research and/or authorship of this article.

Ethics approval

The study protocol was reviewed by the University of Health Sciences, Antalya Training and Research Hospital Clinical Research Ethics Committee. The committee determined that formal ethics committee approval was not required as the study utilized publicly available artificial intelligence outputs and did not involve human participants or patient data (Date: 07.11.2025, Decision No: 20/30).

Authors' contribution

NÇY: Conceptualization, Methodology, Writing – original draft. OK: Data curation, Formal analysis, Writing – review & editing. MÖ: Validation, Visualization, Supervision.

References

1. Goodman RS, Patrinely JR, Stone CA, Zimmerman E, Donald RR, Chang SS et al. Accuracy and reliability of chatbot responses to physician questions. JAMA Netw Open 2023; 6: 1–13.
2. Batchelor TJP, Rasburn NJ, Abdelnour-Berchtold E, Brunelli A, Cerfolio RJ, Gonzalez M et al. Guidelines for enhanced recovery after lung surgery: recommendations of the ERAS Society and the European Society of Thoracic Surgeons (ESTS). Eur J Cardiothorac Surg 2019; 55: 91–115.
3. Grant MC, D'Ambra MN, Clark JM. Enhanced recovery after thoracic surgery: current evidence and future directions. Ann Thorac Surg 2024; 117: 872–80.
4. Rokah M, Ferri L. Implementation of enhanced recovery after surgery program for lung resection. Curr Chall Thorac Surg 2025; 7: 1–13.

5. Wilson EA, Makoul G, Bojarski EA, Bailey SC, Waite KR, Rapp DN et al. Comparative analysis of print and multimedia health materials: a review of the literature. Patient Educ Couns 2012; 89: 7–14.

6. Berkman ND, Sheridan SL, Donahue KE, Halpern DJ, Crotty K. Low health literacy and health outcomes: an updated systematic review. Ann Intern Med 2011; 155: 97–107.

7. Troian M, Lovadina S, Ravasin A, Arbore A, Aleksova A, Baratella E, Cortale M. An assessment of ChatGPT's responses to common patient questions about lung cancer surgery. A Preliminary Clinical Evaluation of Accuracy and Relevance. J Clin Med 2025; 14: 1676.

8. Ferrari-Light D, Manning MA, Zhang Y, Li Y, Geraci TC, Cerfolio RJ et al. Evaluating ChatGPT as a patient resource for frequently asked questions about lung cancer surgery. J Thorac Cardiovasc Surg 2024; 168: 1432–41.

9. Şahin MF, Topkaç EC, Doğan Ç. Still using only ChatGPT? Comparison of five different artificial intelligence chatbots' answers to the most common questions about kidney stones. J Endourol 2024; 38: 1172–7.

10. Hua HU, Kaakour AH, Rachitskaya A, Srivastava S, Sharma S, Mammo DA. Evaluation and comparison of ophthalmic scientific abstracts and references by current artificial intelligence chatbots. JAMA Ophthalmol 2023; 141: 819–24.

11. Yüksel G, Gürkan S. Evaluation of the performance of current AI chatbots regarding patient information after coronary artery bypass graft surgery. J Health Sci Med 2025; 8: 421–8.

12. Shao J, Zhou Y, Xu W, Zhang C, Lin T. Assessing the performance of large language model chatbots in answering patient questions in urology: comparison among ChatGPT, Bing, and Bard. Urology 2024; 182: 67–73.

13. Platz A, Schmid P, Haller G, Baeriswyl M. Large language model chatbots in cardiothoracic surgery: evaluation of accuracy and content quality of patient education material. Interact Cardiovasc Thorac Surg 2024; 39: 161–8.

14. Weiss BD. Health Literacy and Patient Safety: Help Patients Understand. Chicago, IL: American Medical Association Foundation; 2007.

15. Wang YC, Xue J, Tu YC, Chung YC, Chang Y, Chen CY. Evaluating ChatGPT's accuracy and readability in answering patient questions about breast cancer. Breast Cancer Res Treat 2024; 197: 633–42.

This article is an open access article distributed under the terms and conditions of the Creative Commons Attribution (CC BY) license (http://creativecommons.org/licenses/by/4.0/).

To cite this article: Tanrıkulu G, Melek H, Sevinç TE, Özer E, Yentürk E, Bayram AS, Gebitekin C. Intercostal nerve reconstruction for compensatory hyperhidrosis: clinical outcomes of the "Gebitekin technique". Curr Thorac Surg 2025;10(3):114-123.

Original Article

Intercostal nerve reconstruction for compensatory hyperhidrosis: clinical outcomes of the "Gebitekin technique"

Gamze Tanrıkulu[1]*, Hüseyin Melek[2], Tolga Evrim Sevinç[3], Erhan Özer[2], Eylem Yentürk[4], Ahmet Sami Bayram[2], Cengiz Gebitekin[2]

[1]Department of Thoracic Surgery, Gülhane Training and Research Hospital, University of Health Sciences, Ankara, Türkiye
[2]Department of Thoracic Surgery, Faculty of Medicine, Uludag University, Bursa, Türkiye
[3]Clinical Research Center, Faculty of Medicine, Koç University, Istanbul, Türkiye
[4]Department of Thoracic Surgery, Yedikule Chest Diseases and Surgery Training and Research Hospital, Istanbul, Türkiye

ABSTRACT

Background: Compensatory hyperhidrosis (CH) is the most common complication following endoscopic thoracic sympathectomy (ETS) and significantly impairs quality of life (QOL). This study assesses and compares the QOL before and after our minimal invasive intercostal nerve reconstruction technique (the "Gebitekin Technique", GT) in CH patients.

Materials and Methods: Between January 2014 and November 2016, 32 consecutive CH patients underwent GT. Patients' satisfaction levels and demographic parameters were self-assessed before surgery and six months postoperatively using the World Health Organization Quality of Life questionnaire (WHOQOL-BREF) and institutional questionnaires.

Results: A total of 64 surgeries were performed in 32 patients with a mean age of 32.5 ± 6.77 years. All patients who underwent GT responded to the questionnaires. Improvement of CH symptoms was observed in 24 (75%) patients, along with improvement in dryness in 60%. None of the patients had recurrence of primary hyperhidrosis. Significant ($p < 0.05$) improvements were observed in all survey sub-areas following surgery.

Conclusion: This study demonstrates that GT improves QOL and alleviates related symptoms in the overwhelming majority of patients with CH.

Keywords: compensatory hyperhidrosis, intercostal nerve reconstruction, survey, quality of life, Gebitekin technique

Corresponding Author*: Gamze Tanrıkulu, MD. University of Health Sciences, Gulhane Training and Research Hospital, Department of Thoracic Surgery, Ankara, Türkiye.
E-mail: gamzece019@hotmail.com Phone: +90 5077046416
Doi: 10.26663/cts.2025.021
Received 10.10.2025 accepted 24.11.2025

Introduction

Primary focal hyperhidrosis (PFH) involves the hands, feet, face, and/or axilla, with a prevalence ranging from 1% to 3% [1]. When medical treatment fails, endoscopic thoracic sympathectomy (ETS) represents the standard therapeutic option. The presence of the 'Kuntz nerve' - an alternative pathway running parallel to the sympathetic chain between the T1 and T2 levels - constitutes an important cause of failure [2]. Compensatory hyperhidrosis (CH) - defined as excessive sweating in anatomical regions where previously there was no significant sweating - may be observed in 3% to 98% of cases [1]. Once it develops, CH greatly impairs patients' quality of life (QOL), and medical treatments usually fail [3]. Promising results of surgical sympathetic pathway reconstruction have been reported lately [4].

A novel intercostal-to-intercostal nerve reconstruction technique, termed the "Gebitekin Technique" (GT), has been developed to create an alternative pathway to the sympathetic chain through the intercostal nerves, thereby potentially reducing the likelihood of CH [5].

This study aimed to compare pre- and postoperative QOL and patient satisfaction following treatment of CH using the GT.

Materials and Methods

This prospective study was conducted at the Department of Thoracic Surgery, Uludag University, between January 2014 and November 2016, following the approval of the institutional ethics committee. Patients who developed compensatory hyperhidrosis were informed in detail about the 'Gebitekin Technique' (GT). Surgical treatment was performed on those who consented to the procedure. Data analysis was conducted for this patient cohort after a follow-up period of two years."

The decision to operate was based on complaints and symptoms that adversely affected daily or social life and impaired QOL. Written informed consent was obtained from all patients. All patients undergoing surgery completed, both preoperatively and 6 months postoperatively, the WHO Quality of Life Scale-Short Form (WHOQOL-BREF) and a second in-hospital questionnaire, which was based on and extended the WHOQOL-BREF questions. For example, patients were asked, "How much does your sweating prevent you from accomplishing your daily tasks?" and instructed to provide a score between 1 and 5 (1 = none, 5 = greatly).

The "Gebitekin Technique"

The technique involves creating an end-to-end anastomosis between the two intercostal nerves located proximal and distal to the sympathetic chain levels previously cut or clipped during ETS.

Under general anesthesia with double-lumen intubation, the patient is placed in the lateral decubitus position, and surgery is performed using biportal videothoracoscopy. The intercostal nerves above and below the level of the previous cutting or clipping are dissected without cautery and then divided. If present, clips are removed after intercostal nerve dissection (Figure 1).

The prepared intercostal nerves are approximated end-to-end using one or two interrupted 5/0 polydioxanone sutures (PDS), avoiding direct manipulation of the nerves. The anastomosis is then inspected and secured to the pleural surface with fibrin glue (Figure 1) [5]. After achieving hemostasis, a 16–20F chest drain is inserted into the pleural cavity. During the same session, the technique is repeated on the contralateral hemithorax.

WHOQOL-BREF Survey / Questionnaire and Analysis Assessment

The WHOQOL-BREF questionnaire [6–8] was re-administered after six months, together with an in-house questionnaire assessing patients' satisfaction levels. In addition, the question "How much does your sweating prevent you from accomplishing your daily tasks?" was re-administered.

Quality of life (QOL) was measured using the Turkish version of the WHOQOL-BREF (WHOQOL-BREF-TR). The validity and reliability of the Turkish version of the WHOQOL-BREF were established by Eser et al [9]. The WHOQOL-BREF-TR questionnaire is presented in Table 1.

The study was approved by the Uludag University Ethics Committee (03/2017-4/41) and the Institutional Review Board. Written informed consent was obtained from all patients, including consent for the use of their anonymized data for research and publication purposes, in accordance with the principles of the Declaration of Helsinki.

Table 1. WHOQOL-BREF domains.	
Domain	Facets incorporated within domains
1. Physical health	Activities of daily living Dependence on medication and medical aids Energy and fatigue Mobility Pain and discomfort Sleep and rest Work capacity
2. Psychological	Bodily image and appearance Negative feelings Positive feelings Self-esteem Spirituality / Religion / Personal beliefs Thinking, learning, memory and concentration
3. Social relationships	Personal relationships Social support Sexual activity
4. Environment	Financial resources Freedom, physical safety and security Health and social care accessibility and quality Home environment / Transport Opportunities for acquiring new information and skills Participation in, and opportunities for, recreation and leisure activities Physical environment (pollution / noise / traffic / climate)

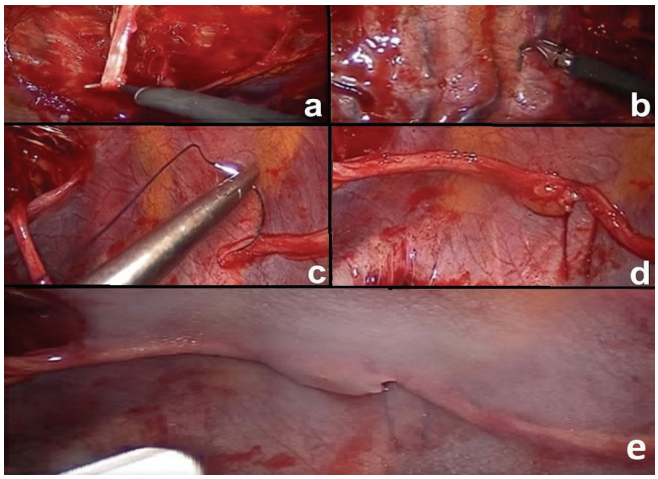

Figure 1. Intraoperative view of the Gebitekin Technique. Intercostal nerve dissection. An endoscopic clamp is used to push the clip downward to pass the pleura, clips are removed from the closed end using an endoscopic clamp **(a,b)**, nerve anastomosis is performed using PDS sutures **(c,d)**, intercostal nerves are supported with fibrin glue after end-to-end anastomosis **(e)**.

Statistical Analysis

The normality of variable distribution was tested using the Shapiro–Wilk test, and results were expressed as mean ± standard deviation (SD). An independent samples t-test was used to compare two independent groups, and a paired samples t-test was used to compare two dependent groups. The Mann–Whitney U test was used to compare two independent groups, the Wilcoxon signed-rank test was used to compare two dependent groups. Categorical variables were expressed as frequencies and percentages (n, %), and compared using the Pearson chi-square test or Fisher's exact test. Relationships between variables were examined using Spearman's correlation coefficient. Statistical analyses were performed using SPSS Statistics version 22.0, and ROC analysis was conducted with MedCalc version 12.3.0.0. A p-value of <0.05 was considered statistically significant.

Results

A total of 36 patients were evaluated. Thirty-two patients constituted the study group, as four were excluded due to failed intercostal-to-sympathetic nerve anastomosis surgery, resulting in 32 VATS GT procedures. These patients formed the basis of the QOL assessment. The study group consisted of 23 males (72%) and nine females, with a mean age of 32.5 ± 6.77 years (Table 2).

Facial sweating was the most common indication for ETS (12/32, 37.5%). ETS was limited to one level in 11 patients (34.3%), and 14 patients (43.7%) underwent ETS with clipping. The median interval between ETS and GT was 48 months (range: 8–192) (Table 2).

Multifocal CH was observed within the first month after surgery in 23 patients (71.8%). Severe CH was present in all but two patients and was accompanied by excessive dryness, depression, fatigue, loss of excitement, loss of libido, and upper extremity weakness in 23 patients (71.8%). Excessive dryness at the PFH site was observed in 15 patients (46.8%). Fifty percent of the patients had previously received medical treatment.

Preoperatively, patients were asked to rate their complaints on a scale of 1 to 5 (1 = none, 5 = severe) and to indicate whether they regretted undergoing the ETS

operation and how much CH affected their daily lives. All but two patients (2/32, 93.8%) regretted undergoing ETS, and 84% (n = 27) stated that their daily lives were severely limited by CH.

The preoperative WHOQOL-BREF questionnaire showed that 26 patients (81.2%) reported having poor QOL, and none of the patients (100%) were satisfied with their QOL. Fourteen patients (43.75%) reported being dissatisfied with their health (Question 2). Six patients also reported complaints regarding their sexual life.

All but one patient underwent bilateral nerve surgery in the same surgical session using two-port videothoracoscopy. The mean duration of anesthesia for bilateral operations was 165.16 minutes (range: 100–255). In fifteen patients (43.7%), the first intercostal nerve was used for anastomosis.

Hemothorax occurred in four patients (4/32, 12.5%), who were treated with VATS exploration within 24 hours postoperatively. Late complications included areolar hyperaesthesia in three patients and a keloid scar in one patient. In addition, hypoesthesia was observed in 13 patients in the corresponding area of the intercostal nerve used for anastomosis. All complaints, except for nipple hyperaesthesia observed in two patients, were transient and subsided within 6 months after surgery.

Twenty-four patients (75%) reported a reduction in CH. The median decrease in CH among all patients was 20% (range: 0–70%). In the ROC analysis, it was found that a 12.5% decrease in CH was associated with a reduction in the number of daily clothing changes reported by patients. The area under the ROC curve (AUC) was found to be statistically significant ($p < 0.0001$) in this analysis. In addition, the reduction in CH was not affected by the timing of GT ($p = 0.661$).

In the postoperative period, patients were asked about the regression rate after GT and the degree to which CH affected their daily lives, which decreased from 84% (n = 27) to 31.3% (n = 10) ($p < 0.01$). Only four patients (12.5%) regretted undergoing the GT operation. The number of daily clothing changes decreased in 19 patients (59.4%) ($p < 0.01$). Eighteen patients (56.2%) recommended GT, and six patients (18.7%) were indecisive.

There was similar reliability between the preoperative and 6-month postoperative WHOQOL-BREF-TR questionnaires (Cronbach's alpha coefficients: 0.891 and 0.925, respectively), and no statistical significance was observed among other preoperative variables studied. However, the improvement in symptoms after GT was statistically significant in patients who had previously undergone a T2 block with ETS ($p = 0.041$). In other words, when intercostal nerve reconstruction was performed, recovery rates were significantly better in patients in whom the T1 nerve was used ($p = 0.041$) (Table 3).

When the domains of health in the preoperative WHOQOL-BREF questionnaire were examined, the domain most affected by CH was the psychological subgroup (mean score: 10.21, range: 4–17.33). The next lowest score was in the social health subgroup, with a mean score of 11.83 (range: 4–20) (Table 4).

The results of the WHOQOL-BREF questionnaire, which was re-administered postoperatively, identified 16 patients (50%) who reported that their quality of life was good or very good (4 or 5 points). In the postoperative period, the number of patients requiring extensive medical treatment (5 points) for their complaints decreased to seven. The number of patients dissatisfied with their sexual life and those not satisfied with their health both declined to three, respectively. When the percentage changes in the preoperative and postoperative survey subdomains were compared, the questions showing the greatest variation were questions 4, 1, and 2, respectively.

The statistical evaluation of the WHOQOL-BREF questionnaire was based on percentage changes. The calculation was performed as follows: Percentage change = (postoperative value – preoperative value) / preoperative value.

Percentage change scores for the WHOQOL-BREF subdomains are summarized in Table 5. Patients with ≥ 4 hyperhidrosis regions showed significantly greater improvements in physical health ($p = 0.018$) and environmental health ($p = 0.03$) compared with those with ≤ 3 regions, whereas no differences were observed in the psychological or social domains. When comparing

ETS methods, patients treated with clips demonstrated a greater median improvement in physical health scores compared with those treated with cautery or dissection (p = 0.045). In addition, patients who reported postoperative sweating or moistening at the initial ETS sites showed significantly greater improvements in physical health compared with those without such symptoms (p = 0.029).

Twenty-four patients (75%) reported a reduction in reflex sweating. The median decrease in reflex sweating across all patients was 20% (range: 0–70). In the ROC analysis performed to determine a cut-off value at which the reduction in sweating percentage would correspond to a decrease in the number of daily clothing changes, it was found that a 12.5% reduction in reflex sweating was associated with fewer clothing changes. As the p-value was <0.0001, the area under the ROC curve (AUC) was considered statistically significant. At the 6-month postoperative follow-up, patients were asked to what extent their CH symptoms were reduced, and the ROC analysis was conducted based on their responses. Patients were divided into two groups: those with a reduction of < 12.5% in CH and those with ≥ 12.5%. There was a statistically significant percentage change when the physical and psychological subdomains of the WHOQOL-BREF questionnaire were compared between these groups (pPA = 0.006, pPSA = 0.009, pSA = 0.022, pEA = 0.223).

Table 2. Patients demographical information.

Variable		*n (%)
Age (years)		32.09±6.77
Sex	Female	9 (28.13%)
	Male	23 (71.88%)
Marital status	Single	20 (62.50%)
	Married	10 (31.25%)
	Divorced	2 (6.25%)
Occupation	Social	11 (34.38%)
	Requires effort	8 (25.00%)
	Others	13 (40.63%)
Education level	Elementary	1 (3.13%)
	High school	6 (18.75%)
	Associate	7 (21.88%)
	Undergraduate	16 (50%)
	Postgraduate	2 (6.25%)
ETS etiology	Single region hyperhidrosis	19 (59.38%)
	Hyperhidrosis in more than 1 region	13 (40.63%)
	Facial sweating and flushing	12 (37.5%)
ETS method	Clipping	14 (43.75%)
	Cautery/Dissection	18 (56.25%)
ETS anatomic level	Single level block	11 (34.38%)
	Block in more than 1 level	21 (65.62%)
Number of compensatory hyperhidrosis regions	≤3	15 (46.88%)
	≥4	17 (53.13%)
Time interval between the two surgeries	<48 months	14 (43.75%)
		18 (56.25%)

ETS: Endoscopic thoracic sympathectomy, n: number of patients

Table 3. Comparison of the variables between two groups (patients with a reduction in compensatory sweating symptoms after GT/patients with no change in symptoms after GT).				
Variables		No change in symptoms (n=8)	Reduced symptoms (n=24)	p-value
Age* (min-max)		30.63 (24-41)	32.58 (22-48)	0.487
Sex	Female	3 (33.3%)	6 (66.7%)	0.654
	Male	5 (21.7%)	18 (78.3%)	
Marital Status	Single	4 (18.2%)	18 (81.8%)	0.218
	Married	4 (40.0%)	6 (60.0%)	
Occupation	Social	3 (27.3%)	8 (72.7%)	1.000
	Requiring effort	2 (25.0%)	6 (75.0%)	
	Others	3 (23.1%)	10 (76.9%)	
Education Level	Elementary	0 (0.0%)	1 (100.0%)	0.359
	High school	0 (0.0%)	6 (100.0%)	
	Associate	3 (42.9%)	4 (57.1%)	
	Undergraduate	4 (25.0%)	12 (75.0%)	
	Postgraduate	1 (50.0%)	1 (50.0%)	
Altitude at residence	Sea level	6 (30%)	14 (70%)	0.676
	High altitude	2 (16.7%)	10 (83.3%)	
Reason for ETS	Single indication	5 (26.3%)	14 (73.7%)	1.000
	Multiple indications	3 (23.1%)	10 (76.9%)	
Region of hyperhidrosis	Face	2 (16.7%)	10 (83.3%)	0.676
	Others	6 (30%)	14 (70%)	
Number of ETS levels	Single	2 (18.2%)	9 (81.8%)	0.681
	Multiple	6 (28.6%)	15 (71.4%)	
ETS levels	T2 included	1 (6.7%)	14 (93.3%)	0.041
	T2 excluded	7 (41.2%)	10 (58.8%)	
ETS method	Clipping	3 (21.4%)	11 (78.6%)	1.000
	Cautery	5 (27.8%)	13 (72.2%)	
Regions of compensatory hyperhidrosis	3 or less	4 (26.7%)	11 (73.3%)	1.000
	4 or more	4 (23.5%)	13 (76.5%)	
Time interval between the two surgeries	<48 months	4 (28.6%)	10 (71.4%)	0.703
		4 (22.2%)	14 (77.8%)	

**Median age was taken into consideration.ETS: Endoscopic thoracic sympathectomy, GT: Gebitekin Technique. p-value < 0.05 was considered as statistically significant*

Table 4. Preoperative and postoperative changes of the WHOQOL-BREF questionnaire subfield/area of health scores.			
Subfield values	Preop value (min/max)	Postop value (min/max)	p value
Physical	12.29 (6.86/17.14)	16.57 (6.29/20.00)	<0.001
Psychological	10.34 (4.00/17.33)	15.33 (4.67/18.67)	<0.001
Social	12.00 (4.00/20.00)	14.67 (4.00/20.00)	<0.001
Environmental	14.50 (9.50/18.00)	16.00 (7.00/19.50)	0.010

Scores were calculated as described in the literature [8]
p-value < 0.05 was considered as statistically significant

Table 5. Factors affecting percentage changes of survey subfields.

Variables/Subfields		Physical	Psychological	Social	Environmen al	PhS p-value	PsS p-value	SS p-value	ES p-value
Sex	Female	0.353	0.562	0.077	0.037	0.363	0.229	0.681	0.458
	Male	0.188	0.214	0.144	0.059				
Reason for ETS indication	Single	0.259	0.200	0.144	0.083	0.887	0.545	0.362	0.880
	Multiple	0.210	0.267	0.083	0.037				
ETS level	Single	0.259	0.168	0.101	0.103	0.531	0.938	0.907	0.144
	Multiple	0.188	0.236	0.143	0.033				
ETS method	Clips	0.358 (-0.02-0.81)	0.354	0.129	0.057	0.045	0.613	0.667	0.639
	Cautery/ Dissection	0.170 (-0.14-0.94)	0.214	0.122	0.044				
Time interval between ETS and GT	<48 months	0.171	0.191	0.122	0.068	0.283	0.488	0.925	0.896
	≥48 months	0.317	0.257	0.153	0.049				
Number of compensatory sweating regions	≤3 regions	0.100 (-0.14-0.63)	0.214	0.181	0.029 (-0.26-0.17)	0.018	0.331	0.455	0.027
	≥4 regions	0.280 (-0.05-0.94)	0.278	0.077	0.103 (-0.220.38)				
Complaints besides compensatory sweating	None	0.133 (-0.14-0.81)	0.171	0.074	0.029	0.029	0.110	0.515	0381
	Yes	0.353 (-0.08-0.94)	0.517	0.223	0.087				
Proximal nerve used for GT	T1	0.196	0.241	0.241	0.057	0.512	0.866	0.488	0.837
	T2	0.270	0.225	0.089	0.048				

Abbrev.; ETS: Endoscopic thoracic sympathectomy, GT: Gebitekin Technique, PhS:, PsS: subfield, SS: subfield, ES: PC: Percent change. p-value < 0.05 was considered as statistically significant

Discussion

Primary focal hyperhidrosis is a condition that severely impairs individuals' quality of life (QOL) by affecting their social and professional functioning. The gold standard treatment is surgery, and the most common postoperative complication is compensatory hyperhidrosis (CH) [2,10]. The search for effective treatments for CH is ongoing, with the goal of identifying a permanent approach that may reverse its impact on professional life, QOL, and psychological well-being. Patient complaints have prompted surgeons to develop ETS techniques aimed at minimizing side effects. One such measure was to reduce the levels of ETS performed for PFH, preferably avoiding T2 sympathectomy whenever possible [1,10,11]. A recent meta-analysis by Zhang et al [11] reported that the lowest complication rates were observed in T4 ETS. According to Weksler et al [12], patients with more than one ganglion blockade had a higher risk of developing CH. As a result, Cerfolio et al [1] suggested that operations at the T2 level should be performed only in patients with craniofacial sweating or flushing, and that the associated risks should be explained in detail during preoperative discussions. Unfortunately, severe CH due to ETS still has an incidence of 27.2% [13].

The first nerve reconstruction for the treatment of compensatory hyperhidrosis was performed by Telaranta [14], who used the sural nerve via thoracotomy. After the operation, the reduction in the patient's hot flashes and the decreased severity of CH generated hope for a potential treatment. Another free-flap procedure was performed by Wong et al [15], incorporating the intercostal nerves.

A firefighter with post-sympathectomy hot flashes experienced complete resolution of symptoms after insertion of an intercostal nerve graft between T2 and T4. There are studies in the literature in which intercostal nerves have been used not only at the level of the sympathetic chain but also for brachial plexus injuries [16]. Haam et al [17] presented a series of 19 intercostal nerve implantations in which the distal healthy intercostal nerve, after clearance of fibrosis from the sympathetic chain ends, was transplanted to the area of damage. In

9 of the 19 patients, CH symptoms were markedly reduced. Park et al [4] reported minimal success with the Melbourne Technique, in which a superficial vein graft from the forearm enveloped both ends of the sympathetic chain that had been damaged by ETS. In our clinic, we initially applied a technique similar to that of Haam et al [17]. However, the feedback received from patients was not favorable. This may be related to the fact that the healthy tissue at the proximal damaged end of the sympathetic chain could not be identified macroscopically.

These unsuccessful results prompted us to search for a new method to treat CH. Our hypothesis was that anastomosis of the intercostal nerves above and below the compromised section of the sympathetic chain could create an alternative pathway similar to the Kuntz nerve pathway. Because intercostal nerves have motor, sensory, and autonomic functions, transmission is bidirectional. Additionally, sensory disturbances in the areas of the intercostal nerves used for anastomosis can be compensated by the intercostal nerves above and below the anastomosis. Therefore, intercostal nerve reconstruction does not result in permanent side effects in patients. It is also suggested that the fibrin glue used at the anastomosis line during surgery is important in the initial phase of peripheral nerve regeneration, promoting Schwann cell proliferation [18].

Fifty percent of the patients who underwent GT rated their quality of life as 4 or 5 points after surgery. Furthermore, following the resolution of CH in one of the two patients who had attempted suicide, the patient reported that he no longer required treatment for depression and was able to continue his daily life as normal. In one patient, the heart rate after ETS was less than 50 beats per minute, which increased to 75 during the postoperative follow-up period, resulting in a marked improvement in chronic fatigue.

When patients were asked about the percentage reduction in their CH symptoms, a threshold of ≥10% was accepted as a clinically significant decrease. Thus, 75% of the patients were found to have reduced sweating. Despite this high success rate, the relatively lower satisfaction rate (65.53%) may be attributed to the very high expectations of the patients.

In this treatment method, achieving predictability and consistency in each patient is challenging. Therefore, we compared the preoperative and postoperative responses subjectively. In this context, we applied the 26-item Turkish version of the WHOQOL-BREF questionnaire to assess QOL. We also prepared a short questionnaire to learn about patients' thoughts on ETS, their symptoms, and their history of CH. This newly developed questionnaire aimed to determine the extent to which the operation contributed to patients' quality of life preoperatively and at 6 months postoperatively. This newly developed questionnaire aimed to determine the extent to which the operation contributed to patients' quality of life preoperatively and at 6 months postoperatively.

Intercostal nerve reconstruction reduced sweating in most patients who underwent anastomosis, particularly at the T1 level. The most likely explanation for this may be the excess of T1 efferent fibers. The most important consideration when using the T1 intercostal nerve is to avoid damaging the T1 root that contributes to the brachial plexus. At this level, the intercostal nerve has no sensory branch, and the spinal nerve, once exiting the intervertebral foramen, divides into a thick anterior branch that joins the plexus and a thin intercostal branch. Therefore, dissection of the intercostal nerve should be performed as distally as possible at the lower border of the first rib. None of our patients developed symptoms suggestive of brachial plexus injury. Similarly, none of our patients developed Horner's syndrome.

When examining the health subdomains of the WHOQOL-BREF questionnaire, we found that the psychological health domain had the greatest percentage change, increasing from 10.34 to 15.33 ($p < 0.001$). This finding is not coincidental. When CH symptoms resolved, stress was alleviated, anxiety was reduced, the need for frequent clothing changes decreased, and daily comfort levels increased. Since the data in our study are based on subjective assessments of patient satisfaction, we aimed to determine the threshold of symptom reduction required to improve overall QOL, as compared with patients' reported need for daily clothing changes. As a result of the ROC analysis, a 12.5% decrease in CH symptoms, with 76.92% specificity and 84.21% sensitivity, was identified as the benchmark for reducing the need for daily clothing changes and thereby im-

proving QOL. These data are meaningful in terms of the reliability of patients' subjective evaluations.

Complications related to GT were minor in nature. During the first year of applying the method, a Hemovac drain was placed at the end of the operation. However, due to the risk of hemothorax developing in the early postoperative period, placement of chest drains became the preferred approach. In the four patients in whom hemothorax developed, VATS was the preferred treatment method, since tube thoracostomy could potentially damage the anastomosis. Given the total sample size of 32 patients, the observed complication rates may appear comparatively high. In the period following the description and adoption of the technique, hemothorax occurred during follow-up, likely due to the use of reduced cauterization in the reconstruction area to avoid neural injury. Based on this clinical experience, hemostasis practices were subsequently reinforced, and no further cases of hemothorax were observed in our later series. Revision procedures were performed with VATS, and no active bleeding was detected during these procedures. It was found that tissue adhesives (fibrin glue) applied to the anastomosis line secured the anastomosis to the chest wall. Hyperalgesia that developed in the breasts of two women did not completely resolve. Hypoesthesia or hyperalgesia of the breast is also an important problem affecting female sexual life. For this reason, we perform intercostal nerve reconstruction using the T6 intercostal nerve in women.

In the study published by Rantanen and Telaranta [19] in 2017, 19 patients underwent treatment for CH using free intercostal or sural nerve grafts, and preoperative and postoperative surveys were administered to the patients, similar to our study. A success rate of approximately 75% was reported based on the results of these surveys. However, this questionnaire lacks validity and reliability, as it was developed in a single clinic and the yield of the study was as low as 12.6%. In comparison with other reconstruction methods performed for the treatment of CH, our study demonstrated a 75% success rate with the largest case series and a 65.63% satisfaction rate, based on the subfields of the WHOQOL-BREF questionnaire, making GT the most effective treatment for CH.

Limitations of the study

The present study has several limitations. First, the cohort size was modest, reflecting the rarity of patients undergoing intercostal nerve reconstruction for compensatory hyperhidrosis. Second, a control group was not included, as the procedure is performed selectively in patients with severe CH unresponsive to medical management. Third, the follow-up period of six months provides preliminary but not long-term outcomes. Future prospective studies with larger sample sizes, control groups, and extended follow-up will be necessary to confirm the durability and generalizability of these results.

In conclusion, our survey study demonstrated that patients with CH still represent an unmet clinical need, and the GT offers significant improvements in quality of life, with safe, high, and long-term success rates.

Declaration of conflicting interests

The authors declared no conflicts of interest with respect to the authorship and/or publication of this article.

Funding

The authors received no financial support for the research and/or authorship of this article.

Ethics approval

The study was approved by the Uludag University Ethics Committee (03/2017-4/41) and the Institutional Review Board.

Authors' contribution

GT: Conceptualization, Methodology, Writing – original draft. HM: Data curation, Investigation. TES: Formal analysis, Visualization. EÖ: Validation, Supervision. EY: Data curation, Software. ASB: Supervision, Validation. CG: Conceptualization, Project administration, Supervision.

References

1. Cerfolio RJ, De Campos JR, Bryant AS, Connery CP, Miller DL, DeCamp MM, et al. The Society of Thoracic Surgeons expert consensus for the surgical treatment of hyperhidrosis. Ann Thorac Surg 2011; 91: 1642-8.

2. Licht, PB, Hyperhidrosis. Thorac Surg Clin 2016; 26: 9-10.

3. Lyra Rde M, Campos JR, Kang DW, Loureiro Mde P, Furian MB, Costa MG, et al. Sociedade Brasileira de Cirurgia Torácica. Guidelines for the prevention, diagnosis and treatment of compensatory hyperhidrosis. J Bras Pneumol 2008; 34: 967-77.

4. Park HS, Hensman C, Leong J. Thoracic sympathetic nerve reconstruction for compensatory hyperhidrosis: the Melbourne technique. Ann Transl Med 2014; 2: 45.

5. Gebitekin C, Melek H, Çetinkaya G, Ozer E, Yenturk E, Sevinç TE, et al. Intercostal nerve reconstruction for severe compensatory hyperhidrosis: The Gebitekin Technique. Ann Thoracic Surg 2021; 111: 443-46.

6. Group, TW, The World Health Organization quality of life assessment (WHOQOL): development and general psychometric properties. Soc Sci Med 1998; 46: 1569-85.

7. Group, W. Development of the World Health Organization WHOQOL-BREF quality of life assessment. Psychol Med 1998; 28: 551-58.

8. Organization WH, WHOQOL-BREF: introduction, administration, scoring and generic version of the assessment: field trial version, December 1996.

9. Eser E, Fidaner H, Fidaner C, Eser SY, Elbi H, Göker E. Psychometric properties of the WHOQOL-100 and WHOOOL-BREF. Psikiyatri Psikoloji Psikofarmakoloji (3P) Dergisi 1999; 7: 23-40.

10. Montessi J, Almeida EP, Vieira JP, Abreu Mda M, Souza RL, Montessi OV. Video-assisted thoracic sympathectomy in the treatment of primary hyperhidrosis: a retrospective study of 521 cases comparing different levels of ablation. J Bras Pneumol 2007; 33: 248-54.

11. Zhang W, Yu D, Wei Y, Xu J, Zhang X. A systematic review and meta-analysis of T2, T3 or T4, to evaluate the best denervation level for palmar hyperhidrosis. Sci Rep 2017: 9; 7: 129.

12. Weksler B, Blaine G, Souza ZB, Gavina R. Transection of more than one sympathetic chain ganglion for hyperhidrosis increases the severity of compensatory hyperhidrosis and decreases patient satisfaction. J Surg Res 2009; 156: 110-5.

13. de Andrade Filho LO, Kuzniec S, Wolosker N, Yazbek G, Kauffman P, de Campos JR, et al. Technical difficulties and complications of sympathectomy in the treatment of hyperhidrosis: an analysis of 1731 cases. Ann Vasc Surg 2013; 27: 447-53.

14. Telaranta T. Secondary sympathetic chain reconstruction after endoscopic thoracic sympathicotomy. Eur J Surg Suppl 1998; 580: 17-8.

15. Wong RH, Ng CS, Wong JK, Tsang S. Needlescopic video-assisted thoracic surgery for reversal of thoracic sympathectomy. Interact Cardiovasc Thorac Surg 2012; 14: 350-2.

16. Malessy MJ, Thomeer RT. Evaluation of intercostal to musculocutaneous nerve transfer in reconstructive brachial plexus surgery. J Neurosurg 1998; 88: 266-71.

17. Haam SJ, Park SY, Paik HC, Lee DY. Sympathetic nerve reconstruction for compensatory hyperhidrosis after sympathetic surgery for primary hyperhidrosis. J Korean Med Sci 2010; 25: 597-601.

18. Kalbermatten DF, Pettersson J, Kingham PJ, Pierer G, Wiberg M, Terenghi G. New fibrin conduit for peripheral nerve repair. J Reconstr Microsurg 2009; 25: 27-33.

19. Rantanen T, Telaranta T. Long-Term Effect of Endoscopic Sympathetic Nerve Reconstruction for Side Effects after Endoscopic Sympathectomy. Thorac Cardiovasc Surg 2017; 65: 484-90.

This article is an open access article distributed under the terms and conditions of the Creative Commons Attribution (CC BY) license (http://creativecommons.org/licenses/by/4.0/).

To cite this article: Nabi MS, Sarwar Z. Talc pleurodesis for hepatic pleural effusions: clinical outcomes following serum albumin optimization. Curr Thorac Surg 2025;10(3):124-130.

Original Article

Talc pleurodesis for hepatic pleural effusions: clinical outcomes following serum albumin optimization

Muhammad Shoaib Nabi, Zeeshan Sarwar*

Department of Thoracic Surgery, Services Institute of Medical Sciences (SIMS), Services Hospital, Lahore, Punjab, Pakistan

ABSTRACT

Background: Hepatic hydrothorax is a debilitating complication of advanced liver disease, often unresponsive to medical therapy. In settings where liver transplantation and TIPS are not readily available, talc pleurodesis may offer effective palliation. This study evaluates its outcomes, safety, and predictors of recurrence in such patients.

Materials and Methods: A retrospective observational review study was conducted on 52 patients undergoing talc pleurodesis for hepatic hydrothorax between January 2020 and June 2025. Data included demographics, liver disease etiology, Child–Pugh class, MELD score, serum albumin, chest tube duration, hospital stay, recurrence, and complications. Quantitative variables were expressed as mean ± SD, and correlations were analyzed using Pearson's r.

Results: Mean age was 61.2 ± 7.2 years; 67.3% were male. Hepatitis C was the leading etiology (96.2%), and 82.7% were Child–Pugh class C. Mean MELD score was 15.2 ± 5.4, correlating with both Child–Pugh class (r = 0.67) and recurrence (r = 0.63). Baseline albumin was 2.78 ± 0.44 g/dL, inversely related to recurrence (r = –0.39). After albumin optimization (>3.4 g/dL), the correlation disappeared (r = 0.02). Mean chest tube duration was 12.8 ± 7.3 days, hospital stay 4.6 ± 2.5 days, with a strong correlation between tube duration and recurrence (r = 0.67). Clinical control was achieved in 77%; pain (19.2%) and empyema (11.5%) were the main complications.

Conclusions: Talc pleurodesis offers effective palliation and significant symptomatic relief in refractory hepatic hydrothorax, especially where advanced therapies are inaccessible, improving quality of life for patients with end-stage liver disease.

Keywords: hepatic hydrothorax, talc pleurodesis, cirrhosis, palliative management, recurrence

Corresponding Author*: Zeeshan Sarwar, M.D. Department of Thoracic Surgery, Services Hospital, House 139, Block 4, Sector C-2, Green Town, Lahore, Punjab, Pakistan.
E-mail: zeeshan.sarwar195@gmail.com Phone: +92 3214347410
Doi: 10.26663/cts.2025.022
Received 31.10.2026 accepted 26.11.2026

Introduction

Hepatic hydrothorax (HH) is defined as the accumulation of pleural fluid in patients with liver cirrhosis in the absence of primary cardiac or pulmonary disease, and it represents a challenging complication of advanced hepatic failure. It is estimated to occur in approximately 5–10% of patients with cirrhosis and is associated with significant morbidity and mortality due to respiratory compromise and recurrent effusions [1,2]. The underlying pathophysiology involves the transdiaphragmatic movement of ascitic fluid through small defects in the diaphragm due to negative intrathoracic pressure and elevated intra-abdominal pressure [3,4].

Conservative management strategies such as sodium restriction, diuretics, and repeated thoracenteses are often insufficient in refractory cases [5]. Transjugular intrahepatic portosystemic shunt (TIPS) or liver transplantation are definitive options but are frequently unavailable or contraindicated due to comorbidities or poor hepatic reserve, especially in resource-limited settings [6,7]. For these patients, pleural interventions such as chemical pleurodesis have been explored as palliative or semi-definitive alternatives to control recurrent effusions [8].

Among sclerosing agents, talc pleurodesis remains the most widely accepted because of its efficacy, cost-effectiveness, and favorable safety profile when sterile, graded talc preparations (such as Steritalc®) are used [9,10]. However, the success rate of talc pleurodesis in hepatic hydrothorax has been variable, ranging from 11% to 72%, largely due to poor hepatic function, malnutrition, and persistent hypoalbuminemia preventing adequate pleural apposition [11,12]. Several studies have identified hypoalbuminemia as a strong predictor of pleurodesis failure, reflecting impaired reparative processes and ongoing transudation of fluid into the pleural cavity [13,14]. Therefore, pre-procedural optimization especially correction of serum albumin levels may play a pivotal role in improving pleurodesis outcomes in these patients [15].

In developing countries, where chronic liver disease is common and advanced therapeutic options remain limited, there is a need for simple, reproducible, and effective techniques for managing hepatic pleural effusions [16]. Our institutional experience has shown that normalization of serum albumin before pleurodesis, followed by complete therapeutic drainage and talc instillation, markedly enhances success rates and minimizes recurrence.

This study presents our five-year single-center experience (January 2020 to June 2025) evaluating outcomes of sterile, graded talc preparations, talc pleurodesis in hepatic pleural effusions. Our standardized protocol emphasizes albumin correction before the procedure, followed by therapeutic pleural tapping and talc pleurodesis. The albumin levels were maintained around 3.5g/dL during this whole procedure till the removal of chest tube post-procedure. The objectives of this study are to determine the overall success rate, identify predictors of failure, and assess the safety and efficacy of our albumin-optimized pleurodesis protocol in patients with hepatic hydrothorax.

Materials and Methods

Study Design and Setting

This was a retrospective observational review study conducted in the Department of Thoracic Surgery, Services Institute of Medical Sciences (SIMS), Services Hospital, Lahore, over a period of five and a half years (January 2020 to June 2025).

Study Population

Inclusion criteria: Patients aged ≥18 years presenting with pleural effusion secondary to hepatic failure (hepatic hydrothorax), confirmed clinically and radiologically, were included. Diagnosis of hepatic hydrothorax was based on: presence of liver cirrhosis and/or portal hypertension, absence of underlying primary pulmonary or cardiac disease, transudative pleural effusion on Light's criteria and complete drainage of pleural effusion before pleurodesis.

Exclusion criteria: Malignant or tuberculous pleural effusions: spontaneous bacterial empyema, spontaneous bacterial peritonitis, uncorrectable coagulopathy (INR > 2.5), patients having albumin of < 3.5 g/dL despite optimization, patients unfit for thoracic procedures and those who declined consent (Figure 1).

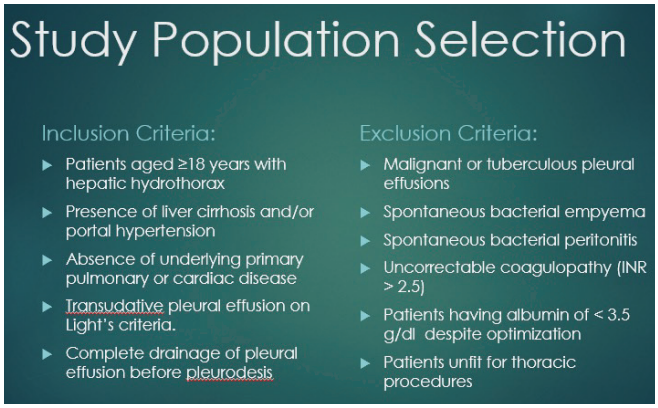

Figure 1. Flowchart demonstrating the selection of the study population based on inclusion and exclusion criteria.

Pre-Procedural Optimization

Serum albumin optimization followed a standardized protocol supervised by the hepatology team. Intravenous 20% human albumin was administered at 1 g/kg divided over 48–72 hours, followed by daily supplementation of 20–40 g/day depending on urine output, hemodynamics, and laboratory monitoring. Optimization continued until albumin was ≥3.5 g/dL on two consecutive days. Nutritional support included high-protein oral diet (1.2–1.5 g/kg/day) or enteral supplementation. Diuretics were titrated to achieve controlled negative fluid balance without worsening renal function.

Importantly, albumin levels were maintained within the optimized range (≥3.5 g/dL) for four weeks following talc pleurodesis to support pleural symphysis and minimize recurrence. Patients who failed to achieve the minimum optimization threshold (≥3.5 g/dL) prior to pleurodesis, or those whose serum albumin dropped below the optimized range during the four-week post-pleurodesis period, were excluded from the study analysis. Twelve patients initially failed to reach ≥3.5 g/dL and pleurodesis was postponed; all subsequently achieved optimization before proceeding with the procedure. No patient underwent pleurodesis without meeting the predefined albumin threshold.

Pleural Fluid Drainage and Talc Pleurodesis Technique

Once albumin levels were optimized, therapeutic pleural drainage was performed to evacuate the effusion completely. A 28–32 Fr intercostal tube was inserted under aseptic conditions and connected to underwater seal drainage.

When full lung re-expansion was confirmed on chest radiograph and daily drainage was <100 mL, talc pleurodesis was performed (3 g in sterile saline slurry). The talc slurry was instilled through the chest tube, which was then clamped for 2 hours.

After unclamping, the tube remained on underwater seal drainage until output was minimal and no radiological evidence of recurrence was seen. The tube was removed once pleural symphysis was confirmed clinically and radiographically.

Post-Procedural Care and Follow-Up

Patients were monitored for pain, fever, and dyspnea post-procedure. Antibiotics and analgesics were administered as required. Follow-up chest radiographs were obtained at 24 hours, one week, and one month post-procedure, and then at three-month intervals for up to six months. Pleurodesis success was defined as the absence of reaccumulation of pleural fluid on imaging and symptom resolution for ≥3 months post-procedure without repeat thoracentesis. Failure was defined as reaccumulation of effusion requiring further drainage or repeat pleurodesis.

This study was conducted as a retrospective review of routinely collected clinical data. The study was approved by the institutional ethics review board of Services Institute of Medical Sciences with reference number IRB/2025/1677/SIMS on 20.10.2025. As per institutional policy for retrospective studies with minimal risk, the requirement for individual informed consent was waived. All patient data were anonymized and handled confidentially in accordance with the Declaration of Helsinki and institutional guidelines to ensure protection of patient privacy.

Statistical Analysis

All data were analyzed using SPSS version 26. Quantitative variables (age, MELD score, serum albumin, chest tube duration, hospital stay) were expressed as mean ± SD with range, while categorical variables (gender, Child–Pugh class, etiology, recurrence, complications) were presented as frequencies and percentages. Pearson's correlation coefficient (r) was used to assess relationships between MELD score, Child–Pugh class, serum albumin, chest tube duration, and recurrence. For patients achieving post-optimization albumin >3.4 g/dL, the correlation with recurrence was recalculated to evaluate the effect of corrected hypoalbuminemia. All correlation coefficients were accompanied by two-tailed p-values, with significance set at $p < 0.05$. A multivariable logistic regression model was constructed to identify independent predictors of pleurodesis failure. Variables with $p < 0.10$ on univariate analysis (MELD score, Child–Pugh class, baseline albumin, chest tube duration) were included in the final model.

Results

A total of 52 patients who underwent talc pleurodesis for hepatic pleural effusion were included in the study. The mean age of the cohort was 61.2 ± 7.2 years (range: 45–73 years). There were 35 males (67.3%) and 17 females (32.7%). The predominant etiology of hepatic hydrothorax was hepatitis C infection (50/52; 96.2%), followed by alcohol-related liver disease (12/52; 23.1%) and hepatitis B infection (5/52; 9.6%). Several patients had dual etiologies, such as hepatitis C with alcohol use

disorder. Therefore, percentages exceed 100%. Etiologies were not mutually exclusive. Most patients were classified as Child–Pugh class C (43/52; 82.7%), indicating advanced hepatic dysfunction.

The mean MELD score was 15.2 ± 5.4 (range: 6–25). A strong positive correlation was observed between MELD score and Child–Pugh class (r = 0.67), suggesting that higher MELD values were associated with more severe hepatic impairment. MELD score also correlated positively with recurrence (r = 0.63), while a moderate correlation was noted between Child–Pugh class and recurrence (r = 0.50).

The mean baseline serum albumin was 2.78 ± 0.44 g/dL (range: 1.8–3.7 g/dL). After nutritional and medical optimization, post-procedure albumin levels were maintained at >3.4 g/dL in all patients. Baseline albumin demonstrated a moderate inverse correlation with recurrence (r = –0.39), indicating that patients with lower pre-procedure albumin levels were more likely to experience recurrent effusion. However, after optimization, this correlation became negligible (r = 0.02), suggesting that once hypoalbuminemia was corrected, recurrence was more closely linked to hepatic reserve rather than albumin level.

The mean chest tube duration was 12.8 ± 7.3 days (range: 3–30 days), and the mean hospital stay was 4.6 ± 2.5 days (range: 3–15 days). A strong positive correlation (r = 0.67) was observed between chest tube duration and recurrence, implying that patients requiring prolonged drainage were more likely to develop recurrence, likely due to persistent fluid production or incomplete pleural apposition.

The mean time to recurrence after a single session of pleurodesis was 5.0 ± 2.4 days (range: 3–8 days). Twenty-two (42.3%) patients achieved complete resolution with a single pleurodesis session, 15 (28.8%) required two sessions, and 3 (5.7%) required three sessions. Twelve (23%) patients experienced pleurodesis failure with persistent effusions. Overall, final clinical control of pleural effusion was achieved in 40 patients (77%), while 12 patients (23%) experienced recurrence or died during follow-up.

On multivariable logistic regression, MELD score (p = 0.01) and chest tube duration (p = 0.03) were independent predictors of recurrence, while post-optimization albumin was not statistically significant.

Complications were noted in several patients, with pain being the most frequent (10 patients; 19.2%), followed by fever (2 patients; 3.8%). Empyema developed in 6 patients (11.5%), all within the subgroup experiencing pleurodesis failure. Five patients (9.6%) died during follow-up. Four deaths occurred within 30 days, primarily due to progressive hepatic failure (n = 3) and sepsis unrelated to empyema (n = 1). One late death (after 30 days) resulted from variceal bleeding.

Table 1. Baseline demographic and clinical characteristics.

Variable	N (%) or Mean ± SD	Range
Total Patients	52	—
Age (Years)	61.2 ± 7.2	45–73
Gender		
Male	35 (67.3%)	—
Female	17 (32.7%)	—
Etiology		
Hepatitis C	50 (96.2%)	—
Hepatitis B	5 (9.6%)	—
Alcoholic liver disease	12 (23.1%)	—
Child–pugh category		
Class A	0 (0%)	—
Class B	9 (17.3%)	—
Class C	43 (82.7%)	—
MELD score	15.2 ± 5.4	6–25
Baseline albumin (g/dL)	2.78 ± 0.44	1.8–3.7
Chest tube duration (days)	12.8 ± 7.3	3–30
Hospital stay (days)	4.6 ± 2.5	3–15

Table 2. Correlation analysis between clinical parameters and recurrence.

Variables Compared	Correlation coefficient (r)	Interpretation	p-value
MELD vs child–pugh class	0.67	Strong positive	< 0.001
MELD vs recurrence	0.63	Moderate–strong positive	< 0.05
Child–pugh vs recurrence	0.50	Moderate positive	< 0.05
Baseline albumin vs recurrence	–0.39	Moderate negative	< 0.05
Post-optimization albumin vs recurrence	0.02	No correlation	0.91
Chest tube duration vs recurrence	0.67	Strong positive	< 0.05

Table 3. Procedural outcomes and complications.	
Variable	n (%)
Outcome	
Complete control after 1 session	22 (42.3%)
Two sessions required	15 (28.8%)
Three sessions required	3 (5.7%)
Pleurodesis failure	12 (23.0%)
Overall clinical control achieved	40 (77.0%)
Complications	
Pain	10 (19.2%)
Fever	2 (3.8%)
Empyema	6 (11.5%)
Mortality	5 (9.6%)

In summary, talc pleurodesis provided effective and sustained control of hepatic pleural effusion in approximately three-quarters of patients, though recurrence and complication rates remained considerable. Neither age nor sex significantly influenced pleurodesis success.

Discussion

In this study of 52 patients with hepatic hydrothorax secondary to advanced cirrhosis, talc pleurodesis provided effective palliation in a majority of cases, with 77% achieving control of pleural effusion and improvement in dyspnea. The mean MELD score was 15.2 ± 5.4, and 82.7% of patients were Child–Pugh class C, representing an advanced hepatic disease cohort. The correlation analysis demonstrated that higher MELD and Child–Pugh scores were associated with recurrence, emphasizing the impact of hepatic reserve on pleurodesis success.

The success rate observed in this series aligns with international experience, where reported control rates range between 70% and 80% following talc pleurodesis for hepatic hydrothorax [17-19]. A success rate of 73% was reported using video-assisted thoracoscopic pleurodesis, while other studies have documented efficacy between 65% and 79% in similar populations [8,20]. These findings indicate that, even in resource-limited centers where TIPS and liver transplantation are not routinely available, comparable outcomes can be achieved with meticulous patient selection and optimization.

The complication rate in the present series was approximately 23%, with pain being the most common adverse effect (19%), followed by fever and empyema (3.8% and 11.5%, respectively). This complication profile is consistent with other published data, where pain and transient fever are frequent but manageable events, and serious infections occur in up to 10–20% of patients [3]. Despite these complications, talc pleurodesis remains considerably safer than repeated large-volume thoracentesis, which carries risks of pneumothorax, infection, and protein loss in patients with poor hepatic synthetic function.

The mean chest tube duration was 12.8 ± 7.3 days, and longer drainage was significantly associated with recurrence ($r = 0.67$). Similar associations have been documented, where early tube removal after successful pleural symphysis reduced recurrence risk [21].

Serum albumin levels also demonstrated prognostic relevance. Patients with lower baseline albumin showed higher recurrence rates ($r = –0.39$), consistent with the role of hypoalbuminemia in maintaining negative oncotic pressure and facilitating effusion reaccumulation [18,22]. After optimization, when albumin was maintained above 3.4 g/dL, this association disappeared, suggesting that correction of nutritional and volume status improves pleurodesis success. Albumin optimization was associated with reduced recurrence, although causality cannot be conclusively established.

Importantly, the study highlights the role of talc pleurodesis in patients with end-stage liver disease, particularly in regions where definitive options are either not readily available or unaffordable. Hepatic hydrothorax severely compromises quality of life due to dyspnea and recurrent fluid accumulation. The present experience demonstrates that pleurodesis provides meaningful symptomatic relief, reduces the need for repeated hospital admissions, and allows earlier discharge (mean stay 4.6 ± 2.5 days). Talc pleurodesis appeared to improve symptoms, thereby improving both physical comfort and psychosocial well-being [17,18,22]. In this context, pleurodesis serves as a humane, cost-effective, and clinically justified option to address refractory symptoms in patients otherwise left without curative options.

While the procedure's long-term survival benefit remains limited by underlying liver failure, its role as a symptom-directed intervention is significant. The re-

sults also suggest that recurrence is more closely related to the degree of hepatic decompensation than to procedural inadequacy. Therefore, talc pleurodesis should be considered part of comprehensive care for cirrhotic patients with hydrothorax, complementing diuretics, albumin therapy, and controlled sodium intake. The study's strengths include its focus on real-world data and the demonstration of achievable outcomes without reliance on high-cost technologies.

Limitations of the Study

This study has certain limitations inherent to its single-center, retrospective observational design. The sample size was relatively small, which may limit the statistical power to generalize the findings to broader populations. Patients were not randomized, and the choice of management relied partly on clinical judgment and patient condition, introducing potential selection bias. Additionally, long-term follow-up was limited in some cases due to poor compliance or mortality related to underlying hepatic dysfunction. Advanced hemodynamic parameters such as portal pressure gradient or detailed nutritional status were not routinely measured, which could have provided more comprehensive insight into predictors of recurrence.

In conclusion, talc pleurodesis is a safe, effective, and cost-efficient palliative option for patients with refractory hepatic hydrothorax, particularly in regions where liver transplantation or transjugular intrahepatic portosystemic shunt (TIPS) is scarce. The procedure successfully controlled recurrent pleural effusion in a majority of patients and significantly improved dyspnea and overall comfort, enhancing quality of life despite advanced liver disease. Although recurrence was observed in some patients with poor liver function, the symptomatic relief achieved was clinically meaningful. In the context of developing healthcare systems, this simple intervention can serve as an important palliative strategy for end-stage liver disease patients unfit for definitive surgical options. Larger multicentric studies with longer follow-up are warranted to better define prognostic indicators and optimize patient selection for talc pleurodesis in hepatic hydrothorax.

Declaration of conflicting interests

The authors declared no conflicts of interest with respect to the authorship and/or publication of this article.

Funding

The authors received no financial support for the research and/or authorship of this article.

Ethics approval

The study was approved by the institutional ethics review board of Services Institute of Medical Sciences with reference number IRB/2025/1677/SIMS on 20.10.2025.

Authors' contribution

MSN: Conceptualization, Methodology, Writing - original draft. ZS: Data curation, Formal analysis, Writing - review & editing.

References

1. Garbuzenko DV, Arefyev NO. Hepatic hydrothorax: An update and review of the literature. World J Hepatol 2017; 9: 1197-204.
2. Roussos A, Philippou N, Mantzaris GJ, Gourgouliannis KI. Hepatic hydrothorax: pathophysiology diagnosis and management. J Gastroenterol Hepatol 2007; 22: 1388-93.
3. Singh A, Bajwa A, Shujaat A. Evidence-based review of the management of hepatic hydrothorax. Respiration 2013; 86: 155-73.
4. Krok KL. Hepatic hydrothorax: Current concepts. Clin Liver Dis (Hoboken) 2014; 4: 35-7.
5. Pippard B, Bhatnagar M, McNeill L, Donnelly M, Frew K, et al. Hepatic Hydrothorax: A Narrative Review. Pulm Ther 2022; 8: 241-54.
6. Ismail A, Awadalla M, Pothuraju S, Singal AK. Hepatic Hydrothorax: A Review. Curr Hepatol Rep 2025; 24: 10.
7. Matei D, Craciun R, Crisan D, Procopet B, Mocan T, Pasca S et al. Hepatic Hydrothorax-An Independent Decompensating Event Associated with Long-Term Mortality in Patients with Cirrhosis. J Clin Med 2021; 10: 3688.
8. Lee WJ, Kim HJ, Park JH, Park DI, Cho YK, Sohn CI et al. Chemical pleurodesis for the management of refractory hepatic hydrothorax in patients with decompensated liver cirrhosis. Korean J Hepatol 2011; 17: 292-8.
9. Baiu I, Yevudza E, Shrager JB. Talc Pleurodesis: A Medical, Medicolegal, and Socioeconomic Review. Ann Thorac Surg 2020; 109: 1294-301.

10. Xia H, Wang XJ, Zhou Q, Shi HZ, Tong ZH. Efficacy and safety of talc pleurodesis for malignant pleural effusion: a meta-analysis. PLoS One 2014;9:e87060.

11. Farooq S, Armin S, Killingsworth JE, Agrawal A, Rao A, Estrada-Y-Martin RM, Cherian SV. Predictors for spontaneous pleurodesis in patients with indwelling pleural catheters for malignant pleural effusion: a safety net hospital experience. Ther Adv Respir Dis 2025; 19: 17534666251318844.

12. Williams JG, Lerner AD. Managing complications of pleural procedures. J Thorac Dis 2021; 13: 5242-50.

13. Ford A, Jennings S, Tharion J. Low serum albumin as a predictor of poor outcome in pleurodesis for malignant pleural effusion. Heart Lung Circ 2015; 24: e9.

14. Alonso JC. Pleural effusion in liver disease. Semin Respir Crit Care Med 2010; 31: 698-705.

15. Kaddah S, Helmy N, Akl Y, Abd El Hafez H, El Makhzangy H. Chemical pleurodesis in patients with hepatic hydrothorax: management, morbidity and mortality. Egypt J Chest Dis Tuberc 2018; 67: 372-7.

16. Salim A, Farooq MO, Saleem S, Malik K. Financial burden and social implications of chronic liver disease in a patient population group in Pakistan. Pak J Med Sci 2024; 40: 1503-8.

17. Milanez de Campos JR, Filho LO, de Campos Werebe E, Sette H Jr, Fernandez A, Filomeno LT, Jatene FB. Thoracoscopy and talc poudrage in the management of hepatic hydrothorax. Chest 2000; 118:1 3-7.

18. Takayama T, Kurokawa Y, Kaiwa Y, Ansai M, Chiba T, et al. A new technique of thoracoscopic pleurodesis for refractory hepatic hydrothorax. Surg Endosc 2004; 18: 140-3.

19. Rahim Y, Reddy RV, Naeem M, Tsaknis G. Medical thoracoscopy with talc pleurodesis for refractory hepatic hydrothorax: A case series of three successes. Respir Med Case Rep 2024; 50: 102039.

20. Badillo R, Rockey DC. Hepatic hydrothorax: clinical features, management, and outcomes in 77 patients and review of the literature. Medicine (Baltimore) 2014; 93: 135-42.

21. Wilkins H, Britt E, Bhatnagar M, Pippard B. Hepatic hydrothorax. J Thorac Dis 2024; 16: 1662-73.

22. Ma B, Shang T, Huang J, Tu Z, Wang Y, Chen J, Han Y et al. The impact and role of hepatic hydrothorax in the prognosis of patients with decompensated cirrhosis: A retrospective propensity score-matched study. Front Med 2022; 9: 904414.

This article is an open access article distributed under the terms and conditions of the Creative Commons Attribution (CC BY) license (http://creativecommons.org/licenses/by/4.0/).

To cite this article: Unal ME, Akcam TI, Uysal FE, Ergonul AG, Ozdil A, Turhan K Gurgun A, Ulker M, Cakan A, Cagirici U. Impact of preoperative pulmonary rehabilitation on postoperative outcomes in patients undergoing lung cancer surgery. Curr Thorac Surg 2025;10(3):131-138.

Original Article

Impact of preoperative pulmonary rehabilitation on postoperative outcomes in patients undergoing lung cancer surgery

Merve Ezgi Unal[1], Tevfik İlker Akcam[2], Funda Elmas Uysal[3], Ayse Gul Ergonul[2], Ali Ozdil[2], Kutsal Turhan[2], Alev Gurgun[3], Melike Ülker[4]*, Alpaslan Cakan[2], Ufuk Cagirici[2]

[1]Department of Thoracic Surgery, Nevsehir City Hospital, Nevsehir, Türkiye
[2]Department of Thoracic Surgery, School of Medicine, Ege University, İzmir, Türkiye
[3]Department of Chest Diseases, School of Medicine, Ege University, İzmir, Türkiye
[4]Department of Thoracic Surgery, Avrasya Hospital, Istanbul, Türkiye

ABSTRACT

Background: In this study, it was planned to improve the respiratory and metabolic capacities of patients who will be operated for lung cancer in the preoperative period. Thus, the effect of preoperative pulmonary rehabilitation (PPR) on postoperative morbidity / mortality rates and the duration of hospital stay was investigated.

Materials and Methods: Between July 2020 and February 2021, 43 patients who were operated for lung cancer were evaluated prospectively. Group I (n = 20) patients were included in the PPR program for 2 weeks preoperatively. PPR was not applied to the control group, Group II (n = 23) patients. Demographic findings of the cases, postoperative length of stay and drain duration, postoperative complication development were compared.

Results: The mean age of Group I was 63.60 ± 5.87 (54-75), while that of Group II was 60.78 ± 13.30 (32-83). Surgical mortality was not observed in any patient. While morbidity was observed in 7 (35%) patients in Group I and 13 (65%) patients in Group II (p = 0.158). The postoperative hospital stay of Group I was found to be statistically significantly lower than Group II (p = 0.026). It was determined that the drain stay time of Group I patients was shorter than Group II (p = 0.009).

Conclusion: It was seen that the importance of preoperative pulmonary rehabilitation was high in achieving less complications and shorter hospital stay in the postoperative period in patients who underwent pulmonary rehabilitation due to lung cancer surgery.

Keywords: lung surgery, non-small cell lung cancer, pulmonary rehabilitation, morbidity

Corresponding Author*: Melike Ülker, M.D. Department of Thoracic Surgery, Avrasya Hospital, Istanbul, Türkiye.
E-mail: melike.ulker@hotmail.com
Doi: 10.26663/cts.2025.023
Received 13.10.2025 accepted 02.12.2025

Introduction

Lung cancer is the second most common type of malignancy worldwide and one of the leading causes of cancer-related mortality. Lung cancer creates an important burden of disease on society and the economy is seriously affected by this burden [1]. Surgical resection, because of its chance of curability, has higher survival rates compared to all other treatment methods. However, it can be related to significant morbidity, functional losses and a decrease in the quality of life [2,3]. Despite the preoperative examinations, complications may occur during the postoperative period, hence the length of hospitalization may be prolonged. For this reason, studies on this subject suggest that preoperative pulmonary rehabilitation (PPR) programs together with exercise, can improve the exercise capacity, functional performance, and quality of life, both before and after the operation [2-5]. PPR is a comprehensive intervention that includes, exercise training (durability and resistance) and behavioral changes for the patient [6,7]. It is known that patients with low exercise tolerance have worse outcomes of thoracic surgery morbidity/mortality compared to other patient groups [8]. Therefore, it is hoped that PPR can decrease postoperative complications and morbidity, shorten the length of hospitalization, and reduce healthcare costs [8].

This study aimed to show the increase the metabolic and respiratory capacities of patients in the preoperative period with PPR, thus it is planned to increase the tolerability of surgical procedures, having less complications in the postoperative period and shorter length of hospital stay.

Materials and Methods

Between the dates of July 2020 and February 2021, patients who were operated on because of non-small cell lung cancer (NSCLC) were included in the evaluation. Randomization is achieved by coin flipping between the eligible patients who applied to the outpatient clinic to be included in the study and control groups. The patients who cannot do physical exercise due to comorbidity, who will be operated on because of benign pathology or metastatic lung disease, who have a history of cardiac operation and also patients with history of orthopedic operation with a prosthesis, and recent history of major surgery because of other reasons are excluded in the study. Patients who completed a PPR program that matches the criteria are included in the study.

All patients included in the study completed their preoperative diagnostic and evaluation procedures at the Ege University Faculty of Medicine, and the surgical interventions were likewise performed in the same institution, ensuring consistency in preoperative assessment, perioperative management, and postoperative follow-up within a standardized institutional setting.

Group I patients, which is the study group, were additionally included in a pulmonary rehabilitation program, before the operation for 2 weeks. The method of randomization was based on selecting individuals who, within the study period, had no contraindications for the Pulmonary Rehabilitation (PR) program and expressed willingness to participate. Group II patients, which is the control group, were operated on without any additional application, with routine preoperative preparations. 20 patients for Group I, 23 patients for Group II were included in this prospective study. The age, sex, comorbidity, technique of surgical procedure, figures of forced expiratory volume in one second (FEV1) before the pulmonary rehabilitation (PR), figures of arterial blood gases before the PR, postoperative length of hospitalization, surgical diagnosis, postoperative complications, the length of tube thoracostomy treatment, smoking history and postoperative early period mortality of total 43 patients were researched.

Patients of both groups were evaluated by the blood biochemistry, electrocardiogram (ECG), respiratory function test, posteroanterior and lateral chest x-ray, thorax CT. When required, PET/CT and MRI evaluations were done. For the diagnosis, one or more of following techniques were used; sputum cytology, transthoracic fine-needle aspiration biopsy (TTFNAB), evaluation with bronchoscopy (lavage, bronchial brushing, biopsy). The staging of the cases were done according to the 'International Association for the Study of Lung Cancer (IASLC)''s 2017 international lung cancer classification. Histopathologic typing was determined according to World Health Organisation's 2015 classification.

In scope of the study, 20 patients that were willing to participate in the program and who did not have any contraindications for pulmonary rehabilitation, were subjected to bronchial hygiene methods, exercise techniques (respiratory, aerobic, stretching, and relaxation exercises) and information that could be applied to the daily life were given one time during the program. At the preoperative period, the Group I cases were included in a pulmonary rehabilitation program that consisted exercises of joint range, aerobic (walking and spinning), strengthening (forced stretching movements, weight training, etc.), re-

spiratory (forced inhalation and exhalation that strengths the respiratory muscles), relaxation and stretching to be practiced by the physicians, physiotherapists, and technicians who were trained about this subject and all rehab program to be completed at the pulmonary rehabilitation unit for 2 weeks, 5 days a week, 1.5 hours in a day. Cases were also asked to do an exercise program once a week at home. Joint range exercise consisted of 10 rep of neck, waist, upper, and lower body extremities joint exercises which were done before the aerobic exercise. Aerobic exercise was done for 30 minutes total, 15 minutes treadmill, and 15 minutes spinning. It was performed to reach 60-70% of VO2max and 60-70% of heart rate reserve, as moderate-intensity exercise. 23 cases in Group II, did not have any rehabilitation before the operation and these cases formed the control group.

Complications were classified as prolonged air leak, subcutaneous emphysema, pneumonia, atelectasis requiring bronchoscopy, postoperative expansion defect, pulmonary embolism, blood product transfusion, intraoperative bleeding, postoperative hemorrhage, arrhythmia, and metabolic disorder.

The ethical approval for this study was obtained from the Ethics Committee of Medical Research at Ege University in 06/2020 (Approval No: 20-6T/50).

Statistical Analysis

Statistical analyses were done by using the '' Statistical Package for Social Sciences (SPSS) '' 24.0 program. Categorical data was stated as numbers and percentages. Numerical data was stated as average ± standard deviation and normal (minimum-maximum). The normality control of the numerical variables in the groups was done with the ''Shapiro-Wilk test''. For the comparison of numerical variables in groups, '' The Independent t-test and Mann-Whitney U test'' were used. ''The K-square test'' was used for the comparison of categorical variables in groups. A p-value less than 0.05 was defined as statistical significance.

Results

The mean age of Group I (study group) was 63.60 ± 5.87 (54-75) and the number of female patients' were 4 (20%). Right upper lobectomy was performed on 5 patients, right lower lobectomy on 4 patients, segmentectomy on 3 patients, middle lobectomy on 2 patients, left upper lobectomy on 2 patients, left lower lobectomy on 2 patients, left pneumonectomy on 1 patient, and wedge resection on 1 patient. While 5 (25%) of these procedures were performed videothoracoscopically, 15 (75%) patients underwent lateral thoracotomy. It was detected that 11 (55%) of the patients were diagnosed with squamous cell carcinoma, 8 (%40) with adenocarcinoma, 1 (5%) with adenosquamous carcinoma. 16 (80%) of the patients had co-morbid illnesses. 9 (45%) of the patients did not have a history of smoking (Table 1). While no mortality was observed on any patient in the post-operation early period, one of the patients underwent revision due to hemorrhage. Morbidity (prolonged air drainage on 5 patients, increased urea-creatinine levels on 1 patient, and hemorrhage on 1 patient) was detected on 7 (35%) patients.

The mean age of Group II (control group) was 60.78 ± 13.30 (32-83) and the group consisted of 18 (78%) male, 5 (22%) female patients. Right upper lobectomy was performed on 7 patients, left upper lobectomy on 6 patients, left lower lobectomy on 4 patients, right lower lobectomy on 3 patients, middle lobectomy on 1 patient, superior bilobectomy on 1 patient, and left pneumonectomy on 1 patient. While 3 (13%) of these procedures were performed videothoracoscopically, 20 (87%) patients underwent lateral thoracotomy. Nine (%39) of the patients got diagnosed with squamous cell carcinoma, 8 (%35) with adenocarcinoma, 3 (13%) with an atypical carcinoid tumor, and 1 each (4.3%) with large cell neuroendocrine carcinoma, lymphoepithelioma-like carcinoma, and large cell carcinoma. Fifteen (65%) of the patients had co-morbid illnesses. Seven (65%) of the patients in Group II did not have a history of smoking. In the early post-operative period, while no mortality was observed on any patient, morbidity (prolonged air drainage in 10 patients, increased urea-creatinine levels in 1 patient, pulmonary embolism in 1 patient, pneumonia in 1 patient, subcutaneous emphysema in 1 patient and sinus bradycardia in 1 patient) were detected in 13 (65%) patients. In the evaluation of normality of numerical variables between groups, age, preoperative values of FEV1 ''liter'' and ''%'', preoperative values of PO2 and PCO2 in arterial blood gases did demonstrate a similar distribution between groups (Table 2).

In the pre-PR measurements of cases, Group I's average FEV1 ml and % values were 2340 ± 691 (760-3630) ml and 82.2 ± 21.2 % (40-114), Group II's 2648 ± 763 (1230-4130) ml and 92.3 ± 16.8 % (52-117) as resulted in (for ml $p = 0.176$, for % $p = 0.088$) (Table 2).

According to pre-PR arterial blood gases measurement results, Group I's cases average PaO2 (mmHg) value was 87.8 ± 12.8 (59-110), PaCO2 value was 37.5 ± 4.8 (28.4-47.5) and oxygen saturation value was 97.6

(92-99). In Group II's cases the average PaO2 (mmHg) value was 97.7 ± 23 (60-166), PaCO2 value was 37.4 ± 3.8 (31.1-47.1), and oxygen saturation value was 98.1 (93.9-99.7). There was no statistical difference between the two groups (p; 0.096, 0.990, 0.122) (Table 2).

When we evaluate the post-operative hospitalization length of stay, while Group I's results were average 5.6 ± 1.8 (2-9)/day, Group II's results were found to be 8.35 ± 5.76 (3-27)/day. When comparing groups, there was a statistically significant difference between them (p = 0.026) (Figure 1) (Table 3).

The length of tube thoracostomy treatment in the post-operative period was compared. While Group I's results were average 5 ± 3.5 (2-18)/day, Group II's results were 8.7 ± 5.9 (3-24)/day. The difference between groups was statistically significant (p = 0.009) (Figure 2) (Table 3).

When the complication development status in the postoperative early period was evaluated, 7 (35%) cases in Group I and 13 (56.5%) cases in Group II postoperative morbidity were detected. Although there was a difference between groups, the difference was not statistically significant. (p = 0.158) (Table 4).

Table 1. Demographic and clinical characteristics.

	Group I (N=20)	Group II (N=23)	P-value
Gender			0.889
Female	4 (20%)	5 (22%)	
Male	16 (80%)	18 (78%)	
Age (avg., range, year)	63.6 (54-75)	60.8 (32-83)	0.366
Comorbidity			0.281
Present	16 (80%)	15 (65%)	
Absent	4 (20%)	8 (35%)	
Surgical technique			0.315
Thoracotomy	15 (75%)	20 (87%)	
VATS	5 (25%)	3 (13%)	
Histopathological diagnosis			0.167
Adenocarcinoma	8 (40%)	8 (35%)	
Squamous cell carcinoma	11 (55%)	9 (39%)	
Other	1 (5%)	6 (26%)	
Smoking			0.053
Present	11 (55%)	6 (35%)	
Absent	9 (45%)	17 (65%)	

Abbrev.: VATS: video-assisted thoracic surgery; Avg.: Average.

Table 2. Preoperative respiratory function parameters.

	Grup I (N=20) Avg. (interval)	Grup II (N=23) Avg. (interval)	P-value
FEV1 (L) [before PR]	2.3 (0.76-3.6)	2.6 (1.2-4.1)	0.176
FEV1 % [before PR]	82.2 (40-114)	92.4 (52-117)	0.088
Preop. PaO2 (mmHg)	87.8 (59-110)	97.7 (61-166)	0.096
Preop. PaCO2 (mmHg)	37.5 (28-47)	37.4 (31-47)	0.990
Preop. saturation	97.6 (92-99)	98.1 (93.9-99.7)	0.122

Abbrev.: FEV1 : forced expiratory volume in one second, L : liter, PR : pulmonary rehabilitation, Preop: preoperative, Avg. : Average

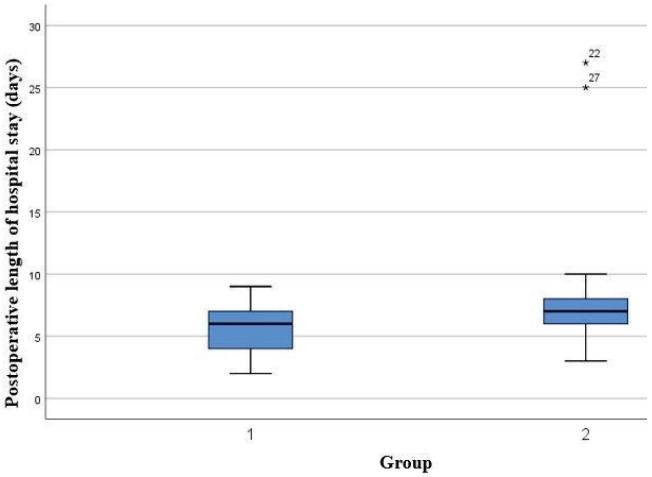

Figure 1. Postoperative length of hospital stay.

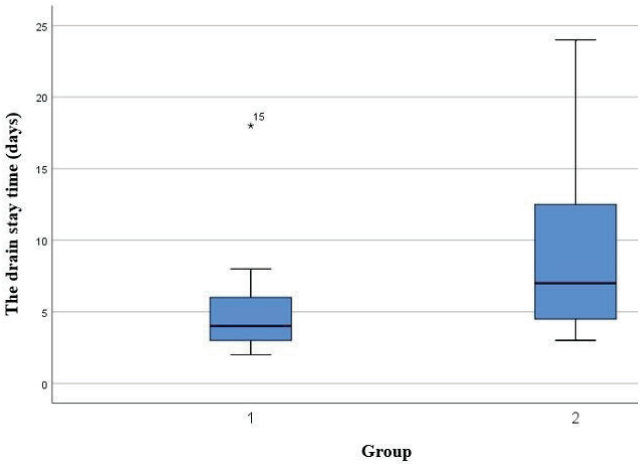

Figure 2. Duration of chest tube drainage.

Table 3. Comparison of postoperative hospitalization and tube thoracostomy duration.

	Grup	n	Average	Standard deviation	Min.	Max.	P value
Postoperative duration of hospitalization (day)	I	20	5.60	1.88	2	9	0.026
	II	23	8.35	5.77	3	27	
	Total	43	7.07	4.57	2	27	
Postoperative duration of tube thoracostomy (day)	I	20	5.00	3.54	2	18	0.009
	II	23	8.70	5.99	3	24	
	Total	43	6.98	5.29	2	24	

Table 4. Distribution of postoperative mortality-morbidity-revision according to the groups.

Grup	Postoperative morbidity		Total	P value
	Present	Absent		
I (n, %)	7, 35%	13, 65%	20, 100%	0.158
II (n, %)	13, 56.5%	10, 43.5%	23, 100%	
Total	20, 46.5%	23, 53.5%	43, 100%	
Grup	Revision		Total	P value
	Present	Not present		
I (n, %)	1, 5%	19, 95%	20, 100%	0.278
II (n, %)	0, 0%	23, 100%	23, 100%	
Total	1, 2.3%	42, 97.7%	43, 100%	
Grup	Mortality (first 1 month)		Total	P value
	Present	Not present		
I (n, %)	0, 0%	20, 100%	20, 100%	
II (n, %)	0, 0%	23, 100%	23, 100%	
Total	0, 0%	43, 100%	43, 100%	

Discussion

It is predicted that the number of patients who will be operated on for early-stage lung cancer will increase with the improvement in lung cancer awareness and developments in imaging methods in recent years. Postoperative complication and mortality risk after lung resection represent significant limitation for surgical treatment of lung cancer. For this reason, there can be potential of decreasing the postoperative risk and hospitalization length by managing the modifiable risk factors, at the same time, it is hoped that it will have a positive effect on health care costs [9]. Many studies in the literature indicate that the practice of pulmonary rehabilitation decreases postoperative morbidity in colorectal, heart, and spinal surgeries [10]. The results of these studies, collected under the name of ERAS: Enhanced Recovery After Surgery, in the specialty fields like colorectal surgery and examined in detail. In the aim of accelerating the recovery, it is planned to restore the postoperative organ dysfunction. With the practice of many evidence-based preoperative measures, serious results have been achieved. In conclusion, the information of decrease in the hospitalization lengths and postoperative complication rates were attained [11]. In general, ERAS interventions in thoracic surgery are divided into preoperative, intraoperative, and postoperative periods. In the preoperative period, nutritional evaluation and support, correction of the anemia and smoking cessation are the leading factors. The intraoperative period focused on minimally invasive surgery (VATS) with optimal analgesic technique, when possible. In the postoperative period, the main goals are the management of pain, early mobilization, early oral intake, and prevention of nausea and vomiting. However, it has been stated that improvement of patients' pulmonary function and exercise capacity may reduce the risk of complication [12].

In the light of all these examples and suggestions, it is encouraging to research the role of PPR in the patients who will undergo pulmonary resection. The hypothesis regarding the effect of PPR is such that, if the existing respiratory functions of the patients are improved in the preoperative evaluation, postoperative complications and mortality can be reduced. In this prospective study, we researched the PPR's effect on the tolerability of surgery, postoperative morbidity/mortality ratio and hospitalization length by planning to improve preoperative respiratory and metabolic capacities of the patients who will be operated on due to lung cancer. Although there is no consensus on the duration of preoperative pulmonary rehabilitation in many studies based on this hypothesis in the literature, the durations have been found to range from one day to four weeks before the operation [13]. Divisi et al [14] observed a monotypic group of 27 patients with a diagnosis of COPD and NSCLC in their studies and performed lobectomy after subjecting all the patients to a 4 week of PPR program. Likewise, Sekine et al [15] evaluate the effect of a 2-week program of PPR on patients who underwent a lobectomy and showed that PPR decreases the length of hospitalization. In a study, Yanez-Brage et al [16] evaluated the postoperative pulmonary complications in patients who underwent coronary artery bypass graft surgery. It has been stated that 1 day of preoperative physiotherapy can significantly reduce the atelectasis. Hulzebos et al [17] applied 2 weeks of inspiratory muscle exercises to the 140 patients out of 279 who underwent elective coronary artery bypass graft surgery and show that postoperative pulmonary complications were significantly reduced. In the light of these examples in literature, we planned a 2 week of pulmonary rehabilitation program similar to previous studies, considering the oncological waiting times.

The studies have shown that PPR is safe for resectable lung cancer patients, improves the results of respiratory function test and cardiopulmonary exercise test [18]. However, these development's effect on postoperative complications and mortality has not been clear. It was thought that reasons such as clinical trials have failed to show the statistically significant difference, not randomizing, patient selection or short-term PPR practice reveal these results. The low number of patients included in the study and other limitations prevent the generalization of results.

In the study done by Benzo et al [19], it is shown that randomly selected patients with the diagnosis of COPD and NSCLC, for the preoperative exercise therapy program who underwent lung resection, had a shorter duration of postoperative tube thoracostomy treatment (4.3 days in comparing to 8.8 in the control group, $p = 0.04$) and also it is shown the incidence of long duration of tube thoracostomy (>7 days) is lower (11% against 63%, $p = 0.03$) comparing to the control group. In addition, the patients in the preoperative exercise therapy arm of the study were found to have shorter hospital stays which was almost significant. For the postoperative pulmonary complication incidence, no significant difference (patients who need bronchoscopy due to respiratory failure, pneumonia, atelectasis, $p = 0.45$ (for every 3 outcome criteria)) was found [19].

The study carried by Bobbie et al [20], includes 11 cases (monotypic group) operated on between 2004-2006 due to NSCLC and underwent 4 weeks of preoperative pulmonary rehabilitation. Although the study has found that significantly meaningful improvement of 2.8mL/kg/min at VO2max values and is one of the first studies that practiced PPR. It was insufficient to produce meaningful results due to the lack of a control group.

Morano et al [20] have reported that the patients who are in the preoperative exercise program have spent fewer days (7.8 ± 4.8 against 12.2 ± 3.6 days, $p = 0.04$) at the hospital (comparing to the control group), keeping the chest tube fewer days (4.5 ± 2.9 against 7.4 ± 2.6 days, $p = 0.03$) and lower incidence of postoperative pulmonary complications (16.7% against 77.8%, $p = 0.01$).

The case-control study done by Varela et al [21] has emphasized that the mortality in the preoperative exercise group was lower compared to the control group. It was reported that the rates of pneumonia and atelectasis were found to be higher in the control group, but only the difference in atelectasis rates was significant. The mean hospital length of stay was found to be significantly less in the preoperative exercise therapy group.

Gao et al [22] published a study of 142 high-risk patients with potentially resectable lung cancer in 2015. The patients were non-randomly allocated to the study group (71 patients) who underwent a preoperative pulmonary rehabilitation program followed by lobectomy, and to

the control group who underwent only lobectomy with conventional treatment, and the postoperative complication rate in the study group was found to be significantly lower than in the control group. While the postoperative hospital length of stay was significantly longer in the control group, there was no difference between the two groups in terms of the analysis of the average cost in the hospital, including the cost of pulmonary rehabilitation.

In a randomized clinical trial conducted by Licker et al [18] in 2017; 25-day PPR was applied to 74 out of 151 lung cancer patients who were to undergo elective surgery and the results compared with the control group of 77 cases. When the VO2max and six-minute walk test results were compared between the two groups, in the PPR group; a statistically significant 15% increase was found for both values. An 8% decrease in VO2max was observed in the control group, and there was no statistical difference in postoperative complications (or hospital stay) between the groups.

In our prospective study researching the effectiveness of the pulmonary rehabilitation (PR) program applied for 2 weeks before the operation in patients with NSCLC who were planned pulmonary resection, it was shown that PPR caused a statistically significant decrease in postoperative hospitalization time and chest tube treatment time ($p < 0.05$).

Limitations of the study

There are several limitations of our study that should be considered when evaluating the results. One of these limitations is, we had to carry out this prospective study during the Covid-19 pandemic, which resulted with lower number of cases. Although there were fewer complications in the PPR group, no statistically significant difference was observed, possibly due to limited number of cases. As we mentioned before, the effect of PPR on postoperative complications and mortality could not found to be statistically significant in many studies, similar to our study in the literature [18,19,21]. Another limitation was that the VATS procedure alone can reduce postoperative pulmonary complications and mean hospital stay, and thus affecting the outcomes. It is thought that the interaction between VATS/thoracotomy surgical procedure type and pulmonary rehabilitation should be investigated with a further study. Our results require confirmation with a larger and possibly multicenter study.

In conclusion, our findings suggest, short-term pulmonary rehabilitation has positive effects on pulmonary functions, inspiratory muscle strength, exercise capacity, and dyspnea in patients with lung cancer. We think, the positive effects of preoperative pulmonary rehabilitation emerged objectively in our study. We see this rehabilitation program as effective management of pulmonary rehabilitation in the perioperative period in our cases, in which we observed significant improvement of lung function, exercise capacity and quality of life.

Declaration of conflicting interests

The authors declared no conflicts of interest with respect to the authorship and/or publication of this article.

Funding

The authors received no financial support for the research and/or authorship of this article.

Ethics approval

The ethical approval for this study was obtained from the Ege University Ethics Committee of Medical Research at 06/2020 (Approval No: 20-6T/50).

Authors' contribution

MEU: Definition of intellectual content, Statistical analysis, Manuscript preparation. TİA: Design, Definition of intellectual content. FEU: Clinical Studies. AGE: Data acquisition. AÖ: Literature Search, Review. KT: Literature Search, Review. AG: Clinical Studies. MÜ: Definition of intellectual content, Statistical analysis, Manuscript preparation. AC: Editing, Review. UC: Editing, Review.

References

1. U.S. Department of Health and Human Services. The Health Consequences of Smoking- 50 Years of Progress: A Report of the Surgeon General. Atlanta, GA: U.S. Department of Health and Human Services, Centers for Disease Control and Prevention, National Center for Chronic Disease Prevention and Health Promotion, Office on Smoking and Health, 2014.
2. Shannon VR. Role of pulmonary rehabilitation in the management of patients with lung cancer. Curr Opin Pulm Med 2010; 16: 334-9.
3. Kenny PM, King MT, Viney RC, Boyer MJ, Pollicino CA, McLean JM et al. Quality of life and survival in the 2 years after surgery for non small-cell lung cancer. J Clin Oncol 2008; 26: 233-41.

4. Crandall K, Maguire R, Campbell A, Kearney N. Exercise intervention for patients surgically treated for non-small cell lung cancer (NSCLC): a systematic review. Surg Oncol 2014; 23: 17-30.

5. Brocki BC, Andreasen J, Nielsen LR, Nekrasas V, Gorst-Rasmussen A, Westerdahl E. Short and long-term effects of supervised versus unsupervised exercise training on health-related quality of life and functional outcomes following lung cancer surgery - a randomized controlled trial. Lung Cancer 2014; 83: 102-8.

6. Nici L. The role of pulmonary rehabilitation in the lung cancer patient. Semin Respir Crit Care Med 2009; 30: 670-74.

7. Spruit MA, Singh SJ, Garvey C, ZuWallack R, Nici Linda, Rochester C et al. An official American Thoracic Society/European Respiratory Society statement: key concepts and advances in pulmonary rehabilitation. Am J Respir Crit Care Med 2013; 188: 13-64.

8. Morano MT, Araújo AS, Nascimento FB, Silva GF, Mesquita R, Pinto JS et al. Preoperative pulmonary rehabilitation versus chest physical therapy in patients undergoing lung cancer resection: a pilot randomized controlled trial. Arch Phys Med Rehabil 2013; 94: 53-58.

9. Templeton R, Greenhalgh D. Preoperative rehabilitation for thoracic surgery. Curr Opin Anaesthesiol 2019; 32: 23-28.

10. Kehlet H, Wilmore DW. Evidence-based surgical care and the evolution of fast-track surgery. Ann Surg 2008; 248: 189-98.

11. Nicholson A, Lowe MC, Parker J, Lewis SR, Alderson P, Smith AF. Systematic review and meta-analysis of enhanced recovery programmes in surgical patients. Br J Surg 2014; 101: 172–88.

12. Sanchez-Lorente D, Navarro-Ripoll R, Guzman R, Moises J, Gimeno E, Boada M et al. Prehabilitation in thoracic surgery. J Thorac Dis 2018; 10: 2593-600.

13. Pouwels S, Fiddelaers J, Teijink JAW, Woorst JFT, Siebenga J, Smeenk F. Preoperative exercise therapy in lung surgery patients: A systematic review. Respir Med 2015; 109: 1495-504.

14. Divisi D, Di Francesco C, Di Leonardo G, Crisci R. Preoperative pulmonary rehabilitation in patients with lung cancer and chronic obstructive pulmonary disease. Eur J Cardiothorac Surg 2013; 43: 293-96.

15. Sekine Y, Chiyo M, Iwata T, Yasufuku K, Furukawa S, Amada Y, et al. Perioperative rehabilitation and physiotherapy for lung cancer patients with chronic obstructive pulmonary disease. Jpn J Thorac Cardiovasc Surg 2005; 53: 237-43.

16. Yanez-Brage I, Pita-Fernandez S, Juffe-Stein A, Martinez-Gonzalez U, Pertega-Diaz S, Mauleon-Garcia A. Respiratory physiotherapy and incidence of pulmonary complications in off-pump coronary artery bypass graft surgery: an observational follow-up study. BMC Pulm Med 2009; 28: 36.

17. Hulzebos EH, Helders PJ, Favie NJ, De Bie RA, Brutel de la Riviere A, Van Meeteren NLU. Preoperative intensive inspiratory muscle training to prevent postoperative pulmonary complications in high-risk patients undergoing CABG surgery: a randomized clinical trial. JAMA 2006; 296: 1851-57.

18. Licker M, Karenovics W, Diaper J, Fresard I, Triponez F, Ellenberger C, et al. Short-Term Preoperative High-Intensity Interval Training in Patients Awaiting Lung Cancer Surgery: A Randomized Controlled Trial. J Thorac Oncol 2017; 12: 323-33.

19. Benzo R, Wigle D, Novotny P, Wetzstein M, Nichols F, Shen RK et al. Preoperative pulmonary rehabilitation before lung cancer resection: results from 2 randomized studies. Lung Cancer 2011; 74: 441-45.

20. Bobbio A, Chetta A, Ampollini L, Primomo GL, Internullo E, Carbognani P et al. Preoperative pulmonary rehabilitation in patients undergoing lung resection for non-small cell lung cancer. Eur J Cardiothorac Surg 2008; 33: 95-8.

21. Varela G, Ballesteros E, Jimenez MF, Novoa N, Aranda JL. Cost-effectiveness analysis of prophylactic respiratory physiotherapy in pulmonary lobectomy. Eur J Cardiothorac Surg 2006; 29: 216-20.

22. Gao K, Yu PM, Su JH, He CQ, Liu LX, Zhou YB et al. Cardiopulmonary exercise testing screening and pre-operative pulmonary rehabilitation reduce postoperative complications and improve fast-track recovery after lung cancer surgery: A study for 342 cases. Thorac Cancer 2015; 6: 443-9.

This article is an open access article distributed under the terms and conditions of the Creative Commons Attribution (CC BY) license (http://creativecommons.org/licenses/by/4.0/).

To cite this article: Ozturk O, Ceylan KC, Akcay O, Ors Kaya S, Ucvet A, Gursoy S, Evkan Ozturk A, Samancilar O. Survival outcomes and prognostic factors in salvage surgery for advanced non-small cell lung cancer: a 10-year single-center experience. Curr Thorac Surg 2025;10(3):139-146.

Original Article

Survival outcomes and prognostic factors in salvage surgery for advanced non-small cell lung cancer: a 10-year single-center experience

Ozgur Ozturk[1], Kenan Can Ceylan[2], Onur Akcay[1*], Seyda Ors Kaya[2], Ahmet Ucvet[2], Soner Gursoy[1], Aysen Evkan Ozturk[3], Ozgur Samancilar[4]

[1]Department of Thoracic Surgery, Bakırçay University Çiğli Training and Research Hospital, Izmir, Turkiye

[2]Department of Thoracic Surgery, University of Health Sciences, Dr. Suat Seren Chest Diseases and Chest Surgery Training and Research Hospital, Izmir, Turkiye

[3]Department of Intensive Care Unit, University of Health Sciences, Dr. Suat Seren Chest Diseases and Chest Surgery Training and Research Hospital, Izmir, Turkiye

[4]Department of Thoracic Surgery, Medicana International Izmir Hospital, Izmir, Turkiye

ABSTRACT

Background: In case of failure or a presence of residual tumor after definitive chemotherapy and/or radiotherapy applied in advanced lung cancer treatment, surgical treatment with R0 resection can be performed in selected patients. Also called salvage resections, the indications for these operations remain unclear in the literature. Our study investigated the efficacy of "Salvage" operations using postoperative survival, intraoperative–postoperative morbidity, and mortality along with prognostic factors.

Materials and Methods: Patients operated on for non-small cell lung cancer between January 2006 and December 2016 were examined. Among these patients, 51 patients who underwent R0 resection after definitive chemotherapy and/or radiotherapy were evaluated.

Results: The mean age was 57.58 ± 6.78 (46-78) years in 46 male and 5 female patients. Thirty-two (62.74%) patients had chemotherapy at the definitive dose, 16 (31.37%) received chemoradiotherapy, 3 (5.88%) underwent high-dose radiotherapy. The mean duration between treatment and surgery was 14 ± 10.89 (6-74) weeks. Thirty-two patients were clinically evaluated as Stage 3A, while 19 as Stage 3B and referred to definitive therapy. Thirty (63%) patients underwent lobectomy and 19 (37%) pneumonectomy. Forty-two patients (82.35%) had no complications, and there were complications in 9 (17.65%) patients. Postoperative mortality occurred in four (7.8%) patients. Five-year survival was calculated as 36.6%, and the median survival was 34 months. Median progression-free survival was 26.23 months.

Conclusion: "Salvage surgery" has been considered a feasible method in experienced centers with acceptable morbidity and mortality in selected patients with advanced lung cancer.

Keywords: definitive therapy, lung cancer, salvage surgery

Corresponding Author*: Onur Akcay, MD. Department of Thoracic Surgery, TC Sağlık Bakanlığı Bakırçay Üniversitesi Çiğli Eğitim ve Araştırma Hastanesi, Izmir, Turkiye.
Email: onur_akcay@yahoo.com Phone: +90 2323983700
Doi: 10.26663/cts.2025.024
Received 13.11.2025 accepted 04.12.2025

Introduction

Lung cancer, the most common malignity in men and the second most common in women, is a significant public health problem globally. Because effective screening methods are not sufficient and do not show specific symptoms, the cases are diagnosed as advanced stages at the time of diagnosis [1]. Salvage surgery refers to surgical resection performed after definitive non-surgical therapy (such as chemoradiotherapy) in patients previously deemed unresectable. Despite its increasing use, clear selection criteria and long-term outcomes remain controversial [2]. This study aimed to assess the survival outcomes and prognostic factors associated with salvage pulmonary resections in patients with advanced-stage NSCLC initially deemed inoperable.

Since approximately 70-85% of patients with non-small cell lung carcinoma (NSCLC) are diagnosed in the advanced stage at the time of diagnosis, most patients cannot have the chance for radical surgery [3]. Although systemic chemotherapy ± radiotherapy is generally recommended in this group, the 5-year survival rate is only 5-30% (4). In this group, salvage surgery performed due to local recurrences despite treatment, failure to respond to treatment, or the possibility of resectability after treatment may increase survival.

This retrospective study aimed to investigate the feasibility and efficacy of salvage surgery on survival (OS) with perioperative morbidity and mortality in NSCLC patients who were initially considered to be unable to undergo R0 resection, did not have distant metastases, and were referred to definitive chemotherapy / radiotherapy (RT) / chemoradiotherapy (CRT) for these reasons and subsequently operated. We hypothesized that salvage surgery could offer a survival benefit, particularly in patients achieving mediastinal downstaging after definitive therapy.

Materials and Methods

TBetween January 2006 and December 2016, 3500 patients were operated on for non-small cell lung cancer in our center. Among these patients, there were 80 patients who were initially evaluated as inoperable, referred for definitive treatment, and then referred for surgery again. Of these 80 patients, 51 patients who underwent standard lung resection and mediastinal lymph node dissection and who were considered to have R0 resection were included. Excluding criteria are; distant metastasis, incomplete resection and neoadjuvant therapy.

In the preoperative evaluation process of all patients, chest computerized tomography (CT) angiography, which did not exceed 30 days until the operation, positron emission tomography- computerized tomography (PET-CT), contrast-enhanced brain CT or magnetic resonance imaging (MRI), pulmonary function test (PFT), and blood gas examinations were performed after definitive treatment. The patients with borderline PFT values for resection underwent ladder and VO2max tests. A preoperative cardiological evaluation was performed on all patients. In the presence of suspicious mediastinal lymph nodes on chest CT and PET-CT, mediastinal evaluations were made with endobronchial ultrasound (EBUS) before the operation of the patients who had definitive treatment. The patients were followed up through the outpatient clinic during the postoperative period, and their latest status was updated via the central civil registration system. The effects of variables such as age, gender, type of definitive treatment, type of resection, pathological subtype, tumor diameter, and stage on 5-year survival were investigated. This study was conducted as part of a medical specialty thesis and was approved by the Training Commission for Medical Specialization of the University of Health Sciences, Dr. Suat Seren Chest Diseases and Thoracic Surgery Training and Research Hospital. As per national regulations applicable at the time and the institutional protocol, a separate ethical committee approval was not required for retrospective analyses of anonymized data.

Statistical Analysis

For the analysis of quantitative data, compliance with normal distribution was examined by Kolmogorov-Smirnov Test, parametric methods were used in the analysis of variables with normal distribution and homogeneous variances, and non-parametric methods were used in the analysis of variables that did not have a normal distribution and homogeneous variance. Statistical Package for the Social Sciences (SPSS) 16 program analyzed the data. Comparisons were performed using the independent-samples t-test or Mann–Whitney U test for continuous variables, and Chi-square test for categorical variables. Survival was estimated using the Kaplan-Mei-

er method. Cox regression analysis was used for multivariable survival analysis. A p-value <0.05 was considered significant. Quantitative data were expressed in the tables as mean ± std. (standard deviation) and median ± IQR values. Categorical data were stated as n (numbers) and percentages (%). The data were analyzed at a 95% confidence level, and a p-value less than 0.05 was considered statistically significant.

Results

Of the patients in our study group, 46 (90.19%) were male, 5 (9.81%) were female, and the mean age was 57.58 ± 6.78 years (46-78). Twenty-five (49.01%) patients were not operated on and directed to definitive treatment due to mediastinal invasion, 24 (47.05%) due to bulky/multi N2, 1 (1.96%) due to widespread chest wall invasion, and 1 (1.96%) due to medical inoperability. 32 patients (62.74%) received CT, 16 (31.38%) CRT, and 3 (5.88%) radiotherapy. Before definitive treatment, the stages after clinical evaluation were determined as Stage 3A in 21 (41.18%) and Stage 3B in 30 (58.82%) patients.

The time from the last definitive treatment to the operation was calculated as 14 ± 10.89 (6-74) weeks on average. In the preoperative evaluation, 30 (58.82%) patients had no comorbid disease, while 21 (41.18%) patients had an accompanying disease. 32 (63%) patients underwent lobectomy, and 19 (37%) patients had pneumonectomy. Extended resection was performed in 14 (27.45%) of the patients. Mediastinal staging of 17 patients before definitive treatment or before surgery was evaluated either with EBUS or mediastinoscopy. Clinical evaluation was performed with PET-CT in other patients.

The mean postoperative hospital stay was 8.23 ± 3.12 (4-20) days. Postoperative complications developed in 9 (17.65%) patients. When the pathology reports were examined, 15 (29.41%) patients had adenocarcinoma, 28 (54.9%) had squamous cell carcinoma, and 8 (15.69%) had other pathological types. This other pathological subtype group included adenoid cystic carcinoma in 1 patient, NSCLC in 4 patients, large cell carcinoma in 1 patient, carcinoid tumor in 1 patient, and pleomorphic carcinoma in 1 patient.

The postoperative staging was evaluated as pTNM (pathological TNM) staging after multimodal treatments, and 11 patients (21.57%) were Stage 0, 17 patients (33.33%) Stage 1, 14 (27.25%) Stage 2, and 9 (17.65%) Stage 3.

The mean postoperative hospital stay was 8.23 ± 3.12 (4-20) days. 4 (7.8%) patients developed postoperative mortality in the first month. While no recurrence or metastasis was observed in 29 patients during their follow-up, 14 of 22 patients had lung recurrence, 4 had brain metastasis, one patient had liver, two had bone, and one had adrenal metastases. Five-year survival was 36.6%, and median survival was 34 months.

While the 5-year survival rate was 38.2%, and the median survival was 28 months in those with clinical stage 3A before definitive treatment, these values were 34.1% and 34 months in those with 3B, respectively (Figure 1). There was no significant difference between stage 3A and 3B patients (p = 0.505). The 5-year survival rate was 40.4% in patients with mediastinal invasion as the definitive cause of treatment, and it was 35.3% in patients with multi/bulky N2 (Figure 2). No statistical significance was observed between them (p = 0.254).

While the 5-year survival rate was 38.2% in patients who underwent lobectomy, it was 31.6% in pneumonectomy patients. Although the results were better in lobectomy, there was no statistical significance (p = 0.427). Considering the cell type, 5-year survival was 22.9% in adenocarcinoma, 40.7% in the squamous cell, and 46.9% in other pathologies. No statistical significance was observed between the pathology subtypes as well (p = 0.325).

The pathological T stage was evaluated, and the 5-year survival in the Tx group, which had a complete response after definitive treatment, was found to be the best at a rate of 54.5%. While it was 28.6% in T1, 42.4% in T2, and 40.8% in T3, no patient achieved 5-year survival in the T4 stage. There was no statistical significance between the values (p = 0.104). When the N status was evaluated, the 5-year survival rate was 49.1% in patients with N0 pathologically, 14.3% in N1, and 0% in N2 (Figure 3). Statistically, the survival rate was higher in N0 patients (p = 0.006). When the time to surgery after definitive treatment was examined, there was an inverse correlation between survival and time according to Pearson's correlation test, which was statistically significant (p = 0.032). R-value was -0.301.

Table 1. Studies on "salvage surgery" in the literature.

Authors	Years	No of patients	Indication	Timing of surgery (Weeks)	Mortality (%)	Follow-up (Months)	Overall of survival (Months)
Yang et al [14]	2015	31	RT+recurrent or persistant tumor	18 (8-111)	0	n.g	32
Uramoto et al [16]	2014	8	Mixed	n.g	0	14	n.g
Dickhoff et al [17]	2016	15	CRT+ recurrent or persistant tumor	21 (3-95)	6,7	12,1	46
Schreiner et al [18]	2016	9	CRT+ recurrent tumor	30 (12-165)	11	30	23
Verstegen et al [19]	2016	9	SBRT+ recurrent or persistant tumor	n.g	0	19	26
Shimada et al [20]	2016	18	CRT+ recurrent or persistant tumor	38 (3-282)	0	47	n.g
Mizobuchi et al [21]	2016	12	RT+ recurrent or persistant tumor	96 (36-312)	0	18	n.g
Our study	2020	51	CRT+ recurrent or persistant tumor	14 (6–74)	7.8	n.g	n.g

Abbrev.: n.g: not given; RT: radiotherapy; CRT: chemoradiotherapy; SBRT: stereotactic body radiotherapy.

Table 2. Patients who underwent extended resection.

	Age	Treatment	Type of resection	Follow-up time (Month)
Patient 1	69	Chemotherapy	Extended intrapericardial left pneumonectomy	40
Patient 2	58	Chemotherapy	Extended intrapericardial left pneumonectomy	102
Patient 3	56	Chemoradiotherapy	Extended right upper lobectomy with pulmonary arterioplasty	56
Patient 4	46	Chemoradiotherapy	Extended intrapericardial right pneumonectomy	2
Patient 5	58	Chemotherapy	Extended intrapericardial left pneumonectomy	27
Patient 6	59	Chemotherapy	Extended intrapericardial right upper lobectomy with bronchoplasty	28
Patient 7	51	Radiotherapy	Extended right lower lobectomy with pulmonary arterioplasty	4
Patient 8	63	Chemotherapy	Extended intrapericardial right pneumonectomy	9
Patient 9	48	Chemotherapy	Extended intrapericardial right pneumonectomy	108
Patient 10	68	Chemotherapy	Extended left upper lobectomy with pulmonary arterioplasty	76
Patient 11	59	Chemotherapy	Extended intrapericardial left pneumonectomy	88
Patient 12	63	Chemotherapy	Extended right upper sleeve lobectomy	85
Patient 13	63	Chemotherapy	Extended left upper lobectomy with pulmonary arterioplasty	1
Patient 14	55	Chemotherapy	Extended intrapericardial left pneumonectomy	13

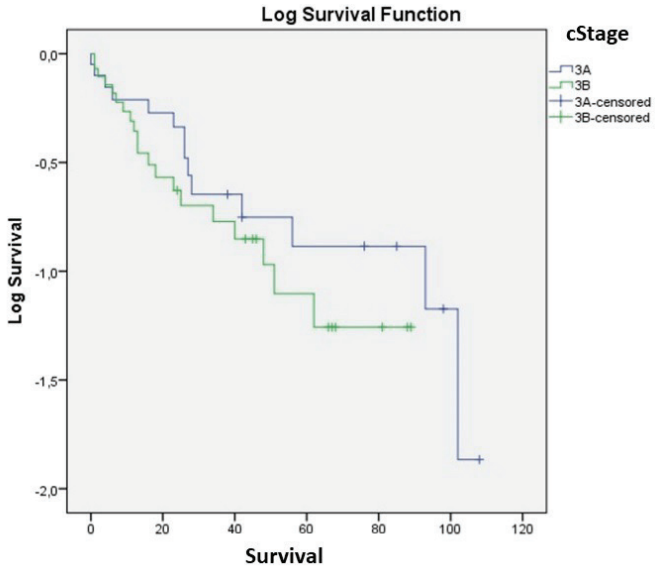

Figure 1. Survival in stages 3A and 3B before definitive treatment.

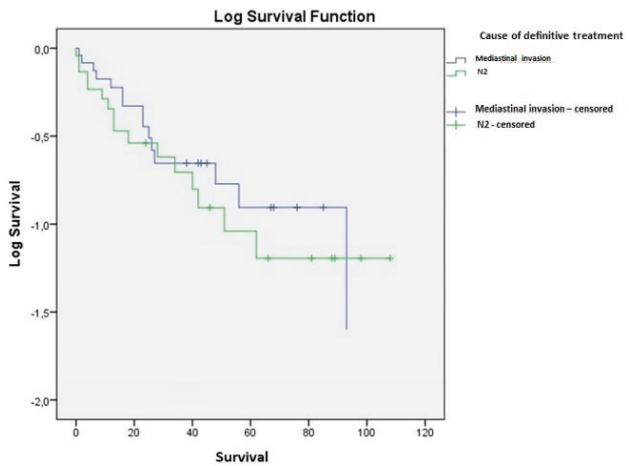

Figure 2. Survival in patients with definitive treatment for mediastinal invasion or bulky/multi N2.

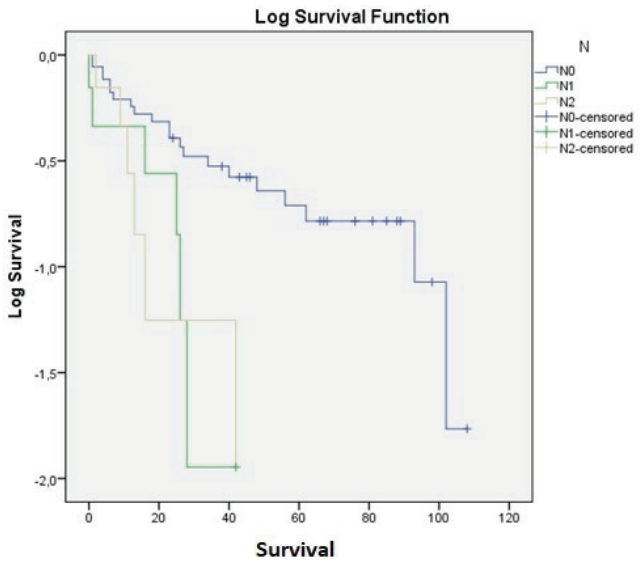

Figure 3. Survival in the case of pathologic N.

Discussion

In our study, the overall survival was 36.6%, and the median survival was 34 months in patients who underwent surgical resection after definitive treatment for locally advanced NSCLC.

Since NSCLC is a heterogeneous group with locally advanced stages, there is no clarity between treatment modalities [5]. Pathological mediastinal staging is recommended in locally advanced diseases. In N0 disease, surgical treatment has positive results if R0 resection can be achieved. There are studies in the literature indicating that an operation can be performed in the presence of single-station N2 with postoperative CT to be administered [6]. Systemic treatment is recommended primarily for patients with multi-station N2/N3 or who cannot undergo R0 resection. Thus, surgical resection can be performed on patients with R0 resection potential, avoiding pneumonectomy if possible. Definitive CRT is recommended as a systemic treatment [5-7]. Studies comparing definitive CRT and trimodal (CRT+surgery) treatment in locally advanced diseases demonstrated that disease-free survival is better in trimodal treatment, although there are similar results in terms of overall survival [5,8,9]. In our study, most patients evaluated as inoperable due to mediastinal invasion and multi/bulky N2 were referred for definitive treatment. As a definitive treatment, per the literature, CT was applied to 32 patients, CRT to 16 patients, and RT to 3 patients.

Since downstaging is known to be a major prognostic factor after induction therapy, re-staging is vital to determine subsequent therapy [6-7]. Many centers perform definitive surgery on cases that are thought to be N0 or N1 after induction therapy [10,11]. Yang et al reported that mediastinal re-staging was associated with improved survival in their Stage 3A-N2 patient series consisting of 111 patients [5]. PET-CT after induction therapy for mediastinal re-staging is of low accuracy due to the high rate of false-positive and false-negative results [12]. In minimally invasive techniques, false negativity was as high as 20-30% [13]. In a study performed with 104 patients in the literature, the sensitivity of re-mediastinoscopy was 71%, the specificity was 100%, and the accuracy rate was 81% [14]. In our study, mediastinal re-evaluation after definitive treatment was performed with mediastinoscopy in 10 patients and EBUS in 7 patients. Other patients were assessed according to PET–CT results.

In our study, the survival of N0, N1, and N2 patients after definitive treatment was better, similar to the literature. After definitive treatment, tumoral treatment was evaluated as the complete response in our Tx and Stage 0 patients, and the highest survival rates were obtained in these groups, in line with the literature.

The American Intergroup 0139 study, the European organization for cancer research and treatment (EORTC) 08941 study, and the ESPATUE study are the largest phase III studies examining treatment modalities in locally advanced diseases. The American intergroup study determined no difference in median survival in patients who received trimodal therapy and definitive therapy. Trimodal therapy was superior in progression-free survival. It was suggested that both treatment modalities could be applied [8]. In the EORTC study, two groups of patients who underwent CT+RT and chemotherapy+surgical treatment were compared, and there was no difference in the survival between the two groups. Similarly, no difference was observed in progression-free survival. CT+RT treatment has been recommended for low morbidity and mortality rates [8]. In the ESPATUE study, when the two groups that underwent definitive CRT and surgical resection after CT were compared, no difference was determined between both 5-year and progression-free survivals. It was re-

ported that the application of both treatment modalities in this group of patients positively affects survival [11].

In a phase III randomized study by Miklos Pless et al (clinicaltrials.gov number NCT00030771), surgical resection was performed on IIIA N2 patient groups, one of whom started with CT and the other with CRT. In the CRT and CT groups, the disease-free survival was 12.8 and 11.6 months, and the median survival was 37.1 and 26.2 months, respectively. There was no statistical difference between the groups. They concluded that radiotherapy did not provide additional benefit to patients undergoing surgery after chemotherapy and stated that a definitive local treatment method combined with neoadjuvant chemotherapy is sufficient to treat resectable stage IIIA/N2 non-small cell lung cancer [5].

The most discussed concepts in locally advanced diseases include potentially resectable, unresectable, and bulky N2 diseases, re-staging after induction therapy, the effectiveness of surgery and radiotherapy in combined treatments, treatment approach in persistent N2, and postoperative radiotherapy after resection in N2 diseases [11]. In our study, the median survival was 34 months, and the 5-year survival was 36.6%. Median progression-free survival was 26.23 months. Downstaging in the N factor seems to be the most important factor affecting survival in locally advanced stages. The time between definitive treatment and surgery also seems to be critical in survival. Our results were compatible with the literature.

"Salvage surgery" is still a controversial issue, but its full extent and effect on survival are unclear. In the literature, "salvage surgery" has also been defined as in patients who have locally advanced disease and need emergency surgery while under induction treatment, who were operated on only after SBRT (stereotactic body radiation therapy), who were operated on only after high-dose RT, or who could not complete induction treatment and were operated due to contraindications (Table 1). In the publications under these definitions, there are also those with R1 resection. We consider that the ideal surgical resection is R0 resection and complete mediastinal lymph node dissection. The patients in our study were patients who underwent R0 resection and were treated with different modalities as definitive treatment.

Due to the differences in the definition of "Salvage surgery," it may not be correct to compare the results in the literature with each other since the studies in the literature show differences in indications. Hence, selecting the appropriate patient for the "salvage surgery" application is vital. In other treatment methods, the median survival for patients with recurrent local lung cancer is less than 12 months [13].

After definitive treatment, lung resection may increase mortality and morbidity rates due to the risk of vascular injury and dissection difficulties as a result of the effects of definitive treatment [14,15]. In our study, the first 1-month mortality occurred in 4 (7.8%) patients, while postoperative major or minor complications developed in 9 (17.64%) patients. Our results were evaluated as consistent with the literature or even better.

After definitive treatment, the effects of definitive treatment on the lung from the time to surgery make the operation risky by creating dissection difficulties. When the literature is examined, durations longer than 12 weeks on average increase surgical morbidity and mortality due to increased fibrosis [14,15]. Our study observed that the time until the transition to surgery after definitive treatment was similar to the literature.

The widespread use of immunotherapeutic agents, such as immune checkpoint inhibitors, in the treatment of advanced non-small cell lung cancer (NSCLC) has led to the emergence of a patient cohort that responds to therapy but subsequently develops residual or oligoprogressive disease [22]. In these selected patients, salvage surgery has emerged as a feasible and safe local treatment option [23,24]. Multicentre studies have demonstrated that salvage resections following immunotherapy are predominantly lobectomies, achieve high rates of complete resection (R0), and are associated with acceptable perioperative morbidity and 30- to 90-day mortality rates [22-24]. Furthermore, a significant proportion of these patients achieve a pathological complete response (pCR), which is considered a promising prognostic indicator for long-term survival [24].

Limitations of the study

There were also some limitations in our study. The mediastinal staging was performed only before definitive treatment and/or surgery in our data. We think that the

inconsistency in mediastinal staging was due to clinical experience, changes in staging and the lack of oncology council evaluations in the first patients included in the study. All patients in the later period of our study underwent mediastinal staging both before definitive treatment and before surgery, they were evaluated in the oncology council, and their treatments were applied in line with the literature. As per the literature, we think that mediastinal "downstaging" should be evaluated in the pathological dimension for more objective data. Unfortunately, it is not possible for the evaluations to be based on an objective basis since locally advanced stage disease is a very heterogeneous group, there are quite different opinions at this stage, and the changes in staging are more common at these stages. All patients at this stage should be evaluated in oncology councils, including oncologists, chest diseases, radiation oncology, and thoracic surgery specialists. In the patients we included in our study, there was no comprehensive oncology council evaluation in our cases before 2010.

Lung resection after definitive therapy can be performed with considerable morbidity and mortality. In locally advanced diseases, evaluation should be multidisciplinary. Trimodal treatments and surgery have positive contributions to survival and disease-free survival in patients at this stage. For the definition of "salvage surgery" to be applied in locally advanced diseases, studies should be performed with more extensive patient populations. With the developing surgical techniques and imaging studies, surgery will become more applicable after definitive treatment in locally advanced diseases, making it possible to be more involved in treatment modalities.

In conclusion, salvage surgery may offer a survival benefit in carefully selected patients with advanced NSCLC following definitive treatment. Future prospective studies with larger cohorts and uniform definitions are warranted to clarify its role in multimodal management.

Declaration of conflicting interests

The authors declared no conflicts of interest with respect to the authorship and/or publication of this article.

Funding

The authors received no financial support for the research and/or authorship of this article.

Ethics approval and consent to participate

This study was conducted as part of a medical specialty thesis and was approved by the Training Commission for Medical Specialization of the University of Health Sciences, Dr. Suat Seren Chest Diseases and Thoracic Surgery Training and Research Hospital. As per national regulations applicable at the time and the institutional protocol, a separate ethical committee approval was not required for retrospective analyses of anonymized data.

Authors' contrubitions

OO and KCC design and planning the study, writing and approval of the final version. OA design and planning the study, writing, statistical analysis and approval of the final version. SOK design and planning the study; writing and approval of the final version. AU design and planning the study, statistical analysis and approval of the final version. SG design and planning the study, writing and approval of the final version. AEO and OS writing and approval of the final version.

References

1. Bunn PA. Worldwide Overview of the Current Status of Lung Cancer Diagnosis and Treatment. Arch Pathol Lab Med 2012; 136: 1478-81.
2. Hamada A, Soh J, Mitsudomi T. Salvage surgery after definitive chemoradiotherapy for patients with non-small cell lung cancer. Transl Lung Cancer Res 2021; 10: 555-62.
3. Ramnath N, Dilling TJ, Harris LJ, Kim AW, Michaud GC, Balekian AA et al. Treatment of stage III non-small cell lung cancer: Diagnosis and management of lung cancer, 3rd ed: American College of Chest Physicians evidence-based clinical practice guidelines. Chest 2013; 143: e314S-e340S.
4. Goldstraw P, Chansky K, Crowley J, Rami-Porta R, Asamura H, Eberhardt WE et al. The IASLC lung cancer staging project: Proposals for revision of the TNM stage groupings in the forthcoming (eighth) edition of the TNM classification for lung cancer. J Thorac Oncol 2016; 11: 39-51.
5. Pless M, Stupp R, Ris HB, Stahel RA, Weder W, Thierstein S et al. Induction chemoradiation in stage IIIA/N2 non-small-cell lung cancer: a phase 3 randomised trial. Lancet 2015; 386: 1049-56.
6. Tsitsias T, Boulemden A, Ang K, Nakas A, Waller DA. The N2 paradox: similar outcomes of pre- and postoperatively identified single-zone N2a positive non-small-cell lung cancer. Eur J Cardiothorac Surg 2014; 45: 882-7.

7. Ahn JS, Ahn YC, Kim JH, Lee CG, Cho EK, Lee KC et al. Multinational randomized phase III trial with or without consolidation chemotherapy using docetaxel and cisplatin after concurrent chemoradiation in inoperable stage III non–small-cell lung cancer: KCSG-LU05-04. J Clin Oncol 2015; 33: 2660-6.
8. Albain K, Swann RS, Rusch VW, Turrisi AT, Shepherd FA, Smith C et al. Radiotherapy plus chemotherapy with or without surgical resection for stage III non-small-cell lung cancer: a phase III randomized controlled trial. Lancet 2009; 374: 379-86.
9. Van Meerbeeck JP, Kramer GW, Van Schil PE, Legrand C, Smit EF, Schramel F et al. Randomized controlled trial of resection versus radiotherapy after induction chemotherapy in stage IIIA-N2 non- small-cell lung cancer. J Natl Cancer Inst 2007; 99: 442-50.
10. Van Schil P, Van Meerbeeck J, Kramer G, Splinter T, Legrand C, Giaccone G et al. Morbidity and mortality in the surgery arm of EORTC 08941 trial. Eur Respir J 2005; 26: 192-7.
11. Eberhardt WE, Pottgen C, Gauler TC, Friedel G, Veit S, Heinrich V et al. Phase III Study of Surgery Versus Definitive Concurrent Chemoradiotherapy Boost in Patients With Resectable Stage IIIA(N2) and Selected IIIB Non-Small-Cell Lung Cancer After Induction Chemotherapy and Concurrent Chemoradiotherapy (ESPATUE). J Clin Oncol 2015; 33: 4194-201.
12. Van Schil PE, Yogeswaran K, Hendriks JM, Lauwers P, Faivre-Finn C. Advances in the use of surgery and multimodality treatment for N2 non-small cell lung cancer. Expert Rev Anticancer Ther 2017; 17: 555-61.
13. Noble J, Ellis PM, Mackay JA, Evans WK. Second-line or subsequent systemic therapy for recurrent or progresive non-small cell lung cancer: a systematic review and practice guideline. J Thorac Oncol 2006; 1: 1042-58.
14. Yang CJ, Meyerhoff RR, Stephens SJ, Singhapricha T, Toomey CB. Long-Term Outcomes of Lobectomy for Non-Small Cell Lung Cancer After Definitive Radiation Treatment. Ann Thorac Surg 2015; 99: 1914-20.
15. Bauman JE, Mulligan MS, Martins RG, Kurland BF, Eaton KD, Wood DE. Salvage lung resection after definitive radiation (>59 Gy) for non-small cell lung cancer: surgical and oncologic outcomes. Ann Thorac Surg 2008; 86: 1632-8.
16. Uramoto H, Tanaka F. Salvage thoracic surgery in patients with primary lung cancer. Lung Cancer 2014; 84: 151-5.
17. Dickhoff C, Dahele M, Paul MA, van de Ven PM, de Langen AJ, Senan S et al. Salvage surgery for locoregional recurrence or persistent tumor after high dose chemoradiotherapy for locally advanced non-small cell lung cancer. Lung Cancer 2016; 94: 108-13.
18. Schreiner W, Dudek W, Lettmaier S, Fietkau R, Sirbu H. Should salvage surgery be considered for local recurrence after definitive chemoradiation in locally advanced non-small cell lung cancer. J Cardiothorac Surg 2016; 11: 1-7.
19. Verstegen NE, Maat APWM, Lagerwaard FJ, Paul MA, Versteegh MI, Joosten JJ et al. Salvage surgery for local failures after stereotactic ablative radiotherapy for early stage non-small cell lung cancer. Radiat Oncol 2016; 11: 131.
20. Shimada Y, Suzuki K, Okada M, Nakayama H, Ito H, Mitsudomi T et al. Feasibility and efficacy of salvage lung resection after definitive chemoradiation therapy for stage III non-small-cell lung cancer. Interact Cardiovasc Thorac Surg 2016; 23: 895-901.
21. Mizobuchi T, Yamamoto N, Nakajima M, Baba M, Miyoshi K, Nakayama H et al. Salvage surgery for local recurrence after carbon ion radiotherapy for patients with lung cancer. Eur J Cardiothorac Surg 2016; 49: 1503-9.
22. Ueno T, Yamashita M, Yamashita N, Uomoto M, Kawamata O, Sano Y et al. Safety of salvage lung resection after immunotherapy for unresectable non-small cell lung cancer. Gen Thorac Cardiovasc Surg 2022; 70: 812-7.
23. Nemeth A, Canavan ME, Zhan PL, Udelsman BV, Ely S, Wigle DA et al. Salvage lung resection after immunotherapy is feasible and safe. JTCVS Open 2024; 20: 141-50.
24. Chiappetta M, Sassorossi C, Lococo F, Guerrera F, Ruffini E, Lyberis P et al. Short-term results of salvage surgery after immune and target therapies in non-small cell lung cancer. J Thorac Dis 2025; 17: 4929-39.

This article is an open access article distributed under the terms and conditions of the Creative Commons Attribution (CC BY) license (http://creativecommons.org/licenses/by/4.0/).

Current Thoracic Surgery

To cite this article: Can A, Sen H, Tiske MA, Sahinoglu T, Yildiran H. Evaluation of thoracic injuries resulting from two major earthquakes in Turkey. Curr Thorac Surg 2025;10(3):147-153.

Original Article

Evaluation of thoracic injuries resulting from two major earthquakes in Turkey

Atilla Can[1]*, Halil Şen[2], Muhammet Ali Tiske[1], Tuba Şahinoğlu[1], Hüseyin Yıldıran[1]

[1]Department of Thoracic Surgery, Selçuk University Faculty of Medicine, Konya, Turkey
[2]Department of Thoracic Surgery, University of Health Sciences, Beyhekim Training and Research Hospital, Konya, Turkey

ABSTRACT

Background: Earthquakes are sudden and destructive natural disasters with significant health implications. Thoracic injuries are among the most prevalent and serious trauma types due to their high morbidity and mortality rates. This study aimed to evaluate the clinical features, types of injuries, and management processes of thoracic trauma cases following the February 6, 2023, earthquakes in Turkey.

Materials and Methods: The study was conducted at a tertiary trauma center and included 14 patients. Data on age, gender, types of trauma, chest trauma score (CTS), duration of entrapment under debris, and associated injuries were analyzed. Statistical analyses were performed using SPSS version 21.0 with appropriate parametric and non-parametric tests.

Results: The mean age of patients was 43.64 ± 16.58 years, with 64.3% female and 35.7% male. The most common injuries were rib fractures (57.1%), hemothorax (35.7%), and crush syndrome (28.6%). The mean CTS was 3.50 ± 2.68, and 80% of patients with CTS scores above 5 had significant complications. Entrapment duration under debris was shorter in older patients, showing a statistically significant negative correlation with age (Spearman's rho = -0.568, p = 0.034). Prolonged entrapment was associated with longer hospital stays (Spearman's rho = 0.634, p = 0.015).

Conclusion: Earthquake-related thoracic injuries represent serious medical challenges that require multidisciplinary approaches and early interventions. The CTS proved effective in assessing trauma severity and guiding clinical priorities. Entrapment duration and age were identified as critical factors influencing patient prognosis, emphasizing their importance in post-disaster healthcare planning. Future studies with larger samples are needed to further investigate these relationships.

Keywords: chest trauma, earthquake injuries, hemothorax, rib fracture, thoracic injuries

Corresponding Author*: Atilla Can, MD. Department of Thoracic Surgery, Selçuk University Faculty of Medicine, Konya, Turkey.
E-mail: atillacan_ac@yahoo.com Phone: +90 5355557436
Doi: 10.26663/cts.2025.025
Received 01.11.2025 Accepted 05.12.2025

Introduction

Earthquakes are sudden and destructive natural disasters that cause profound effects on both human life and the environment. The physical impact of earthquakes extends beyond the destruction of buildings and infrastructure; they also pose serious threats to human health.

Turkey is located in one of the world's most seismically active zones, frequently experiencing major earthquakes due to the presence of significant fault lines, such as the North Anatolian Fault and the East Anatolian Fault. Consequently, large-scale earthquakes periodically occur in Turkey, leading to substantial loss of life and property. Past disasters, such as the 1999 İzmit Earthquake and the 2020 İzmir Earthquake, have highlighted the country's vulnerability to seismic events and the inevitability of such natural catastrophes.

On February 6, 2023, two devastating earthquakes, each exceeding magnitude 7 on the Richter scale, struck southern Turkey within a nine-hour interval. These earthquakes affected a vast region encompassing 10 provinces, resulting in more than 40,000 fatalities and over 100,000 injuries. While the primary impact of earthquakes is associated with mortality, a significant number of survivors sustain various traumatic injuries. Among the most common earthquake-related injuries are severe fractures, internal organ damage, crush syndrome, burns, limb traumas, abdominal injuries, head traumas, and thoracic injuries [1].

Thoracic trauma, particularly pneumothorax and rib fractures, is a major clinical concern in post-earthquake injuries. Additionally, prolonged entrapment under rubble can lead to severe systemic complications, including compartment syndrome, renal failure, and hypovolemic shock. Thoracic injuries resulting from earthquakes constitute a critical aspect of disaster- related medical challenges. These injuries can occur due to multiple mechanisms, with the most common being direct trauma from collapsing structures or debris impact. Such blunt forces can lead to severe thoracic fractures and internal organ injuries. Moreover, panic- induced movements during seismic activity can contribute to additional traumatic injuries.

Studies indicate that approximately 10% of earthquake survivors experience thoracic and/or pulmonary injuries. The most prevalent types of injuries vary depending on the mechanism of trauma; however, individuals trapped beneath completely collapsed buildings and subjected to prolonged compression are at a higher risk of developing pneumothorax and rib fractures [2]. Despite advancements in treatment modalities, thoracic trauma remains associated with high morbidity and mortality rates. Specifically, thoracic trauma accounts for 10-15% of all trauma cases and 7.6-15.9% of earthquake-related injuries [3-5].

This study retrospectively analyzes the clinical characteristics and treatment outcomes of patients presenting with thoracic trauma following the February 6, 2023, Turkey earthquakes at our hospital.

The aim of this study is to evaluate the clinical features, injury patterns, and treatment outcomes of patients who sustained thoracic trauma following the February 6, 2023, earthquakes in Turkey.

Materials and Methods

This study was conducted as a retrospective analysis at a tertiary healthcare center, focusing on patients affected by the February 6, 2023 earthquakes. The primary aim was to evaluate the clinical characteristics and treatment processes of patients who sustained thoracic trauma following the earthquakes. The study was approved by the local ethics committee and institutional administration.

Patients admitted to our hospital between February 8 and February 28, 2023 were screened for eligibility. Earthquake-related thoracic trauma cases were identified through medical records. Earthquake-related injury was defined using objective criteria, including documentation of collapse-related mechanisms, confirmed extrication from debris, transfer from earthquake-affected provinces, or explicit notation such as "earthquake-related injury" in physician or emergency medical service reports. All eligible cases were verified independently through electronic medical record review to ensure accurate classification.

Patients whose injuries had no clear association with the earthquake or had an uncertain etiology were excluded. Entrapment under debris was also recorded and analyzed, although it was not used as an inclusion criterion. The duration of entrapment was obtained from patient or family statements, prehospital rescue documentation, and emergency medical service transfer records, when available.

This study was approved by Ethics Committee of Selçuk University, Noninvasive Clinic Ethics Committee (Approval date: 04.06.2024; Number: 2024/285.)

Statistical Analysis

Statistical analysis of medical data was performed using SPSS version 21.0 (Statistical Package for Social Sciences, SPSS Inc., USA). This software was chosen due to its extensive set of tools for both parametric and non-parametric statistical analyses. For continuous variables, the minimum, maximum, mean ± standard deviation, median, first quartile, and third quartile values were calculated. Categorical variables were summarized using frequency distributions and percentage values. To assess the assumption of normality, the Shapiro-Wilk normality test was conducted. The results indicated that continuous variables, such as age and duration of entrapment under debris, did not follow a normal distribution ($p < 0.05$). Therefore, non-parametric statistical methods were employed for further analyses. For variables exhibiting normal distribution, Pearson's correlation coefficient was used, while for non-normally distributed data, Spearman's rank correlation coefficient was calculated. A statistical significance level of 5% ($p < 0.05$) was applied to all analyses.

Results

A total of 14 patients were included in the study, with a mean age of 43.6 ± 16.6 years (range: 21–82 years). Gender distribution: 64.3% of the patients were female (n = 9), while 35.7% were male (n = 5). The mean age of female patients was slightly lower than that of male patients. This age difference was also associated with differences in the duration of entrapment under debris, with female patients exhibiting longer entrapment durations compared to their male counterparts.

Distribution of trauma types

Rib Fractures: Multiple rib fractures were detected in 42.9% of patients, while 14.3% had a single rib fracture, and 42.9% had no rib fractures at all (Figure 1, Figure 2). Patients with multiple rib fractures frequently exhibited pneumothorax and/or hemothorax. This suggests that severe rib fractures are associated with significant pulmonary damage, intrathoracic pressure changes, and higher rates of pneumothorax and hemothorax (Table 1).

Pneumothorax was observed in 14.3% of the patients. All affected patients required tube thoracostomy to manage lung collapse and restore intrathoracic pressure. Tube thoracostomy effectively alleviated respiratory distress and ensured favorable outcomes.

Hemothorax was detected in 35.7% of patients (Figure 3). The majority of these patients required tube thoracostomy to drain intrapleural blood and restore lung expansion. One patient was managed conservatively, as the hemothorax was minimal. Tube thoracostomy remains the standard intervention for hemothorax, preventing complications and supporting pulmonary function.

Sternal fracture was identified in 7.1% of patients, often associated with severe trauma. In the affected patient, sternal fracture was accompanied by multiple rib fractures, hemothorax, pneumothorax, and pulmonary contusion. These findings highlight the high-energy mechanism of such injuries, which affect both the thoracic wall and intrathoracic organs. The patient required tube thoracostomy, which effectively regulated intrathoracic pressure and improved respiratory status. Sternal fractures emphasize the need for rapid and effective interventions, given their frequent association with severe thoracic injuries.

Crush Syndrome was diagnosed in 28.6% of patients, primarily linked to prolonged entrapment under debris and high-energy trauma. Characterized by prolonged muscle compression, crush syndrome led to systemic complications, including myoglobinemia, hyperkalemia, acute kidney injury, and metabolic acidosis. Patients with crush syndrome frequently exhibited concurrent thoracic trauma, such as hemothorax, pneumothorax, or pulmonary contusion. These findings underscore the systemic impact of severe trauma and highlight the necessity of a multidisciplinary approach in managing these patients effectively.

Chest trauma score

The chest trauma score (CTS) is a scoring system designed to predict outcomes in patients with blunt chest trauma. CTS evaluates age, the number of rib fractures, the severity of pulmonary contusion, and the presence of bilateral rib fractures to generate a total score. The scores range from 2 to 12, with higher scores being associated with worse clinical outcomes. The CTS calculation table is presented in Table 2. This scoring system serves as a practical tool for early intervention in trauma patients [6].

The mean CTS score in our study was 3.5 ± 2.7. Among patients with CTS scores above 5, 80% were found to have additional trauma or complications. Higher CTS

scores were associated with longer ICU stays, increased pneumothorax incidence, and higher complication rates, reflecting the impact of trauma severity on clinical outcomes. These findings support the potential utility of CTS in stratifying trauma patients based on severity, aiding in early risk assessment and clinical decision-making.

Normality testing showed that only age was normally distributed, while entrapment duration, hospital stay, and CTS did not follow a normal distribution (Table 3). Correlation analyses revealed no statistically significant relationship between CTS and age ($\varrho = -0.18$, $p = 0.53$), entrapment duration ($\varrho = -0.12$, $p = 0.67$), or hospital stay ($\varrho = 0.21$, $p = 0.47$). Confidence intervals for these correlations were wide, reflecting the small sample size (Table 4). To explore the relationship between specific thoracic complications and CTS, non-parametric comparisons were conducted using the Mann-Whitney U test. Among the binary variables examined (pneumothorax, hemothorax, contusion, crush syndrome, tube thoracostomy, and ICU admission), only pulmonary contusion was significantly associated with higher CTS scores ($p = 0.045$). No other significant associations were observed (Table 5).

Duration of entrapment under debris

The duration of entrapment for the patients in this study ranged from a minimum of 0 hours to a maximum of 72 hours, with a mean duration of 14.9 ± 21.9 hours. These durations exhibited a wide distribution, with the longest entrapment time recorded as 72 hours.

A statistically significant negative correlation was found between age and duration of entrapment (Spearman's rho = -0.568, $p = 0.034$). This finding suggests that as age increases, the duration of entrapment tends to decrease.

Additional injuries and intensive care unit requirements

Among the patients, 50% did not exhibit any additional injuries, whereas 14.3% presented with associated injuries, including pelvic fractures and scapular fractures. These types of additional injuries were predominantly observed in patients subjected to high-energy trauma mechanisms, highlighting the systemic impact of severe trauma. The presence of additional injuries complicated clinical management and necessitated a multidisciplinary approach to patient care.

A total of 21.4% of patients required intensive care unit (ICU) admission. Among those requiring intensive care, intrathoracic pathologies such as pneumothorax and hemothorax were frequently detected. This suggests that the severity of trauma and the extent of thoracic injuries significantly influenced the need for intensive care. Furthermore, the mean hospital stay was longer among patients admitted to the ICU compared to those who were not. This highlights that severe thoracic trauma prolongs recovery and requires comprehensive management.

These results suggest that earthquake-related thoracic trauma may extend beyond localized injuries and potentially involve systemic implications. The severity of trauma necessitates appropriate treatment strategies, early intervention, and prevention of complications, all of which are critical for optimizing patient outcomes.

Table 1. Distribution of trauma types in earthquake-related thoracic trauma patients.

Type of trauma	n	(%)
Rib fracture (multiple)	6	42.9
Rib fracture (single)	2	14.3
No rib fracture	6	42.9
Pneumothorax	2	14.3
Hemothorax	5	35.7
Crush Syndrome	4	28.6

Table 2. Chest trauma score (CTS) parameters and scoring criteria.

Parameter	Score
Age	
<45	1
45-65	2
>65	3
Pulmonary contusion	
None	0
Unilateral minor	1
Bilateral minor	2
Unilateral major	3
Bilateral major	4
Rib fracture	
<3	1
3-5	2
>5	3
Bilateral rib fracture	
No	0
Yes	2

Table 3. Normality test results (Shapiro-Wilk).			
Variable	Shapiro-Wilk statistic	p-value	Normally distributed (p > 0.05)
Age	0.9539	0.6225	Yes
Duration under debris	0.7370	0.0009	No
Hospital stay (days)	0.5663	0.0000	No
CTS score	0.8569	0.0276	No
Interpretation: Only age follows a normal distribution. Non-parametric tests were used for others.			

Table 4. Correlation between CTS and numerical variables (Spearman with 95% Confidence Interval).				
Variable	Spearman r	p-value	95% CI (lower)	95% CI (upper)
Age	-0.184	0.530	-0.667	0.330
Duration under debris	-0.125	0.671	-0.648	0.601
Hospital stay (days)	0.211	0.469	-0.356	0.750
Interpretation: None of the correlations were statistically significant (p > 0.05). Wide confidence intervals are due to small sample size.				

Table 5. Association between binary complications and CTS (Mann-Whitney U Test).				
Binary Variable	Median CTS (var)	Median CTS (yok)	Mann-Whitney U	p-value
Hemothorax	4.0	3.0	26.5	0.635
Pneumothorax	7.0	2.5	21.0	0.114
Contusion	8.0	3.0	21.5	0.045
Crush Syndrome	2.5	3.0	17.5	0.773
Tube Thoracostomy	5.0	2.5	29.0	0.221
Interpretation: Only contusion showed a statistically significant difference in CTS scores (p = 0.045).				

Discussion

This study contributes to the limited body of literature on the clinical outcomes of earthquake-related thoracic trauma and highlights the significance of structured assessment tools such as the CTS. The management of thoracic trauma in disaster settings is inherently complex, particularly due to challenges in timely access to healthcare and the high severity of crush- and debris-related injuries. Our findings demonstrate the relevance of entrapment duration, CTS, and coexisting injuries in shaping clinical outcomes. Compared with previous studies, the present analysis provides a focused examination of these prognostic factors.

Severe thoracic trauma related to prolonged entrapment is a critical concern in large-scale earthquakes, where mortality among trapped individuals is known to be high [7]. Although specific studies on earthquake-related thoracic trauma are scarce, data from blunt chest trauma indicate that one in three patients develops pneumothorax or hemothorax and more than half sustain pulmonary contusions [8]. These observations are consistent with our cohort, in which rib fractures were the most common injury, followed by hemothorax, pneumothorax, and pulmonary contusion. Prior research has shown that superficial lacerations and contusions are also frequently observed in trauma cases [9–11]. As the ribs represent the primary protective structure of the thoracic cage, disruption of this barrier increases the likelihood of intrathoracic complications. Our results align with existing literature in this regard.

Findings from previous earthquakes further contextualize our results. During the Kobe earthquake, 12.9% of evaluated patients had thoracic injuries, most commonly superficial wounds and rib or clavicular fractures [12]. Similarly, following the 2011 Van earthquake, multiple rib fractures were common, occurring in 46.2% of affected individuals [13]. Although injury rates differ by earthquake magnitude and rescue efficiency, our findings showed comparable proportions of rib fractures and multiple fractures.

In our study, the mean CTS was 3.50 ± 2.68. CTS has been consistently validated as a reliable metric for predicting outcomes in blunt thoracic trauma [14-16]. Prior studies have linked higher CTS values with increased rates of pneumonia, need for mechanical ventilation, longer ICU stay, and mortality [14,16,17]. Consistent with these findings, 80% of patients in our cohort with CTS >5 exhibited additional injuries or serious complications, most commonly pneumothorax.

Furthermore, higher CTS values were associated with a greater likelihood of ICU admission. These parallels reinforce the utility of CTS as an early risk-stratification tool in disaster-related thoracic trauma.

Entrapment duration was positively correlated with hospital length of stay, consistent with earlier studies reporting delayed transfers and prolonged hospitalization among individuals trapped for extended periods [21-23]. Research from the Marmara and Lushan earthquakes similarly emphasized the role of trauma severity and infection burden in prolonging recovery [22,24]. These findings collectively underscore the importance of rapid, well-coordinated rescue operations to reduce morbidity in earthquake victims.

In terms of the relationship between age and entrapment duration, previous literature reports lower survival rates among elderly individuals following prolonged entrapment [25]. In our cohort, older patients had shorter documented entrapment durations. This observation may reflect differences in survival patterns, rescue dynamics, or reporting accuracy rather than intrinsic physiological endurance alone. While definitive causal explanations cannot be drawn due to the small sample size, this finding highlights the relevance of early rescue efforts for elderly individuals.

The clinical implications of our findings are notable. CTS may serve as a rapid triage tool in mass-casualty scenarios to identify patients at higher risk for complications. Early tube thoracostomy for pneumothorax or hemothorax and timely preparation of ICU resources are essential components of disaster-related thoracic trauma management. Additionally, the association between prolonged entrapment and extended hospitalization emphasizes the importance of efficient triage and rescue systems. Integrating these insights into disaster preparedness strategies may improve outcomes in future earthquakes.

Limitations of the study

This study has several limitations. The single-center setting outside the earthquake zone and small sample size (n = 14) restrict generalizability and statistical power. Variability in entrapment duration, trauma severity, and pre-existing conditions further complicates interpretation. The presence of multi-trauma in some patients may also have influenced outcomes. Despite these constraints, the study provides valuable observations on the characteristics and management of earthquake-related thoracic injuries and contributes to the limited existing evidence.

In conclusion, this study evaluated the clinical characteristics and outcomes of thoracic trauma among patients affected by the February 6, 2023 earthquakes in Turkey. Entrapment duration, Chest Trauma Score (CTS), and the presence of associated injuries emerged as key factors influencing clinical course and resource needs. CTS demonstrated practical value in early risk stratification and may serve as a useful tool for guiding treatment priorities in disaster-related thoracic trauma.

Management of earthquake-related thoracic injuries particularly pneumothorax, hemothorax, and crush syndrome remains crucial for improving survival. Prolonged entrapment was associated with extended hospitalization, while older individuals had shorter documented entrapment durations, underscoring the importance of timely and efficient rescue operations.

These findings highlight the need to strengthen post-earthquake healthcare capacity, establish structured early intervention protocols, and adopt multidisciplinary management strategies. Larger multicenter studies are required to validate these observations and provide more robust evidence to inform clinical practice. Until such data become available, the conclusions of this study should be interpreted with caution due to the limited sample size and single-center design.

Declaration of conflicting interests

The authors declared no conflicts of interest with respect to the authorship and/or publication of this article.

Funding

The authors received no financial support for the research and/or authorship of this article.

Ethics Committee Approval

This study was approved by Ethics Committee of Selçuk University, Noninvasive Clinic Ethics Committee (Approval date: 04.06.2024; Number: 2024/285.)

Author Contributions

AC: Conception, design, resources, materials, data collection and processing, analysis and interpretation, literature search, writing manuscript, critical review. HŞ: Data collection, analysis and processing, literature search. MAT: Data collection, resources, materials. TŞ: Data collection, analysis and processing. HY: Supervision, design, critical review, analysis and interpretation.

References

1. Ramirez M, Peek-Asa C. Epidemiology of traumatic injuries from earthquakes. Epidemiol Rev 2005; 27: 47-55.
2. Ozdogan S, Hocaoglu A, Caglayan B, Imamoglu OU, Aydin D. Thorax and lung injuries arising from the two earthquakes in Turkey in 1999. Chest 2001; 120: 1163-6.
3. Hu J, Guo YQ, Zhang EY, Tan J, Shi YK. Chest injuries associated with earthquakes: an analysis of injuries sustained during the 2008 Wen-Chuan earthquake in China. Surg Today 2010; 40: 729-33.
4. Virgós Señor B, Nebra Puertas AC, Sánchez Polo C, Broto Civera A, Suárez Pinilla MA. Predictors of outcome in blunt chest trauma. Arch Bronconeumol 2004; 40: 489-94.
5. Freixinet J, Beltrán J, Rodríguez PM, Juliá G, Hussein M, Gil R et al. Indicators of severity in chest trauma. Arch Bronconeumol 2008; 44: 257-62.
6. Chen J, Jeremitsky E, Philp F, Fry W, Smith RS. A chest trauma scoring system to predict outcomes. Surgery 2014; 156: 988-94.
7. Sobrino J, Shafi S. Timing and causes of death after injuries. Proc (Bayl Univ Med Cent) 2013; 26: 120-3.
8. Richardson JD, Miller FB, Carrillo EH, Spain DA. Complex thoracic injuries. Surg Clin North Am 1996; 76: 725-48.
9. Toker A, Isitmangil T, Erdik O, Sancakli I, Sebit S. Analysis of chest injuries sustained during the 1999 Marmara earthquake. Surg Today 2002; 32: 769-71.
10. Sato K, Kobayashi M, Ishibashi S, Ueda S, Suzuki S. Chest injuries and the 2011 Great East Japan Earthquake. Respir Investig 2013; 51: 24-7.
11. Yi-Szu W, Chung-Ping H, Tzu-Chieh L, Dar-Yu Y, Tain-Cheng W. Chest injuries transferred to trauma centers after the 1999 Taiwan earthquake. Am J Emerg Med 2000; 18: 825-7.
12. Yoshimura N, Nakayama S, Nakagiri K, Azami T, Ataka K, Ishii N. Profile of chest injuries arising from the 1995 southern Hyogo Prefecture earthquake. Chest 1996; 110: 759-61.
13. Sehitogullari A, Kahraman A, Sayir F, Akın O, Sevilgen G, Cobanoglu U. Clinical profile of thorax and lung injuries associated with the 2011 Van earthquake in Turkey. Eur J Gen Med 2013; 10: 69-73.
14. Mahaseth R, Shah S, Kc R. Evaluation of Outcomes in Chest Trauma Patients using Chest Trauma Scoring System. J Universal Coll Med Sci 2022; 10: 3-8.
15. Elsaied Hussein MH, Fadl Mahmoud I, Ms Eita Y, Ahmed Aglan MA, Esmaiel MSA, Abdelshafy Ibrahim Farag G, et al. Prospective Study of Chest Trauma Scoring System as A Morbidity and Mortality Predictor in Patients with Blunt Chest Trauma. Med J Islam Repub Iran 2024; 38: 4.
16. Harde M, Aditya G, Dave S. Prediction of outcomes in chest trauma patients using chest trauma scoring system: A prospective observational study. Indian J Anaesth 2019; 63: 194-9.
17. Baby AT, Appukuttan A, Jothi H, Sajan R. Analysis of Scoring System to Identify High Risk Patients and their Outcome in Isolated Blunt Chest Trauma- A Prospective Observational Study. J Clin Diagn Res 2021; 15: PC06-PC10.
18. Bagaria V, Mathur P, Madan K, Kumari M, Sagar S, Gupta A et al. Predicting Outcomes After Blunt Chest Trauma - Utility of Thoracic Trauma Severity Score, Cytokines (IL-1β, IL-6, IL-8, IL-10, and TNF-α), and Biomarkers (vWF and CC-16). Indian J Surg 2021; 83: 113-9.
19. Mommsen P, Zeckey C, Andruszkow H, Weidemann J, Frömke C, Puljic P et al. Comparison of different thoracic trauma scoring systems in regards to prediction of post-traumatic complications and outcome in blunt chest trauma. J Surg Res 2012; 176: 239-47.
20. Subhani SS, Muzaffar M, Khan MI. Comparison of outcome between low and high thoracic trauma severity score in blunt trauma chest patients. J Ayub Med Coll Abbottabad 2014; 26: 474-7.
21. Ciflik KB, Beyoglu MA, Sahin MF, Mutlu SC, Yuce BRH, Yekeler E et al. Analysis of thoracic trauma patients transferred to Türkiye's largest hospital after Kahramanmaraş earthquake. Ulus Travma Acil Cerrahi Derg 2024; 30: 33-7.
22. Sever MS, Erek E, Vanholder R, Ozener C, Yavuz M, Kayacan SM et al. Lessons learned from the Marmara disaster: Time period under the rubble. Crit Care Med 2002; 30: 2443-9.
23. Askin MF, Tastemur S, Gedikli MA, Candan F, Koc Y. After the earthquakes with epicenter in Kahramanmaraş on February 6, 2023; crush syndrome. Cumhuriyet Med J 2024; 46: 1-7.
24. He YR, Hu H, Jiang YW, Hu JF, Li XH, Yao YC et al. Multivariate factors analysis on length of stay in Lushan earthquake victims. Sichuan Da Xue Xue Bao Yi Xue Ban 2014; 45: 633-6.
25. Sever MS, Erek E, Vanholder R, Akoglu E, Yavuz M, Ergin H et al. The Marmara earthquake: epidemiological analysis of the victims with nephrological problems. Kidney Int 2001; 60: 1114-23.

This article is an open access article distributed under the terms and conditions of the Creative Commons Attribution (CC BY) license (http://creativecommons.org/licenses/by/4.0/).

To cite this article: Yamansavci Sirzai E, Ozcibik Isik G, Cicek U, Kizir D, Turk Y, Sezen CB, Saydam O, Ucvet A. Prognostic value of the geriatric nutritional risk index in elderly patients undergoing surgery for early-stage non-small cell lung cancer. Curr Thorac Surg 2025;10(3):154-159.

Original Article

Prognostic value of the geriatric nutritional risk index in elderly patients undergoing surgery for early-stage non-small cell lung cancer

Esra Yamansavci Sirzai[1]*, Gizem Ozcibik Isik[2], Ufuk Cicek[1], Dilekhan Kizir[2], Yunus Turk[1], Celal Bugra Sezen[2], Ozkan Saydam[2], Ahmet Ucvet[1]

[1]Department of Thoracic Surgery, Dr. Suat Seren Chest Diseases and Thoracic Surgery Training and Research Hospital, İzmir, Türkiye
[2]Department of Thoracic Surgery, Yedikule Chest Diseases and Thoracic Surgery Training and Research Hospital, Istanbul, Türkiye

ABSTRACT

Background: The aim of this study was to evaluate the prognostic impact of the Geriatric Nutritional Risk Index (GNRI) on survival in patients aged 70 years and older who underwent surgery for early-stage non-small cell lung cancer (NSCLC).

Material and Methods: The study included 234 patients with pathological stage 1-2 who underwent surgery at two centers between 2007 and 2020 and who did not receive preoperative neoadjuvant therapy. Patients were divided into two groups based on age: 70-75 years (Group 1) and ≥75 years (Group 2). GNRI was calculated based on serum albumin level and body weight. The difference in survival between the groups was evaluated using Kaplan-Meier analysis, and the prognostic value of GNRI was evaluated using ROC analysis.

Results: No significant association was found between the GNRI value and overall survival (p = 0.506). However, in the ≥75 age group, the survival predictive potential of the GNRI was found to be moderate in ROC analysis (AUC = 0.638). The GNRI cut-off value for this group was determined as 55.7. No significant association was found between the GNRI and clinical parameters such as age, gender, or tumor stage.

Conclusions: The GNRI may be a potential biomarker for predicting survival, especially in NSCLC patients aged 75 and older. Preoperative nutritional support may improve clinical outcomes in patients with low GNRI values. The GNRI may contribute to personalized treatment decisions in the evaluation of elderly NSCLC patients.

Keywords: geriatric nutritional risk index, non-small cell lung cancer, elderly patients, survival, nutritional status, prognostic biomarker

Corresponding Author*: Esra Yamansavci Sirzai, MD. Department of Thoracic Surgery, Dr. Suat Seren Chest Diseases and Thoracic Surgery Training and Research Hospital, İzmir, Türkiye
Email: yamansavci@gmail.com Phone: +90 2324333333
Doi: 10.26663/cts.2025.026
Received 11.11.2025 accepted 12.12.2025

Introduction

Non-small cell lung cancer (NSCLC) constitutes approximately 85% of all lung cancers and is often diagnosed at an advanced stage [1]. Surgical resection remains the gold standard treatment for early-stage NSCLC. However, in elderly patients, factors such as diminished immune function, comorbidities, and limited physiological reserve complicate surgical decision-making. In recent years, advances in surgical techniques and more rigorous patient selection have rendered surgical treatment increasingly feasible in elderly patients with resectable NSCLC [2-4].

The identification of prognostic factors in NSCLC has gained prominence over time. A range of clinical parameters and biomarkers such as hemoglobin, lymphocyte and platelet counts, C-reactive protein (CRP), albumin levels, body mass index (BMI), and nutritional status have been proposed, and various composite indices have been utilized to enhance prognostic accuracy [5-7].

One such index is the Geriatric Nutritional Risk Index (GNRI), developed by Bouillanne et al. in 2005, which has been applied as a prognostic indicator in various malignancies [8,9]. The GNRI, calculated using serum albumin levels and body weight, is clinically valuable as it reflects both the nutritional status and systemic immune response of the patient [10,11]. Nevertheless, current literature lacks sufficient data on the prognostic value of GNRI specifically in elderly NSCLC patients [12].

The objective of this study is to evaluate the prognostic significance of GNRI in patients aged 70 years and older who underwent surgery for early-stage non-small cell lung cancer, and to assess its potential utility as a prognostic biomarker.

Materials and Methods

This retrospective study was conducted in two thoracic surgery centers between 2007 and 2020, following approval from the institutional ethics committee. The inclusion criteria were as follows: patients aged 70 years or older; those who underwent lung resection and systematic mediastinal lymph node dissection for non-small cell lung cancer (NSCLC); those classified as stage I–II according to the 8th edition of the TNM pathological staging system (T1N0–1M0, T2N0–1M0, T3N0M0); and patients with no history of preoperative neoadjuvant therapy.

Exclusion criteria comprised patients with a prior lung resection for indications other than NSCLC, those with locally advanced or metastatic disease (stage III–IV), patients with a history of neoadjuvant therapy, and individuals under the age of 70. A total of 234 patients met the eligibility criteria and were included in the study cohort.

Patients were stratified into two age-based subgroups: Group 1 (70-74 years) and Group 2 (≥75 years). The Geriatric Nutritional Risk Index (GNRI) was calculated using the following formula: GNRI = (1.487 × serum albumin concentration [g/L]) + (41.7 × [actual body weight / ideal body weight]). Ideal body weight was determined using the equation: Ideal body weight = 22 × (height in meters)^2 (16-19). In cases where the actual body weight exceeded the ideal body weight, the weight ratio was assigned a value of 1.

This study was approved by Ethics Committee of SBU, Dr. Suat Seren Chest Diseases and Thoracic Surgery Training and Research Hospital, (Approval date: 08.10.2025; Number: 2025/64-53).

Statistical Analysis

The distribution of group data was evaluated using the Shapiro-Wilk test. Depending on data normality, comparisons between groups were performed using either the Student's t- test or the Mann-Whitney U test. Categorical variables were analyzed using the Chi-square test. Survival analyses were conducted using Kaplan-Meier curves and Cox proportional hazards regression.

Receiver Operating Characteristic (ROC) curve analysis and the Youden index were employed to determine the prognostic value and optimal cut-off of the GNRI. All statistical analyses were performed using

SPSS version 27.0, and a p-value of <0.05 was considered statistically significant.

Results

Of the total cohort, 176 patients (20 females, 156 males) were aged between 70 and 75 years, while 58 patients (10 females, 48 males) were aged 75 years or older. There was no statistically significant difference between the two groups in terms of gender distribution (p = 0.246). The mean age of Group 1 was 72.1 ± 1.7 years, whereas the mean age of Group 2 was 78.1 ± 2.7 years (Table 1).

Lymphocytosis was found to be significantly lower in patients aged 75 years and above compared to the younger group (p = 0.048). Additionally, lobectomy was performed significantly more frequently in the ≥75 age group (p = 0.011) (Table 2).

No statistically significant differences were observed between the two age groups with respect to the Geriatric Nutritional Risk Index (GNRI), smoking history, hemoglobin levels, C-reactive protein (CRP) levels, pulmonary function parameters, or Charlson comorbidity index scores (Tables 2,3).

Similarly, there were no significant intergroup differences in tumor size, pathological nodal status, TNM stage (9), histopathological subtype, or the surgical approach used (VATS vs. thoracotomy) (Tables 2,3).

Survival analysis revealed no statistically significant difference in overall survival between the two age groups (p = 0.506). In Group 1 (<75 years), the median overall survival was 59.5 ± 4.3 months (95% CI: 51.0–68.0), while in Group 2 (≥75 years), it was 55.2 ± 5.8 months (95% CI: 43.8–66.5). The median follow-up duration for the entire cohort was 38.0 ± 1.8 months (Table 4, Figure 1).

When examining the effect of the geriatric nutritional index value on survival, the area remaining on the ROC curve in the group 75 years of age and older was 63.8% (95% CI: 44.9% - 82.7%). The cut-off value for the geriatric nutritional index in the group 75 years of age and older was 55.7 (Figure 2). GNRI's survival prediction is significant in the ≥75 age group, so the ROC analysis was conducted only in this subgroup.

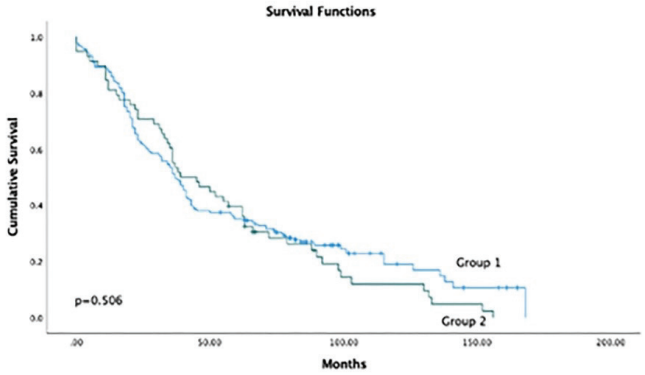

Figure 1. Kaplan–Meier survival curves comparing overall survival between patients aged 70-74 and ≥75 years.

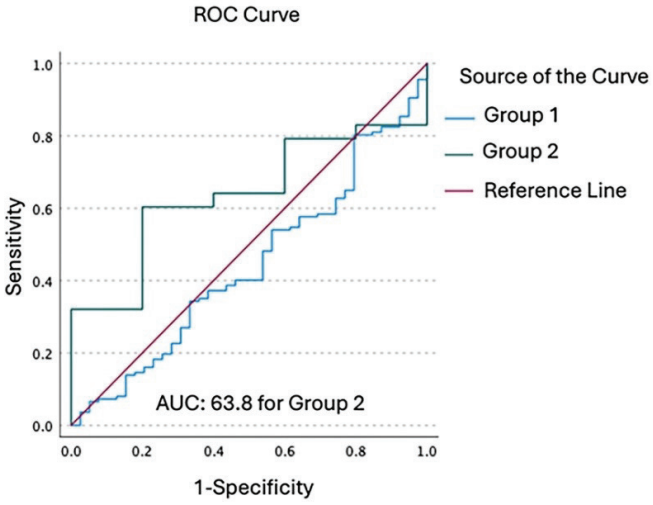

Figure 2. ROC curve analysis showing the predictive performance of the Geriatric Nutritional Risk Index (GNRI) for survival in patients aged ≥75 years.

Table 1. Baseline demographic characteristics of patients according to age group.

Variables	Group 1 (70-75 age) n=176	Group 2 (≥75 age) n=58	p value
Age	72.1 ± 1.7	78.1 ± 2.7	0.034
Gender -Female -Male	 20 (11.4 %) 156 (88.6 %)	 10 (17.2 %) 48 (82.8 %)	0.246 (OR:1.6) %95 CI:0.7-3.7

Table 2. Comparison of laboratory and physiological parameters between age groups.			
Variables	Group 1 (70-75 age) n=176	Group 2 (≥75 age) n=58	p value
GNI (Geriatric Nutritional Index)	55.8 ± 8.2	55.2 ± 6.2	0.256
Cigarette (Pack X year)	49.0 ± 31.9	41.8 ± 28.5	0.480
Tumor diameter (cm)	3.5 ± 1.5	3.6 ± 1.5	0.890
Weight (kg)	74.5 ± 12.9	75.0 ± 11.6	0.366
Height (cm)	168.6 ± 7.0	170.0 ± 7.6	0.536
Albumin	4.2 ± 0.5	4.1 ± 0.5	0.844
Lymphocyte	2.1 ± 1.7	1.8 ± 0.5	0.048
C-Reactive Protein	5.8 ± 11.9	3.1 ± 6.8	0.053
Hemoglobine	13.1 ± 1.7	13.0 ± 1.5	0.410
Platelet	271.8 ± 89.2	255.7 ± 77.6	0.718
Neutrophil	5.7 ± 2.7	6.3 ± 2.8	0.330
FEV1%	81.8 ± 18.2	80.8 ± 20.5	0.826
FEV1 (lt)	2.1 ± 0.5	2.8 ± 0.6	0.752
FVC%	81.9 ± 16.5	80.5 ± 21.7	0.322
FVC (lt)	2.8 ± 0.6	2.2 ± 0.5	0.902

Table 3. Comparison of clinicopathological characteristics between age groups.				
	Group 1 (70-75 age) n=176	Group 2 (≥75 age) n=58	p value	Odds Ratio %95 CI
pN0 pN1	146 30	53 5	0.119	0.5 (0.1-1.3)
Stage 1 Stage 2	102 74	36 22	0.581	
Side -Right -Left	 101 75	 29 29	0.326	 1.4 (0.7-2.4)
Resection -Lobectomy -Pneumonectomy	 152 (86.4%) 24	 57 (98.3%) 1	0.011	 0.1 (0.1-0.8)
Histopathology -Squamous cell carcinoma -Adenocarcinoma -Other pathology	 99 67 10	 33 19 6	0.422	 0.9 (0.8-1.3)
CCI 2 CCI 3	9 167	0 58	0.079	1.4 (1.3-1.5)
VATS Thoracotomy	62 114	22 36	0.710	0.9 (0.5-1.6)

Table 4. Comparison of survival outcomes between age groups.				
	Survival rate (%)	5 year median survival (Months)	95% CI	p value
Group 1 (70-75 age) n=176	22.2	59.5 ± 4.3	51.0 - 68.0	0.506
Group 2 (≥75 age) n=58	8.6	55.2 ± 5.8	43.8 - 66.5	

Discussion

In this study, we investigated the prognostic significance of the Geriatric Nutritional Risk Index (GNRI) in patients aged 70 years and older who underwent surgical resection for early-stage non-small cell lung cancer (NSCLC). ROC curve analysis revealed that the GNRI demonstrated a moderate predictive value for survival in patients aged 75 years and above, with an area under the curve (AUC) of 63.8%. Subgroup analysis identified a GNRI cut-off value of 55.7 in this older age group. These findings suggest that the GNRI may serve as a useful prognostic biomarker in the elderly population, particularly among patients aged 75 years and older.

Originally developed as a simple and practical tool to assess malnutrition, the GNRI has gained clinical utility due to its ease of calculation and its reflection of both nutritional and inflammatory status [8-12]. Previous studies have demonstrated the prognostic value of the GNRI in a variety of malignancies, including gastrointestinal cancers, hepatocellular carcinoma, and hematologic malignancies [8-11]. However, data specific to pulmonary malignancies, particularly in elderly cohorts, remain limited. Kinoshita et al previously reported that a low GNRI was associated with poorer survival outcomes in elderly patients with NSCLC, supporting its prognostic relevance in thoracic oncology [12].

Our findings further contribute to the existing literature by demonstrating the potential utility of the GNRI as a prognostic marker in elderly patients undergoing curative-intent surgery for early-stage NSCLC. Nevertheless, it is important to note that the relatively low tumor burden and systemic inflammation typically observed in early-stage disease may limit the prognostic strength of GNRI in this specific patient population. Moreover, the absence of statistically significant associations between GNRI and clinical variables such as age, sex, tumor stage, and histopathological subtype suggests that GNRI may function as an independent prognostic factor in elderly patients.

In surgical patients, poor nutritional status is associated with several adverse postoperative outcomes, including infectious complications, impaired wound healing, and delayed recovery [13,14]. In our study, a significant decrease in GNRI was detected in the over-75 age group, and its impact on survival was significantly impacted by the ROC curve. Nutrition is becoming increasingly difficult in our country, as it is worldwide, due to socioeconomic factors. This gap is particularly widening in older patients.

Limitations of the study

This study has several limitations. Primarily, its retrospective and multicenter design may have introduced variability in data collection and management, limiting the overall standardization of clinical parameters. In addition, the sample size, particularly in subgroup analyses, may not have been sufficient to detect smaller effect sizes. Prospective studies with larger, more homogeneous populations are warranted to validate our findings and further elucidate the prognostic role of GNRI in NSCLC.

Our findings suggest that malnutrition is a prognostic factor in older, early-stage lung cancer. However, due to the observational nature of this study, we were unable to definitively establish the relationship between nutritional status and surveillance. Recently, perioperative nutritional intervention has been recognized as part of a multidisciplinary approach to malnutrition prevention [15]. However, more well-designed prospective studies are needed to determine the impact of preoperative malnutrition treatment on prognosis.

In conclusion, the Geriatric Nutritional Risk Index appears to be a promising prognostic biomarker for elderly patients undergoing surgical treatment for NSCLC. Its predictive value was more pronounced in patients aged 75 years and older. In this context, nutritional interventions, including albumin replacement and dietary supplementation, may be considered in patients with a GNRI below the identified cut-off value of 55.7 prior to surgery. Incorporating the GNRI into preoperative assessment protocols could contribute to more personalized and risk- adapted treatment strategies in elderly NSCLC patients.

Declaration of conflicting interests

The authors declared no conflicts of interest with respect to the authorship and/or publication of this article.

Funding

The authors received no financial support for the research and/or authorship of this article.

Ethics approval

This study was approved by Ethics Committee of SBU, Dr. Suat Seren Chest Diseases and Thoracic Surgery Training and Research Hospital, (Approval date: 08.10.2025; Number: 2025/64-53).

Author contributions

Concept and Design: EYS, GOI, AU; Data Collection: UC, DK, YT; Analysis and Interpretation: CBS, OS; Drafting the Manuscript: EYS, GOI; Critical Revision: AU, CBS.

References

1. Jiang S, Yang A, Yang F, Zhu X, Chen X, Li Z et al. The geriatric nutritional risk index as a prognostic factor in patients treated with immune checkpoint inhibitors with non-small-cell lung cancer. J Thorac Dis 2024; 16: 5222-37.
2. Nojiri T, Omura A, Iede K, Katsushima U, Higashiyama M. Clinical impact of upfront dose reduction of the first cycle of first-line treatments on safety and survival in elderly patients with non-small cell lung cancer. Asia Pac J Clin Oncol 2025; e14203.
3. Wu GJ, Zhang Y, Liang R, Peng L, Zhang SH. Comparison of survival outcomes of early-stage non-small-cell lung cancer in elderly patients (≥ 70 years) treated with stereotactic body radiotherapy versus surgical resection. World J Surg 2025; 49: 1160-71.
4. Guo Q, He Y, Chen S, Hu S, Wang S, Su L et al. Development and validation of nomogram for predicting the cancer-specific survival among patients aged 80 and above with early-stage non-small cell lung cancer. ANZ J Surg 2025; 95: 106-16.
5. Liu XY, Zhang X, Zhang Q, Ruan GT, Liu T, Xie HL et al. The value of CRP-albumin lymphocyte index (CALLY index) as a prognostic biomarker in patients with non-small cell lung cancer. Support Care Cancer 2023; 31: 533.
6. Liu Q, Xie H, Cheng W, Liu T, Liu C, Zhang H et al. The preoperative hemoglobin, albumin, lymphocyte, and platelet score (HALP) as a prognostic indicator in patients with non-small cell lung cancer. Front Nutr 2024; 11: 1428950.
7. Wei L, Liu C, Wang S, Zhang H, Ruan G, Xie H et al. Sex differences in the obesity paradox of body compositions in non-small cell lung cancer. Nutrition 2025; 132: 112690.
8. Peng SM, Yu N, Ren JJ, Xu JY, Chen GC, Yang JR et al. The Geriatric Nutritional Risk Index as a prognostic factor in patients with advanced non-small-cell lung cancer. Nutr Cancer 2021; 73: 2832-41.
9. Bouillanne O, Morineau G, Dupont C, Coulombel I, Vincent JP, Nicolis I et al. Geriatric Nutritional Risk Index: a new index for evaluating at-risk elderly medical patients. Am J Clin Nutr 2005; 82: 777-83.
10. Hirabayashi T, Sonehara K, Ozawa R, Hachiya T, Nozawa S, Agatsuma T et al. Prognostic value of the Geriatric Nutritional Risk Index in previously untreated patients with advanced non-small cell lung cancer treated with a combination therapy of anti-PD-1/-PD-L1 antibodies and platinum-based chemotherapy: a multicenter retrospective study. Oncology 2024; 102: 819-27.
11. Matsuura S, Morikawa K, Ito Y, Kubota T, Ichijo K, Mochizuki E et al. The Geriatric Nutritional Risk Index and prognostic nutritional index predict the overall survival of advanced non-small cell lung cancer patients. Nutr Cancer 2022; 74: 1606-13.
12. Kinoshita R, Nakao M, Kiyotoshi H, Sugihara M, Kuriyama M, Takeda N et al. Geriatric Nutritional Risk Index as prognostic marker for elderly patients with small cell lung cancer. Cancer Diagn Progn 2024; 4: 482-8.
13. Lobo DN, Gianotti L, Adiamah A, Adam S, Argiles JM, Bischoff SC et al. Perioperative nutrition: recommendations from the ESPEN expert group. Clin Nutr 2020; 39: 3211-27.
14. Zhang X, Xiong Y, Xu A. A prognostic model of elderly patients with non-small cell lung cancer based on Geriatric Nutritional Risk Index. Zhongguo Fei Ai Za Zhi 2023; 26: 497-506.
15. Deeken F, Sanchez A, Rapp MA, Underwood MR, Rehm C, Brannstrom J et al. Outcomes of a delirium prevention program in older persons after elective surgery: a stepped-wedge cluster randomized clinical trial. JAMA Surg 2022; 157: e216370.

This article is an open access article distributed under the terms and conditions of the Creative Commons Attribution (CC BY) license (http://creativecommons.org/licenses/by/4.0/).

To cite this article: Yavuz H, Yılmaz F, Haşimoğlu F. Heterotopic supradiaphragmatic liver tissue mimicking a thoracic tumor: a diagnostic dilemma and VATS management. Curr Thorac Surg 2025;10(3):160-162.

Case Report

Heterotopic supradiaphragmatic liver tissue mimicking a thoracic tumor: a diagnostic dilemma and VATS management

Hasan Yavuz[1]*, Fatih Yılmaz[2], Fulden Haşimoğlu[3]

[1]Department of Thoracic Surgery, Mardin Training and Research Hospital, Mardin, Turkey
[2]Department of Pathology, Mardin Training and Research Hospital, Mardin, Turkey
[3]Department of Thoracic Surgery, Kızıltepe State Hospital, Mardin, Turkey

ABSTRACT

Heterotopic supradiaphragmatic liver tissue (HSLT) is an extremely rare condition, with about 30 cases documented in the literature since its first description. Because it often shows no symptoms and looks similar to pleural or parenchymal tumors on imaging, HSLT poses a significant diagnostic challenge. Although the cause remains unknown, a definitive diagnosis usually requires surgery. While conservative treatment is suitable for clinically confirmed cases, surgical exploration becomes necessary when malignancy cannot be ruled out. In such cases, the videothoracoscopic approach (VATS) is considered the gold standard for both diagnosis and treatment. Here, we report a case of HSLT discovered incidentally during imaging for acute appendicitis. We review the diagnostic difficulties and recommend VATS as the primary surgical option for unclear lesions above the diaphragm.

Keywords: choristoma, liver, thoracic surgery, video-assisted, diaphragm, incidental finding, diagnosis, differential

Corresponding Author*: Hasan Yavuz, MD. Mardin Training and Research Hospital, Thoracic Surgery Clinic, 4710, Mardin, Turkey.
E-mail: hasanyavuzdr@gmail.com Phone: +90 5452211780
Doi: 10.26663/cts.2025.027
Received 16.06.2025 accepted 18.08.2025

Introduction

The incidence of ectopic liver tissue is less than 0.5%, with the majority of cases detected in the abdomen [1]. Supradiaphragmatic presentation is exceptionally rare; since the first description by Hansbrough and Lipin [2], approximately 30 cases have been reported across various age groups. Supradiaphragmatic liver tissue is classified as an accessory liver lobe if connected to the liver parenchyma, or as ectopic (heterotopic) liver if no such connection exists [3]. Diagnosis is challenging due to the asymptomatic nature of the condition, leading to frequent incidental detection [4]. Herein, we present a case of heterotopic supradiaphragmatic liver tissue (HSLT) unconnected to the liver, identified incidentally during surgery for acute appendicitis.

Case Report

A 33-year-old non-smoker male presented with right flank pain. His medical history was significant for an appendectomy performed eight months prior, during which a thoracic lesion was incidentally detected but not surgically addressed. He also had a history of multinodular goiter and thyroiditis and was not on any active medication. Physical examination and laboratory findings were unremarkable.

Follow-up thoracic computed tomography (CT) confirmed a 12 mm nodular lesion in the lateral basal segment of the right lower lobe (Figures 1a,b). To further characterize the lesion, Positron Emission Tomography/Computed Tomography (PET/CT) was performed, which revealed a diaphragmatic pleural-based, smoothly circumscribed soft tissue nodule measuring 14 x 12 mm with a SUVmax of 2.2. Due to the suspicion of a pleural or parenchymal tumor, video-assisted thoracoscopic surgery (VATS) was planned. Surgical exploration revealed a purple-blue nodular lesion, approximately 15 mm in length, located on the diaphragm with a broad base and distinct from the lung parenchyma. The lesion was completely excised from the diaphragmatic pleura using an ultrasonic energy device. The postoperative course was uneventful, and the histopathological examination confirmed the diagnosis of heterotopic supradiaphragmatic liver tissue (HSLT) (Figures 2a-d). Written informed consent was obtained from the patient for publication of this case report and any accompanying images.

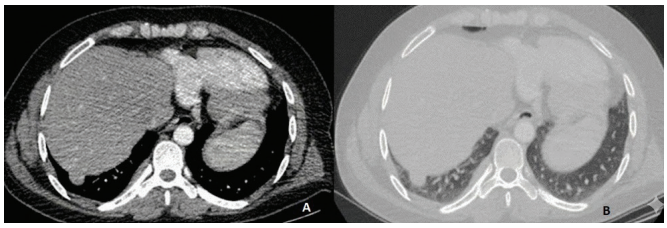

Figure 1. Axial chest CT scans demonstrating a 12mm nodular lesion located in the lateral basal segment of the right lower lobe. Mediastinal window view **(A)**, lung parenchymal window view **(B)**.

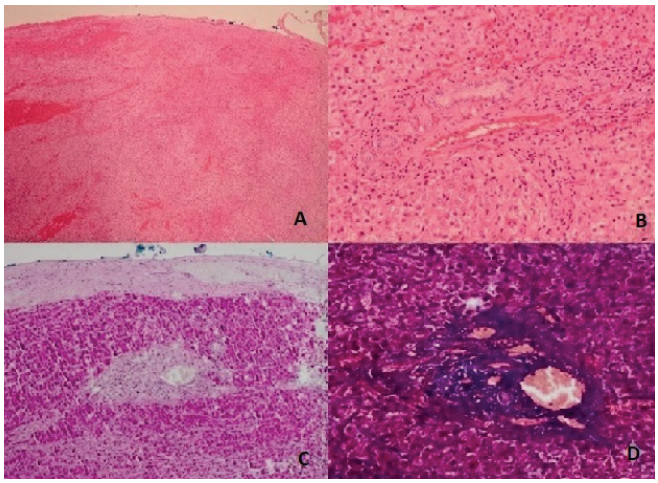

Figure 2. Histopathological evaluation of the resected specimen. Liver parenchyma exhibiting hemorrhagic changes encapsulated by fibrous tissue (H&E, x4) **(A)**, portal areas showing minimal inflammatory infiltration with accompanying hydropic degeneration in the adjacent parenchyma (H&E, x20) **(B)**, Periodic Acid-Schiff staining demonstrating positive hepatocellular glycogen accumulation (x10) **(C)**, Masson's Trichrome staining revealing mild fibrous expansion in select portal areas, corresponding to an ISHAK fibrosis score of 1 (x20) **(D)**.

Discussion

Heterotopic supradiaphragmatic liver tissue (HSLT) is an exceptionally rare entity with an obscure etiology. While often attributed to congenital abnormalities, instances secondary to trauma or surgical intervention have also been reported [5]. Clinically, its presentation varies by localization, frequently mimicking intrathoracic pathologies such as pleural or parenchymal tumors, pulmonary sequestration, or neurogenic tumors [6]. In the present case, the patient lacked any history of congenital disease, trauma, or relevant thoracic surgery. Although an appendectomy was noted in the patient's history, it was performed subsequent to the lesion's detection and was therefore unrelated. While HSLT can

be diagnostically challenging to distinguish from liver herniation, we definitively excluded herniation upon thoracoscopic exploration, which revealed a fully intact diaphragm and no evidence of traumatic sequelae.

The diagnosis of HSLT is complicated by the distinct absence of specific clinical symptoms. While frequently detected incidentally, the principal diagnostic challenge lies in establishing an accurate preoperative identification [7]. Radiological imaging remains the cornerstone of diagnosis. Although CT and PET/CT are instrumental in differentiating benign from malignant tumoral lesions, Magnetic Resonance Imaging (MRI) serves as a valuable adjunctive modality specifically for confirming the hepatic nature of the tissue [8]. In the present case, the patient was asymptomatic with no significant etiological history. The lesion was identified incidentally during imaging for acute appendicitis and was subsequently evaluated via PET/CT to rule out malignancy.

While existing literature documents the potential for HSLT to undergo malignant transformation to hepatocellular carcinoma or degenerate into cirrhosis, conservative management is generally preferred for asymptomatic patients with a definitive preoperative diagnosis. However, the radiological mimicry of HSLT to benign intrathoracic neoplasms often precipitates unwarranted surgical interventions [9]. Conversely, when preoperative diagnostic uncertainty persists, surgical exploration becomes imperative. In the present case, we proceeded with videothoracoscopic exploration and total excision, as the supradiaphragmatic lesion could not be definitively distinguished from potential diaphragmatic or parenchymal malignancies.

When surgical intervention is indicated, the videothoracoscopic approach (VATS) represents the gold standard. Despite the significant diagnostic challenges posed by the rarity and asymptomatic nature of HSLT, it must be considered in the differential diagnosis of supradiaphragmatic lesions. Therefore, rather than avoiding intervention, we advocate for the utilization of minimally invasive videothoracoscopic exploration to ensure accurate diagnosis and definitive management when uncertainty remains.

Declaration of conflicting interests

The authors declared no conflicts of interest with respect to the authorship and/or publication of this article.

Funding

The authors received no financial support.

Authors' contribution

HY; organized the article and wrote the paper, HY,FY; contributed to the data collection, HY,FY,FH; revised the article. All authors revised the manuscript. The authors read and approved the final manuscript.

References

1. Rodríguez Gómez CM, Baldó Padró X, Rubio Garay M. Ectopic Intrathoracic Liver Tissue. Arch Bronconeumol (Engl Ed) 2018; 54: 429.
2. Hansbrough ET, Lipin RJ. Intrathoracic accessory lobe of the liver. Ann Surg 1957; 145: 564-7.
3. An J, Han J, Lee KS, Choi YS. Supradiaphragmatic Heterotopic Liver Presenting as a Pleural Mass: A Case Report. Tuberc Respir Dis 2010; 69: 191-5.
4. Jhamb S, Pillai H, Maguire C, Palamuthusingam P. Incidental finding of heterotopic supradiaphragmatic liver. J Surg Case Rep 2020; 2020: rjaa394.
5. Paez SN, Schawkat K, Garces-Descovich A, Sawhney MS, Mortele KJ. Incidental finding of a supradiaphragmatic caudate lobe on cross-sectional imaging: An exceedingly rare entity. Clin Imaging 2020; 60: 79-83.
6. Bilen S, Sezen CB, Aker C, Kocatürk Cİ. A rare intrathoracic mass: Accessory liver lobe. Turk Gogus Kalp Damar Cerrahisi Derg 2019; 27: 411-3.
7. Wang Y, Junlin L, Zhang WG, Chen JH, He Y, Chen JM. Accessory lobe of right liver mimicking a pulmonary tumor in an adult male. Ann Thorac Surg 2010; 89: e9-e10.
8. Wang C, Cheng L, Zhang Z, Xie T, Ding H, Deng Q, et al. Accessory lobes of the liver: A report of 3 cases and review of the literature. Intractable Rare Dis Res 2012; 1: 86-91.
9. Chen YY, Huang TW, Chang H, Hsu HH, Lee SC. Intrathoracic caudate lobe of the liver: a case report and literature review. World J Gastroenterol 2014; 20: 5147-52.

This article is an open access article distributed under the terms and conditions of the Creative Commons Attribution (CC BY) license (http://creativecommons.org/licenses/by/4.0/).

Current Thoracic Surgery

To cite this article: Kahraman S, Ozdemir A, Bayraktar S, Demirhan R. Treatment of contralateral pneumothorax due to metastasis in a left pneumonectomy patient with single-port VATS. Curr Thorac Surg 2025;10(3):163-165.

Case Report

Treatment of contralateral pneumothorax due to metastasis in a left pneumonectomy patient with single-port VATS

Selime Kahraman[1]*, Attila Ozdemir[1], Saliha Bayraktar[2], Recep Demirhan[2]

[1]Department of Thoracic Surgery, Dr. Siyami Ersek Thoracic and Cardiovascular Surgery Training and Research Hospital, Istanbul, Turkey
[2]Department of Thoracic Surgery, Kartal Dr. Lütfi Kırdar City Hospital, Istanbul, Turkey

ABSTRACT

Spontaneous pneumothorax secondary to pulmonary metastasis is a rare but critical condition, particularly when it occurs in the single remaining lung of a patient who has undergone pneumonectomy. We present the case of a 62-year-old male with a history of left pneumonectomy for a malignant mesenchymal tumor who developed a right-sided pneumothorax one year postoperatively. Due to a persistent air leak resistant to tube thoracostomy, a chest CT was performed, revealing a subpleural metastatic lesion. The patient successfully underwent single-port Video-Assisted Thoracoscopic Surgery (VATS) wedge resection and apical pleurectomy under general anesthesia with transient apnea. This case highlights that despite the limited pulmonary reserve in pneumonectomized patients, single-port VATS offers a safe and effective approach for the definitive management of secondary pneumothorax caused by metastasis in the contralateral lung.

Keywords: pneumonectomy, pneumothorax, video-assisted thoracic surgery, lung neoplasms, neoplasm metastasis

Corresponding Author*: Selime Kahraman, MD. Dr. Siyami Ersek Thoracic and Cardiovascular Surgery Training and Research Hospital, Istanbul, Turkey.
E-mail: selimekahraman91@hotmail.com Phone: +90 5386174957
Doi: 10.26663/cts.2025.028
Received 26.07.2025 accepted 24.09.2025

Introduction

Spontaneous pneumothorax often develops due to bullae in the lungs. Pneumothorax secondary to pulmonary metastasis is a rare condition. In patients who have undergone pneumonectomy, a pneumothorax developing in the contralateral lung can be life-threatening. In such cases, in addition to emergency intervention, a permanent solution is also required. In recent years, Video-Assisted Thoracoscopic Surgery (VATS) has become a prominent treatment method in pneumothorax cases. In cases of prolonged air leaks due to pneumothorax, bullectomy and pleurectomy operations performed with VATS provide highly favorable outcomes [1].

Case Report

A 62-year-old male patient had undergone right arm amputation in 2015 due to a malignant mesenchymal tumor. In 2021, the patient underwent metastasectomy via left thoracotomy due to pulmonary metastasis. In 2022, a left pneumonectomy and mediastinal lymph node dissection were performed due to metastasis in the hilar region.

During follow-up, the patient presented with a sudden onset of dyspnea in the first postoperative year. A chest X-ray revealed pneumothorax on the right side (Figure 1), and an 8F catheter thoracostomy with closed underwater drainage was urgently applied. Preoperative echocardiogram showed an ejection fraction (EF) of 55%, and preoperative pulmonary function tests revealed an FEV1 of 82% and DLCO of 70%.

A chest CT scan was performed due to an air leak lasting for more than a week. The CT scan revealed a subpleural lesion in the right upper lobe consistent with metastasis (Figure 2). Because the lung metastasis was both solitary and peripheral, and the air leak had persisted for more than 10 days, surgery was decided.

The patient was intubated under general anesthesia with a single-lumen endotracheal tube. The ventilator was set to apnea mode during the procedure. A wedge resection and apical pleurectomy were performed using a single-port VATS.

The definitive pathology result was reported as lung metastasis of a mesenchymal tumor. The patient's chest drain was removed on postoperative day 3, and he was discharged in good health on day 5. No recurrence of pneumothorax was observed during the 2-year follow-up period. Written informed consent was obtained from the patient and his relatives for the publication of this case report.

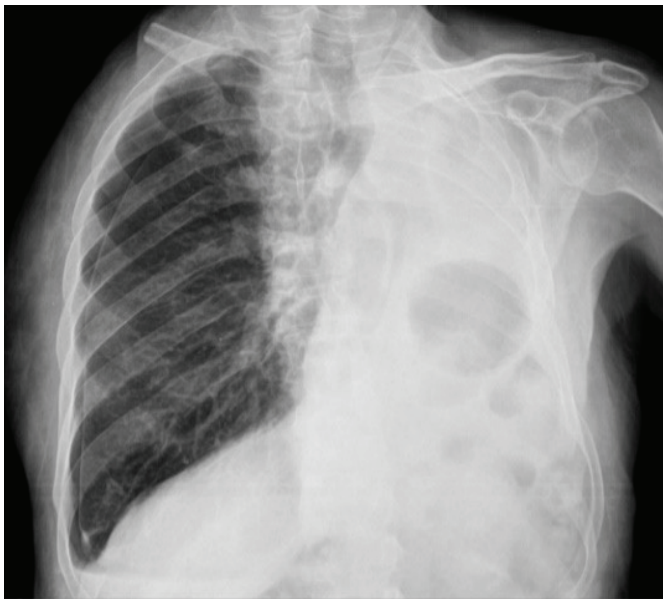

Figure 1. A chest X-ray demonstrated a right pneumothorax.

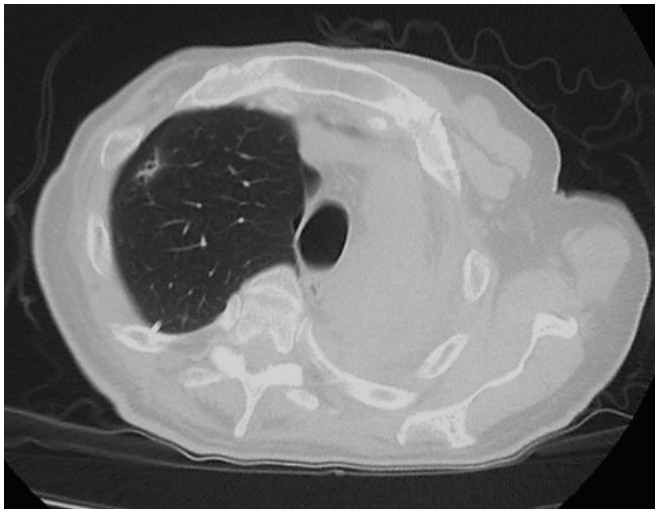

Figure 2. Chest CT performed due to persistent air leak, showing a peripheral metastatic nodule in the right upper lobe.

Discussion

The rate of complications following pneumonectomy procedures has been reported to range between 10% and 45% in various studies [2,3]. Pneumothorax developing in the contralateral lung has been reported in the literature as isolated cases [4,5]. Pneumothorax developing in the contralateral lung after pneumonectomy is a serious condition requiring emergency intervention. The first step should be the application of a tube thoracostomy to relieve the patient. In cases of persistent air leak following pneumothorax, surgical intervention becomes inevitable.

The time of onset of pneumothorax after pneumonectomy varies among studies. In the study by Orki et al, this interval ranged from 2 to 11 years [4]. In the

study by Matsuoka et al, it was reported as 15 days, 3 months, 1 year, and 3 years [5]. In our case, pneumothorax developed in the first year during follow-up. Since the timing of pneumothorax onset can vary and may span several years, careful follow-up of patients who have undergone pneumonectomy is essential.

In cases of dyspnea or chest pain, the possibility of pneumothorax in the contralateral lung must always be considered.

There is no consensus on the nature of surgeries to be performed on the contralateral lung after pneumonectomy. Discussions continue regarding which patients are suitable candidates for such procedures. The general agreement in studies is that surgical intervention can be applied to the contralateral lung in pneumonectomized patients with adequate pulmonary and cardiac reserve [5,6]. Jeon GH et al, in a study involving 13 patients, addressed this issue and reported that, following pneumonectomy, 10 patients underwent single wedge resection, 2 underwent double wedge resection, and 1 patient underwent lobectomy. In that study, complications occurred in 4 patients (36%), and no mortality was reported [6].

In this case, due to the persistent air leak and presence of metastasis in the contralateral lung, wedge resection and pleurectomy were performed using single-port VATS. During the procedure, the lungs were placed in apnea mode on the ventilator. Our patient, who had sufficient lung reserve and no cardiac issues, experienced no complications during or after the procedure.

During the 2-year postoperative follow-up period, no recurrence was observed. The patient remains under regular surveillance with biannual visits.

In conclusion, secondary pneumothorax due to metastatic lung cancers, although rare, may occur. In this patient group with limited respiratory reserve, both initial and definitive interventions can be rapidly performed using minimally invasive methods, yielding successful outcomes. This case highlights that single-port VATS can be a safe and effective option for managing contralateral pneumothorax in patients with limited pulmonary reserve, providing both rapid and definitive treatment.

Declaration of conflicting interests

The authors declared no conflicts of interest with respect to the authorship and/or publication of this article.

Funding

The authors received no financial support.

Authors' contribution

SK; organized the article and wrote the paper, AO,SB; contributed to the data collection, SB,RD; revised the article. All authors revised the manuscript. The authors read and approved the final manuscript.

References

1. Demir M, Akın M, Kaba M, Filiz S, Sever N, Karadağ CA et al. Thoracoscopic Resection in the Treatment of Spontaneous Pneumothorax. Med Bull Sisli Etfal Hosp 2020; 54: 94-7.
2. Marret E, Miled F, Bazelly B, El Metaoua S, Montblanc J, Quesnel C et al. Risk and protective factors for major complications after pneumonectomy for lung cancer. Interact. Cardiovasc Thorac Surg 2010; 10: 936-9.
3. Grapatsas K, Menghesha H, Dörr F, Baldes N, Schuler M, Stuschke M et al. Pneumonectomy for Primary Lung Tumors and Pulmonary Metastases: A Comprehensive Study of Postoperative Morbidity, Early Mortality, and Preoperative Clinical Prognostic Factors. Curr Oncol 2023; 30: 9458-74.
4. Orki A, Tasci EA, Meydan B, Kutlu CA. Video-assisted thoracoscopy for spontaneous 97 pneumothorax after pneumonectomy. Heart Lung Circ 2009; 18: 299-301.
5. Matsuoka K, Ito A, Murata Y, Kuwata T, Takasaki C, Imanishi N et al. Four Cases of Contralateral Pneumothorax After Pneumonectomy. Ann Thorac Surg 2014; 98: 1461-3.
6. Jeong GH, Choi YS, Jeon YJ, Lee J, Park YS, Cho JH et al. Contralateral Pulmonary Resection after Pneumonectomy. J Chest Surg 2024; 57: 145-51.

This article is an open access article distributed under the terms and conditions of the Creative Commons Attribution (CC BY) license (http://creativecommons.org/licenses/by/4.0/).

To cite this article: İşevi C, Pirzirenli MG, Doğan FB, Süllü Y, Çelik B. Pleural capillary hemangioma mimicking traumatic hematoma: a rare case of massive hemorrhagic effusion. Curr Thorac Surg 2025;10(3):166-169.

Case Report

Pleural capillary hemangioma mimicking traumatic hematoma: a rare case of massive hemorrhagic effusion

Caner İşevi[1]*, Mehmet Gökhan Pirzirenli[1], Feyza Bahar Doğan[1], Yurdanur Süllü[2], Burçin Çelik[1]

[1]Department of Thoracic Surgery, School of Medicine, Ondokuz Mayis University, Samsun, Turkey
[2]Department of Pathology, School of Medicine, Ondokuz Mayis University, Samsun, Turkey

ABSTRACT

Pleural capillary hemangiomas are exceptionally rare vascular tumors that may present with massive pleural effusion, often mimicking traumatic hematoma or malignancy. Due to nonspecific clinical features and inconclusive imaging, diagnosis is often delayed. We present a 52-year-old woman with progressive dyspnea and left-sided pleural effusion. Imaging revealed a pleural-based lesion, but malignancy was not confirmed by cytology or bronchoscopy. Video-assisted thoracoscopic surgery and histopathology confirmed capillary hemangioma. Surgical excision led to full recovery without recurrence. This case underscores the importance of considering benign vascular tumors in the differential diagnosis of unexplained pleural effusions.

Keywords: capillary hemangioma, pleura, pleural effusion, video-assisted thoracoscopic surgery, differential diagnosis

Corresponding Author*: Caner İşevi, M.D. Department of Thoracic Surgery, School of Medicine, Ondokuz Mayis University, Kurupelit, Samsun, TR55139, Turkey.
E-mail: drcanerisevi@gmail.com Phone: +90 3623121919/4240
Doi: 10.26663/cts.2025.029
Received 01.08.2025 accepted 30.09.2025

Introduction

Pleural capillary hemangioma is a benign vascular neoplasm originating from the pleural surface and is rarely encountered in clinical practice. Hemangiomas are more commonly seen in superficial soft tissues but can occasionally arise within the thoracic cavity, leading to diagnostic challenges [1]. When located in the pleura, these tumors may present with nonspecific respiratory symptoms and imaging findings suggestive of hematoma or malignancy [2,3].

Due to their rarity and ambiguous radiologic appearance, pleural hemangiomas are frequently misdiagnosed or diagnosed late, often requiring histopathological confirmation through surgical excision [2]. In this report, we present a case of pleural capillary hemangioma that mimicked a traumatic hematoma due to hemorrhagic effusion and radiologic features, ultimately diagnosed and successfully treated via video-assisted thoracoscopic surgery (VATS).

Case Report

A 52-year-old woman with hypothyroidism presented with progressive dyspnea lasting two to three months. She had no history of trauma. Physical examination revealed diminished breath sounds in the lower left lung zone. Laboratory findings included leukocytosis (12,500/μL), hemoglobin of 12.3 g/dL, and elevated CRP (8.3 mg/L). Pleural fluid analysis revealed an exudate with a leukocyte count of 1,376/μL and the growth of Staphylococcus aureus. Thoracic CT revealed a 35 × 20 mm heterogeneously dense lesion at the level of the left 5th–6th ribs with compressive atelectasis in the left lower lobe (Figure 1a). PET-CT demonstrated focal FDG uptake (SUVmax: 10.6) in the lingular segment after chest tube insertion and fluid drainage, likely related to chest tube–associated inflammation, while the pleural-based lesion on thoracic CT showed no FDG avidity (Figure 1b). However, retrospective evaluation suggested that this uptake may have been related to inflammation or the presence of the previously inserted chest tube, rather than the pleural lesion itself. The lesion identified on CT was not FDG-avid. Bronchoscopy and bronchoalveolar lavage cytology showed no abnormalities.

Due to the unresolved effusion and unclear etiology, VATS was planned. Under general anesthesia and single-lung ventilation, approximately 800 mL of serohemorrhagic pleural fluid was aspirated. A 2 × 2 cm cystic lesion was identified on the posterior thoracic wall at the level of the 6th intercostal space and was completely resected. Frozen section analysis indicated lymphoid tissue. Partial decortication was performed, and a 32 Fr chest tube was inserted.

The patient was discharged on the 5th postoperative day without complications. During follow-up, she reported no recurrence of dyspnea. Follow-up thoracic CT showed no pleural effusion and complete resolution of atelectasis. Sections prepared from the thoracic tissue specimen showed a lesion characterized by proliferation of thin-walled vascular structures within soft tissue areas partially covered by mesothelial lining, alongside a fibrinous blood clot. Erythrocytes were observed within some vascular lumens. To support the diagnosis, immunohistochemical analysis was performed using CD31, ERG, Fli-1, CD34, WT-1, pancytokeratin, PHH3, and Ki67. These findings were consistent with a capillary hemangioma. (Figures 2a-c). As of the most recent follow-up in April 2022, the patient remained clinically stable with no evidence of recurrence.

Written informed consent was obtained from the patient for publication of this case report and any accompanying images.

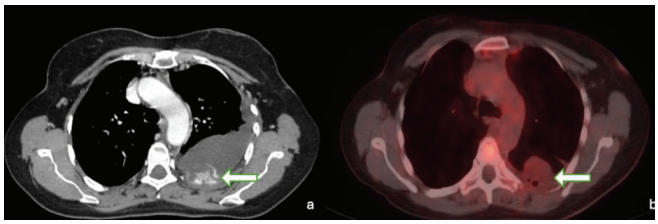

Figure 1. Axial thoracic CT **(a)**, and fused PET-CT **(b)** images showing a pleural-based lesion (green arrows) adjacent to the left posterior thoracic wall. The lesion is visible on both modalities; however, no significant FDG uptake was detected in PET-CT.

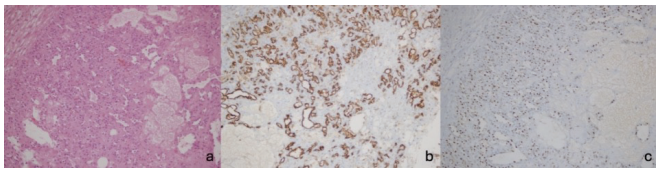

Figure 2. Histopathological appearance of the excised lesion. Lobular proliferation of thin-walled capillary vessels in fibrous stroma (H&E, ×200) **(a),** immunohistochemical positivity for CD31 **(b),** and ERG **(c)** confirms vascular endothelial origin (×200 each).

Discussion

Capillary hemangiomas are benign vascular neoplasms composed of capillary-sized blood vessels lined by a single layer of endothelial cells. While commonly seen in the skin and mucosa, their presentation within the thoracic cavity, especially from the pleural surface, is exceedingly rare. The pathogenesis of pleural hemangiomas remains unclear but may involve congenital vascular malformations or acquired proliferative stimuli in the pleural microvasculature [1,2].

Clinical manifestations are often nonspecific. Patients may present with symptoms such as dyspnea, cough, or pleuritic chest pain due to unilateral pleural effusion, which can be serous or hemorrhagic. The etiology of such effusions is frequently misattributed to malignancy, infection, or trauma. In our case, despite the hemorrhagic nature of the effusion and hypermetabolic findings on PET-CT, repeated cytological examinations and bronchoscopic evaluations failed to establish a diagnosis, consistent with other reported cases where non-invasive modalities proved inconclusive [2,3].

Radiological findings also pose a challenge. CT may show pleural thickening or nodularity, while PET-CT can demonstrate increased metabolic activity. In our patient, the lingular lesion demonstrated intense FDG uptake, which typically raises suspicion for malignancy but can also be observed in benign vascular tumors due to high endothelial turnover [4]. Such overlap necessitates histopathological confirmation. In our case, although PET-CT showed increased FDG uptake, this did not correspond to the excised lesion. The uptake was likely attributable to reactive changes near the chest tube site, rather than the capillary hemangioma itself, which was not FDG-avid. This highlights a potential pitfall in interpreting PET-CT findings in the context of inflammation or recent interventions.

Surgical exploration remains both diagnostic and therapeutic. In this case, VATS allowed direct visualization and excision of the lesion, which appeared cystic and hemorrhagic. Frozen section analysis suggested lymphoid tissue, but definitive diagnosis required permanent sections. Histopathology demonstrated tightly packed capillary vessels, confirming a capillary hemangioma. In our case, immunohistochemical staining including CD31, CD34, ERG, Fli-1, WT-1, pancytokeratin, PHH3, and Ki67 supported the diagnosis of capillary hemangioma and excluded malignancy [3,5].

Embryologically, pleural capillary hemangiomas are thought to arise from congenital vascular malformations of mesodermal origin, although acquired proliferative changes in the pleural microvasculature have also been suggested [1,3]. Their true incidence is extremely low; to date, only a handful of cases have been published, mostly as single case reports or small series [6,7]. Because of this rarity and nonspecific presentation, pleural hemangiomas are often misdiagnosed as traumatic hematoma, empyema, or malignant pleural disease, resulting in delayed treatment [1,3].

Differential diagnosis of vascular tumors in the pleura includes more aggressive entities such as hemangioendothelioma, angiosarcoma, or even metastatic disease, especially when imaging features are ambiguous. In particular, epithelioid hemangioendothelioma can present similarly but carries a worse prognosis and typically requires systemic therapy [8].

Management depends on tumor resectability and clinical symptoms. Surgical excision is curative in most reported cases, with low recurrence and excellent prognosis [2,4].

The current case adds to the limited but growing body of literature describing pleural capillary hemangiomas as an important, albeit rare, cause of unexplained or recurrent pleural effusion. Our findings reinforce the value of early surgical intervention when noninvasive methods fail and highlight the importance of considering benign vascular tumors in the differential diagnosis of PET-positive pleural lesions.

Intraoperative VATS and macroscopic/wound photographs could not be obtained due to equipment malfunction at the time of surgery; this absence is a limitation of the present report.

In conclusion, pleural capillary hemangioma should be considered in the differential diagnosis of recurrent or massive pleural effusion of unclear etiology, particularly when malignancy or trauma are excluded. Surgical excision is both diagnostic and therapeutic, with favorable outcomes. Early recognition and multidisciplinary evaluation are essential for appropriate management.

Declaration of conflicting interests

The authors declared no conflicts of interest with respect to the authorship and/or publication of this article.

Funding

The authors received no financial support.

Authors' contribution

Cİ: Conceptualization, Methodology, Supervision, Writing – original draft, Writing – review & editing. MGP: Writing – original draft, Visualization, Writing – review & editing. FBD: Data curation, Investigation, Writing – original draft. YS: Histopathological analysis, Immunohistochemical evaluation, Validation. BÇ: Validation, Supervision, Writing – review & editing.

References

1. Akagi K, Matsutake T, Fukushima K, Mukae H, Kurohama H, Matsumoto H. A refractory pleural effusion caused by a pleural capillary hemangioma. Respir Med Case Rep. 2021; 33: 101384.
2. Sota Yoldi LA, Vigil Vigil L, Arceo Solis R. Pleural effusion caused by a capillary hemangioma in the pleural cavity. Arch Bronconeumol 2016; 52: 537-9.
3. Hashimoto N, Takenaka S, Akimoto Y, Tanaka H, Morii E, Minami M et al. Capillary hemangioma in a rib presenting as large pleural effusion. Ann Thorac Surg 2011; 91: e59-61.
4. Jacob B, Ben-Arie G, Samueli B, Azulay A. Pleural hemangioma: A case report and review of the literature. Pathol Res Pract 2021; 228: 153650.
5. Patel G, Agrawal S, Patil P. Intrathoracic hemangioma. J Cancer Res Ther 2020; 16: 938-40.
6. Nie N, Liu Z, Kang J, Li L, Cao G. Multifocal pleural capillary hemangioma: a rare cause of hemorrhagic pleural effusion-case report. BMC Pulm Med 2021; 21: 15.
7. Fuentes F, Rubio E, Ie S. A rare case of a mediastinal mass with recurrent pleural effusion. Am J Respir Crit Care Med 2021; 203: A1933.
8. Pateras IS, Kostopanagiotou K, Samaras MG, Koumarianou A, Koutrouli M, Korodimos N et al. Rare cancer with primary pleural epithelioid hemangioendothelioma diagnosed by thoracoscopic biopsy achieving disease control after 16 months: case report and literature review. Front Pharmacol 2024; 15: 1482154.

This article is an open access article distributed under the terms and conditions of the Creative Commons Attribution (CC BY) license (http://creativecommons.org/licenses/by/4.0/).

To cite this article: Kazar M, Kurak TU, Ekinci FB, Köksel MO. Bronchobiliary fistula causing gallstone formation in lung parenchyma: a rare case report. Curr Thorac Surg 2025;10(3):170-174.

Case Report

Bronchobiliary fistula causing gallstone formation in lung parenchyma: a rare case report

Mustafa Kazar*, Tibet Uğur Kurak, Fatma Bağrıaaçık Ekinci, Mehmet Oğuz Köksel

Department of Thoracic Surgery, Faculty of Medicine, Mersin University, Mersin, Turkey

ABSTRACT

Bronchobiliary fistula (BBF) is a rare condition characterized by an abnormal communication between the biliary tract and the bronchial tree. In developing countries, it most commonly occurs as a complication of hepatic hydatid cysts or amebic liver abscesses, whereas in developed countries, it is more frequently associated with trauma or previous biliary surgery. Bilioptysis, defined as the expectoration of bile-stained sputum, is a pathognomonic symptom observed in most patients. The diagnostic and therapeutic management of BBF requires a multidisciplinary and patient-specific approach, beginning with noninvasive or minimally invasive procedures and sometimes requiring major surgical intervention. This case is remarkable because, despite clinical findings suggestive of BBF, preoperative imaging failed to demonstrate the fistulous tract. Moreover, the intraoperative discovery of gallstones within a destructed lung parenchyma makes this case exceptionally rare.

Keywords: bronchobiliary fistula, gallstones, bilioptysis, lung diseases, thoracic surgery

Corresponding Author*: Mustafa Kazar, MD. Department of Thoracic Surgery, Faculty of Medicine, Mersin University, Mersin, Turkey.
E-mail: mustafa.kazar@gmail.com Phone: +90 5317915335
Doi: 10.26663/cts.2025.030
Received 23.08.2025 accepted 25.10.2025

Introduction

Bronchobiliary fistula (BBF) is a rare condition characterized by an abnormal communication between the biliary tract and the bronchial system. It was first described by Thomas Bevill Peacock in 1950 [1]. BBF may develop as a complication following surgical procedures such as hepatic hydatid cyst surgery, cholelithiasis, choledocholithiasis, malignancy, or peptic ulcer surgery, and it may also occur secondary to congenital malformations [2]. Patients most commonly present with the pathognomonic symptom of coughing up bile-stained sputum (bilioptysis). Other nonspecific symptoms such as abdominal pain, fever, and dyspnea may also accompany this presentation [3,4].

A variety of imaging modalities can be utilized for diagnosis, including computed tomography (CT), bronchoscopy, magnetic resonance cholangiopancreatography (MRCP), endoscopic retrograde cholangiopancreatography (ERCP), hepatobiliary iminodiacetic acid (HIDA) scintigraphy, and endoscopic ultrasonography [5,6]. CT is valuable for assessing the lung and hepatic parenchyma, while bronchoscopy allows direct visualization of bile-stained secretions in the bronchial tree. MRCP is superior to CT in delineating the biliary system and identifying the fistulous tract. ERCP, though invasive, enables direct visualization of the biliary tree and allows stent placement for simultaneous diagnosis and treatment [7].

Management should be tailored to the etiology, fistula size, patient's overall condition, and associated disease. Endoscopic biliary stenting via ERCP is usually the first-line treatment to divert bile away from the fistulous tract. However, in cases of persistent bile leakage due to obstruction or hypersecretion, surgical intervention may be necessary. The main surgical principle is to identify and close the fistulous tract [6]. Herein, we present the diagnostic and therapeutic approach in a 54-year-old male patient operated for BBF, highlighting the clinical challenges encountered in management.

Case Report

The patient was first operated on in 2015 at an external center for a perforated hepatic hydatid cyst. In 2021, he developed bilioptysis and underwent ERCP, during which a stent was placed in the common bile duct, resulting in symptomatic improvement. Two years later, gallstones were detected, and cholecystectomy was performed, with simultaneous removal of the biliary stent. One year later, the recurrence of bilioptysis prompted repeat ERCP and re-stenting. As the symptoms persisted, the patient was referred to our clinic.

Retrospective evaluation of imaging studies did not reveal a distinct fistulous tract. Thoracoabdominal CT showed destructive changes in the right lower lobe, without clear visualization of the fistula, and the report stated: "Destructive parenchymal areas in the right lower lobe; no definite fistula observed; bronchobiliary fistula cannot be excluded" (Figure 1).

Bronchoscopy was performed after obtaining informed consent. Findings included mucosal hyperemia in the right intermediate bronchus and yellow-green secretions from the right lower lobe bronchi (Figure 2). Biochemical analysis of bronchoalveolar lavage fluid confirmed bilirubin, while cytology excluded malignancy.

The multidisciplinary team (general surgery, gastroenterology, thoracic surgery) recommended MRCP to evaluate the biliary system. MRCP did not clearly show a fistulous tract; however, the presence of contrast at the diaphragmatic level made exclusion of BBF impossible (Figure 3).

The patient was re-evaluated by the multidisciplinary council. Considering the possibility of dense adhesions between the lung parenchyma and diaphragm, the feasibility of direct evaluation of the fistulous tract via open thoracotomy, and the absence of any suspicion of malignancy, a parenchyma-sparing surgical procedure was planned. Written informed consent was obtained from the patient and his relatives prior to the operation.

During right thoracotomy and exploration, dense adhesions were observed between the right lower lobe and the diaphragm at the level of the fistulous tract; however, these adhesions could not be completely released. A localized area of lung injury was detected in the distal portion of the right lower lobe, while the remaining parts of the lobe appeared intact. Therefore, the region containing the fistulous tract and the surrounding destructed lung tissue was resected from the parenchyma by wedge resection using two separate cutting and stapling devices. A small portion of the diaphragm adjacent to the fistulous site was also excised and sent for histopathological examination (Figure 4). The dia-

phragmatic defect was repaired primarily. Macroscopic examination of the resected specimen revealed the presence of a gallstone within the lung parenchyma (Figure 5). After hemostasis and air-leak control were achieved, two chest tubes were placed in the thoracic cavity, and the thoracotomy incision was closed in layers according to anatomical planes.

Postoperatively, thoracic drains were removed on days 2 and 5. On day 7, yellowish serous discharge appeared at the incision. Upon reopening under local anesthesia, a large amount of yellow-green fluid resembling bile was drained. Vacuum-assisted closure (VAC) therapy and tube thoracostomy were applied. Biochemical analysis confirmed high bilirubin concentration. By day 5 of follow-up, drainage had ceased, and the tube was removed.

Repeat ERCP revealed an obstructed stent, which was removed. The patient underwent laparotomy for exploration of subdiaphragmatic tracts. Two tracts containing gallstones were identified in hepatic segments VII–VIII, and the diaphragmatic openings were closed.

Postoperatively, bilioptysis resolved completely. The thoracotomy wound was managed with VAC changes for 14 days under local anesthesia and closed anatomically. The patient achieved full recovery and was discharged. During outpatient follow-up, no recurrence of symptoms was observed.

Written informed consent was obtained from the patient for publication of this case report and any accompanying images.

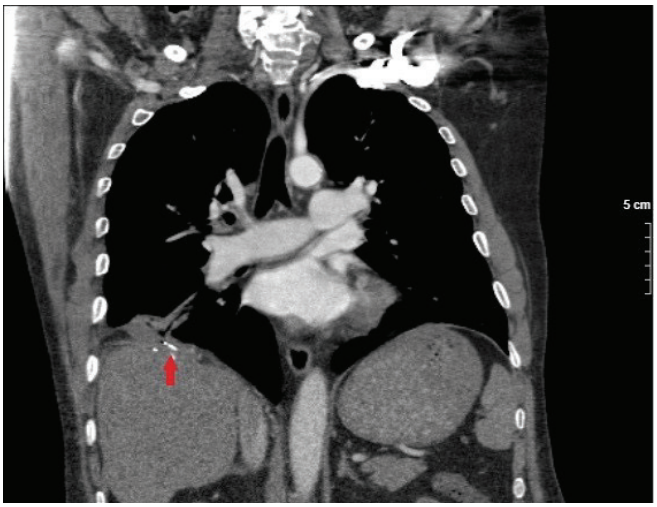

Figure 1. Thoracic CT demonstrating contrast material image at the level of the right diaphragm (area indicated by the arrow).

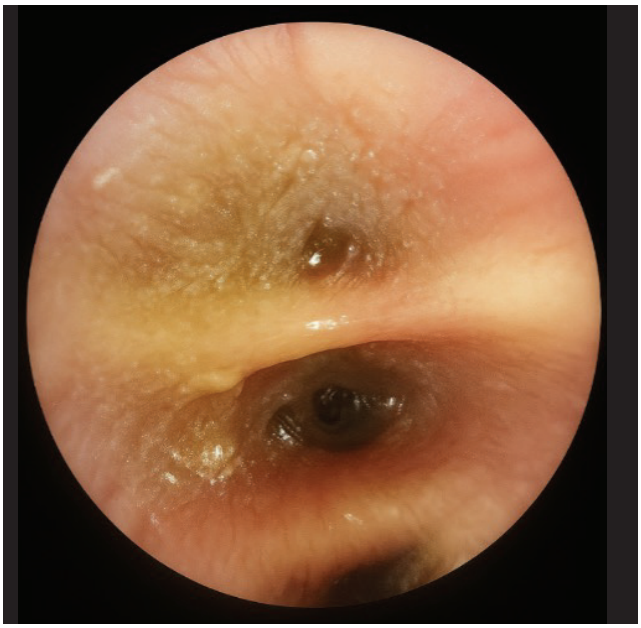

Figure 2. Visualization of bile-stained secretions during bronchoscopy.

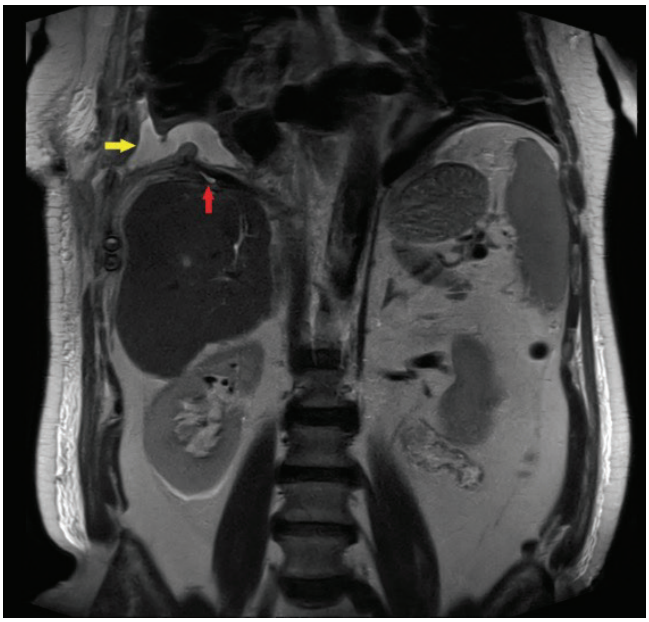

Figure 3. MRCP showing contrast material image at the level of the right diaphragm (red arrow) and right pleural effusion (yellow arrow).

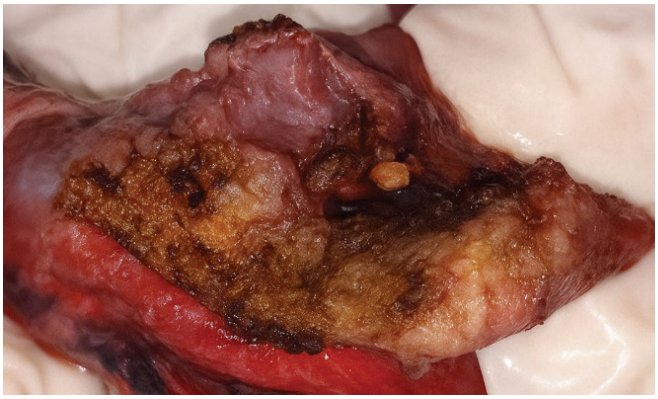

Figure 4. Resected destructive lung parenchyma specimen obtained by wedge resection.

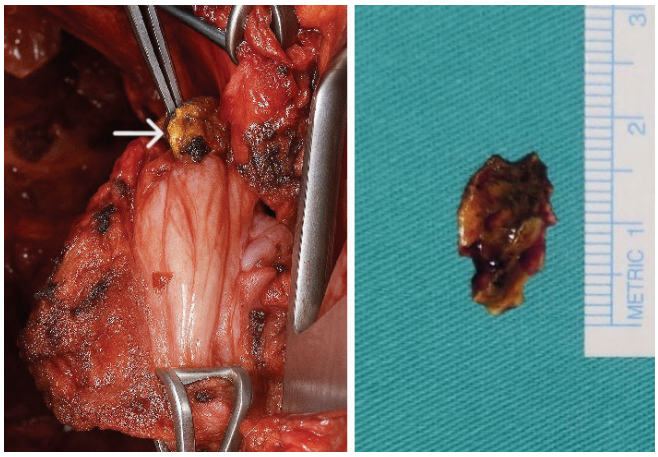

Figure 5. Intraoperative image showing a gallstone within the lung parenchyma (left) and the excised gallstone specimen (right).

Discussion

BBF is a rare pathological condition characterized by an abnormal communication between the biliary system and the bronchial tree [1]. Several mechanisms have been proposed to explain the development of BBF. The most widely accepted theory suggests that an inflammatory process arising in the subdiaphragmatic region or within the hepatic parenchyma causes erosion of the diaphragm, thereby establishing an abnormal connection between the biliary ducts and the bronchial system [5].

Historically, infectious etiologies particularly hydatid disease and pyogenic abscesses have been reported as the most common causes of BBF. In recent years, however, a marked increase has been observed in secondary cases associated with surgical interventions and their complications [4]. Among these, minimally invasive procedures such as transarterial chemoembolization (TACE) and radiofrequency ablation (RFA), which are frequently used in the treatment of hepatic tumors, have emerged as new etiological factors [6]. In our case, BBF developed following liver surgery, demonstrating characteristics similar to those reported in the literature for postoperative cases.

When bile leaks outside the biliary system or gastrointestinal tract, it exerts a strong irritant effect on surrounding tissues. Consequently, irritative cough and bilioptysis are considered pathognomonic findings of BBF [5]. The presence of bilioptysis and elevated bilirubin levels in sputum are valuable biochemical indicators for early diagnosis [8]. In our patient, cough, bilioptysis, and significantly elevated bilirubin levels in bronchoalveolar lavage samples were consistent with the diagnosis of BBF and in agreement with the findings in the literature.

Due to its rarity, there is no universally accepted diagnostic or therapeutic protocol for BBF. At present, curative treatment strategies are generally divided into two main categories: minimally invasive techniques and surgical interventions [9]. The most frequently used minimally invasive approach is ERCP with biliary stent placement. In addition, newer techniques such as ERCP-guided coil embolization and bronchoscopic histoacryl injection have been reported to yield favorable outcomes [6,8].

Physiologically, the basal pressure of the sphincter of Oddi is higher than that of the common bile duct, while intrathoracic pressure is lower than intra-abdominal pressure. These pressure differences facilitate the movement of bile toward the bronchial system in the presence of a fistulous tract [6]. By placing a stent in the common bile duct via ERCP, bile flow is redirected toward the duodenum, effectively eliminating bile drainage through the fistulous tract. This results in symptom regression and may allow for spontaneous fistula closure. However, stent obstruction or excessive bile production can lead to inadequate drainage, resulting in symptom recurrence and the need for surgical intervention [5].

Surgical treatment options include laparatomy, thoracotomy, thoracoabdominal approach. When planning surgery, careful assessment of the etiology, location, size of the fistula, and the extent of tissue injury caused by bile is essential. A multidisciplinary approach is crucial for accurate decision-making and improved treatment outcomes [10].

In this case, despite adequate biliary drainage, persistent symptoms and the development of parenchymal destruction in the lung necessitated surgical intervention. At this stage, the specific surgical approach was determined following a multidisciplinary council evaluation. The major challenge encountered during surgical planning was the inability to clearly delineate the fistulous tract using imaging modalities. Since the parenchymal damage in the right lower lobe was confined to a limited, localized area and the remaining portion of the lobe appeared intact, a parenchyma-sparing wedge resection was performed instead of lobectomy.

In conclusion, the management of bronchobiliary fistula represents a complex challenge that necessitates a tailored, multidisciplinary strategy ranging from minimally invasive interventions to major surgery. As demonstrated in this exceptionally rare case compli-

cated by intrapulmonary gallstone formation, treatment decisions must be guided by the specific anatomical pathology and the patient's overall physiological reserve. This report underscores that when endoscopic measures prove insufficient, individualized surgical planning remains the definitive solution for successful outcomes.

Declaration of conflicting interests

The authors declared no conflicts of interest with respect to the authorship and/or publication of this article.

Funding

The authors received no financial support.

Authors' contribution

MK: organized the article and wrote the paper TUK: FBE: contributed to the data collection MOK: revised the article. All authors revised the manuscript. The authors read and approved the final manuscript.

References

1. Lian BD, Zhou WY, Peng J, Zhang X, Zhao K, Chen C et al. Bronchobiliary fistula caused after percutaneous transhepatic biliary drainage treatment: A case report. Medicine (Baltimore) 2023; 102: e36363.
2. Trieu M, Weihe EK, Sunwoo BY. Bilioptysis Caused by Bronchobiliary Fistula. Am J Respir Crit Care Med 2023; 208: 896-7.
3. Uzun K, Ozbay B, Etlik O, Kotan C, Gencer M, Sakarya ME. Bronchobiliary fistula due to hydatid disease of the liver: a case report. Acta Chir Belg 2002; 102: 207-9.
4. Acquasanta M, Spadarella G, Civelli EM. Spontaneous bronchobiliary fistula: Case report. J Radiol Case Rep 2020; 14: 10-5.
5. Eryigit H, Oztas S, Urek S, Olgac G, Kurutepe M, Kutlu CA. Management of acquired bronchobiliary fistula: 3 case reports and a literature review. J Cardiothorac Surg 2007; 2: 52.
6. Edmunds C, Hollingsworth J, Kouri B, Pawa R, Pawa S. Bronchobiliary Fistulas. Am J Med Sci 2025; 370: 83-9.
7. Guruvaiah N, Ponnatapura J. Bronchobiliary fistula: a rare postoperative complication of spilled gallstones from laparoscopic cholecystectomy. BMJ Case Rep 2021; 14: e243198.
8. Joh HK, Park SY. Surgical Treatment of Bronchobiliary Fistula with Pulmonary Resection and Omentopexy. Korean J Thorac Cardiovasc Surg 2020; 53: 38-40.
9. El Ouali IIE, El Graini SSE, El Aoufir OOE, Belaabed SSB, Benkabbou AAB, Amrani LLA et al. Broncho biliary fistula, a rare complication after hepatectomy: case report of endoscopic and radiological management. J Surg Case Rep 2024; 2024: rjae657.
10. Sarraj A, Khalifa MB, Jaoued F, Ghannouchi M, El Guedr W, Boudokhane M. Broncho-biliary fistula caused by a left hydatic cyst: a case report. Int J Surg Case Rep 2025; 134: 111770.

This article is an open access article distributed under the terms and conditions of the Creative Commons Attribution (CC BY) license (http://creativecommons.org/licenses/by/4.0/

Current Thoracic Surgery

To cite this article: Nabi MS, Sarwar Z, Farooq K. Fibro-osseous lesion of the 11th rib mimicking malignancy: a rare thoracic chest wall tumor. Curr Thorac Surg 2025;10(3):175-178.

Case Report

Fibro-osseous lesion of the 11th rib mimicking malignancy: a rare thoracic chest wall tumor

Muhammad Shoaib Nabi[1], Zeeshan Sarwar[1]*, Khalid Farooq[2]

[1]Department of Thoracic Surgery, Services Institute of Medical Sciences (SIMS), Services Hospital, Lahore, Pakistan
[2]Department of Radiology, Lahore Medical and Dental College, Lahore, Pakistan

ABSTRACT

Fibro-osseous lesions of the rib are rare benign entities that frequently mimic primary or secondary chest wall malignancies. They are most commonly reported in the sixth to eighth ribs, with lower rib involvement being exceptionally uncommon. Radiological findings are often nonspecific, thus, histopathological evaluation is crucial for establishing a definitive diagnosis. We report the case of a 32-year-old female presenting with left lower chest pain and a firm, gradually expanding swelling over the left posterolateral chest wall. Imaging revealed a lytic lesion of the left 11th rib, raising suspicion of a primary bone tumor. Given the diagnostic uncertainty, resection of the affected rib segment was performed. The postoperative course was uneventful, and the patient was discharged on the fourth postoperative day. Histopathology confirmed a benign fibro-osseous lesion. Fibro-osseous lesions of the rib are rare and diagnostically challenging due to their radiological resemblance to malignant tumors. Involvement of the 11th rib is infrequent, and to our knowledge, has not been previously documented. This case showed the importance of surgical excision in achieving diagnostic certainty in the case of a fibro-osseous lesion

Keywords: fibro-osseous lesion of rib, rib tumor, benign chest wall tumor, chest wall resection, malignancy, immunohistochemistry

Corresponding Author*: Zeeshan Sarwar, MBBS, MRCS Department of Thoracic Surgery, Services Hospital, House 139, Block 4, Sector C-2, Green Town, Lahore, Punjab, Pakistan.
E-mail: zeeshan.sarwar195@gmail.com Phone: +92 3214347410
Doi: 10.26663/cts.2025.031
Received 23.09.2025 accepted 25.10.2025

Introduction

Fibro-osseous lesions of the rib are exceptionally rare, benign tumors that often resemble malignant or aggressive chest wall neoplasms on clinical and radiological evaluation. These tumors are also labelled as post-traumatic fibro-osseous lesions (PTFOL), and regarded as reactive proliferations arising after minor or unrecognized trauma, and have historically been misdiagnosed as rib metastases, osteoid osteomas, fibrous dysplasias, sclerosing xanthomatous lesion, or benign fibrous histiocytomas [1-3]. The sixth to eighth ribs are most frequently involved, with no consensus on their natural history or optimal management [4]. The clinical challenge lies in their radiological resemblance to primary or secondary chest wall malignancies. Histopathological confirmation remains the gold standard for diagnosis, as imaging alone rarely provides sufficient specificity [5].

Case Report

A 32-year-old female with a six-month history of dull left chest wall pain had a firm, non-tender swelling over the 11th rib. Computed tomography (CT) showed a well-circumscribed, expansile mass (90 × 78 × 50 mm) with arc-like calcification involving the anterior 11th rib and projecting into the abdominal cavity, without invasion or metastasis (Figure 1). A tru-cut biopsy suggested a spindle cell neoplasm.

Due to the diagnostic uncertainty and symptomatic presentation, she underwent wide local resection of the 10th and 11th ribs with 2 cm margins, followed by chest wall reconstruction using polypropylene mesh. The postoperative recovery was uneventful, and the patient was discharged on the fourth postoperative day.

Histopathological examination revealed a well-circumscribed, lobulated rib mass (7.8 × 7 × 4 cm) with a homogeneous tan-white cut surface. Microscopically, curvilinear osteoid trabeculae lined by osteoblasts were seen, with spindle cell proliferation showing minimal atypia and mild stromal fibrosis. No high-grade features, necrosis, or significant mitotic activity were observed. Immunohistochemistry: CD34, Desmin, STAT6, MUC4 negative; SATB2 positive; β-catenin cytoplasmic only. Final diagnosis was fibro-osseous lesion with clear resection margins (Figure 2). At nine months, the patient remained asymptomatic and recurrence-free. Written informed consent was obtained from the patient for publication of this case report and any accompanying images.

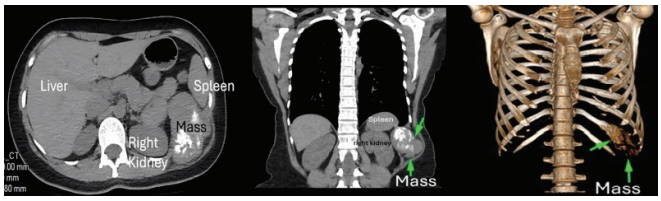

Figure 1. Thoracic computed tomography (CT) images demonstrating the relationship of the left 11th rib mass with adjacent structures, including the diaphragm, kidney, spleen, pancreatic tail, and colon. The three-dimensional (3D) reconstruction of the expansile mass is shown on the right.

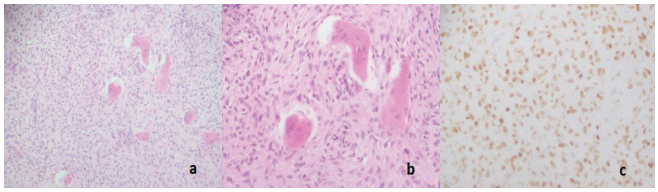

Figure 2. Histopathological evaluation of the resected specimen. Hematoxylin and eosin (H&E) staining showing the fibro-osseous lesion at ×20 magnification **(a)**, higher magnification (×40) demonstrating osteoid trabeculae lined by osteoblasts **(b)**, immunohistochemical staining revealing strong nuclear positivity for SATB2 (×40) **(c)**.

Discussion

Fibro-osseous lesions of the ribs are exceedingly rare, leading to diagnostic and therapeutic challenges. In this patient, a mass involving the left 11th rib, projecting into the abdominal cavity, initially raised strong suspicion for a primary malignant chest wall tumor. The pre-operative tru-cut biopsy further reinforced the malignant differential, necessitating surgical resection. However, final histopathology confirmed a benign fibro-osseous lesion.

The reported age range of post-traumatic fibro-osseous lesions (PTFOL) varies widely, from adolescence to late adulthood, with a mean age in the fifth decade of life [3,4]. Our patient, a 32-year-old female, represents the younger spectrum of reported cases. While a history of trauma has been suggested as a precipitating factor in the majority of PTFOL cases [3], our patient denied any prior traumatic episode. This observation supports the hypothesis that such lesions may also arise in the absence of overt trauma, potentially representing a reactive or developmental process [6].

Radiologically, fibro-osseous rib lesions typically present as well-circumscribed, expansile masses with varying internal density and occasional calcification [1,3]. In our case, CT imaging revealed a large mass with arc-like calcifications and an expansile pattern, raising

suspicion for a malignant chest wall tumor. Such radiological overlap complicates the preoperative diagnostic process. A structured diagnostic approach is therefore essential, including initial imaging (CT or MRI), core needle biopsy, and immunohistochemistry (β-catenin, SATB2) to distinguish fibro-osseous lesions from mimickers such as fibrous dysplasia or low-grade sarcomas [7,8]. Definitive histopathology following excision is crucial, particularly in large or symptomatic lesions.

Histopathological examination remains the gold standard for diagnosis. In our case, the initial biopsy yielded a spindle cell neoplasm, which was misleading, and the correct diagnosis was only possible after complete excision and thorough histological evaluation. Fibrous dysplasia and osteoid osteoma are the most common benign rib lesions and can be distinguished from fibro-osseous lesions histologically [3,4]. The absence of nuclear β-catenin staining and positivity for SATB2 further supported the fibro-osseous nature of the lesion in our patient.

Surgical management remains the mainstay for rib tumors when malignancy cannot be excluded preoperatively. A wide local resection of the involved ribs with mesh reconstruction was performed in our patient, with good functional outcome. While some small, asymptomatic fibro-osseous lesions confirmed by biopsy may be managed conservatively [1,5], surgery is warranted in cases with diagnostic uncertainty, symptomatic lesions, or large tumors threatening adjacent structures.

Importantly, long-term outcomes remain poorly defined. Recurrence has not been systematically reported due to the rarity of these lesions and limited follow-up in existing studies [2,4]. Our 9-month disease-free follow-up, although reassuring, does not allow conclusions about long-term prognosis. Extended surveillance is therefore recommended to clarify recurrence risk and natural history.

In conclusion, fibro-osseous lesions of the rib are rare entities that can closely mimic malignant chest wall tumors. This case highlights the importance of maintaining PTFOL in the differential diagnosis of rib masses, especially when imaging suggests malignancy. A structured diagnostic framework combining radiology, biopsy, and immunohistochemistry is essential, but complete surgical resection remains the definitive management strategy in cases of diagnostic uncertainty (Figure 3). Future multicenter registries could help clarify the natural history and optimal surveillance strategies for these lesions.

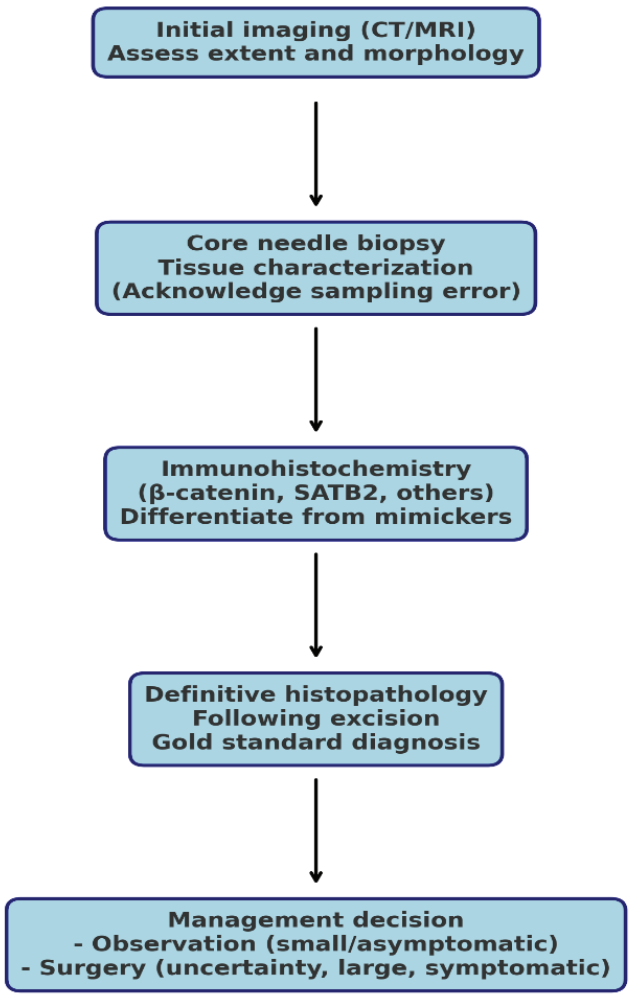

Figure 3. Diagnostic workflow for the evaluation of rib masses suspicious for fibro-osseous lesions.

Declaration of conflicting interests

The authors declared no conflicts of interest with respect to the authorship and/or publication of this article.

Funding

The authors received no financial support.

Authors' contribution

MSN: Conceptualization, Methodology, Supervision, Writing – review & editing. ZS: Writing – original draft, Visualization, Data curation. KF: Investigation, Validation (Radiology).

References

1. Nassereddine H, Larousserie F, Campagna R, Castier Y, Couvelard A, Choudat L et al. Xanthomatous posttraumatic fibro-osseous lesion of the rib: a rare and underrecognized entity. Case report and literature review. Int J Surg Pathol 2017; 25: 640-3.

2. Blanco M, Cabello-Inchausti B, Cura M, Fernandes L. Post-traumatic fibro-osseous lesion of the ribs and scapula (sclerosing xanthofibroma). Ann Diagn Pathol 2001; 5: 343-9.

3. McDermott MB, Kyriakos M, Flanagan FL. Posttraumatic fibro-osseous lesion of rib. Hum Pathol 1999; 30: 770-80.
4. Aubert S, Kerdraon O, Conti M, Buob D, Petit S, Leroy X. Post-traumatic fibro-osseous lesion of the ribs: a relatively under-recognised entity. J Clin Pathol 2006; 59: 635-8.
5. Brahem M, Jomaa O, Abdelali M, Sarraj R, Bayoudh A, Njim L et al. Post-traumatic fibro-osseous lesion of the fourth rib simulating a chest wall tumor: a case report. Korean J Fam Med 2023; 44: 295-8.
6. Patel R, Parelkar K, Puthenpurayil S, Kothiya MR. Cemento-ossifying fibroma: an extensive fibro-osseous lesion involving paranasal sinuses. Int J Otorhinolaryngol Head Neck Surg 2024; 10: 595-8.
7. Katsenos S, Archondakis S, Sakellaridis T. Osteoblastoma of the rib: A rare benign tumor with an unusual location. Int J Surg Case Rep 2013; 4: 146-8.
8. Bacha D, Ayadi-Kaddour A, Marghli A, Djilani H, Mezni FE. Post-traumatic fibro-osseous lesion of the rib: a rare entity not to be overlooked. Ann Pathol 2009; 29: 36-8.

This article is an open access article distributed under the terms and conditions of the Creative Commons Attribution (CC BY) license (http://creativecommons.org/licenses/by/4.0/).

Current Thoracic Surgery

To cite this article: Hasgül D, Okyay N, Kurak TU, Ayan E. Giant lung bulla extending to the contralateral hemithorax. Curr Thorac Surg 2025;10(3):179-183.

Case Report

Giant lung bulla extending to the contralateral hemithorax

Damla Hasgül[1]*, Nurefşan Okyay[2], Tibet Uğur Kurak[2], Erhan Ayan[2]

[1]Department of Thoracic Surgery, Faculty of Medicine, Mustafa Kemal University, Hatay, Turkey
[2]Department of Thoracic Surgery, Faculty of Medicine, Mersin University, Mersin, Turkey

ABSTRACT

Smoking constitutes one of the most significant risk factors in the etiology of giant bullous emphysematous lung disease, leading to the development of massive bullous lesions. This clinical entity is one that poses a diagnostic challenge due to confusion with spontaneous pneumothorax on imaging modalities. In this case report, we present a 52-year-old male patient with underlying Chronic Obstructive Pulmonary Disease (COPD) and a significant history of smoking. The patient presented to the emergency department with chest pain and acute dyspnea. Following the detection of a giant bulla on thoracic computed tomography (CT), the patient was referred to our clinic due to respiratory limitation and the necessity for planned preventive surgical management. This presentation is primarily designed to address the identification of large lung bullae, their integrated management in conjunction with underlying COPD, the radiological criteria for differentiating a bulla from pneumothorax, and to share our operative observations regarding the surgical intervention.

Keywords: giant bulla, pneumothorax, emphysema, bullectomy, vanishing lung syndrome

Corresponding Author*: Damla Hasgül, M.D. Mustafa Kemal University, Faculty of Medicine, Department of Thoracic Surgery, Hatay, Turkey.
E-mail: damlahsgl@gmail.com Phone: +90 5384529090
Doi: 10.26663/cts.2025.032
Received 03.07.2025 accepted 31.10.2025

Introduction

The entity of the giant bulla was first documented in the literature by Burke in 1937. These lesions are clinically defined as emphysematous structures that occupy more than 30% of a hemithorax and anatomically exhibit a predilection for localization primarily within the upper lobes. A commonly accepted synonym for this condition, reflecting the severe reduction in functional lung parenchyma seen radiologically, is Vanishing Lung Syndrome [1]. Depending on the size of the bulla, patients may be asymptomatic or may experience complaints such as chest pain and dyspnea. Especially in the presence of pneumothorax, cough and increasing shortness of breath may be observed.

In the radiological evaluation, the compression atelectasis or absence of discernible pulmonary markings within the bulla cavity on a chest radiograph creates a diagnostic dilemma that can be readily confused with spontaneous pneumothorax. High-resolution thorax computed tomography (CT) is the preferred diagnostic imaging method for detailed evaluation to differentiate between giant bulla and pneumothorax [2].

Both the patient's clinical presentation and comparative diagnostic imaging techniques are indispensable components of the diagnostic process. The invasive procedure chosen holds critical importance because performing a tube thoracostomy for a suspicion of pneumothorax—can lead to severe iatrogenic complications if a giant bulla is instead present. Such complications include the development of bronchopleural fistulas and persistent, massive air leaks, thereby necessitating accurate differentiation [3,4]. Symptomatic improvement and lung expansion cannot be achieved in these patients with incorrect interventions [5].

This presentation is primarily designed to identification of large lung bullae, their integrated management in conjunction with underlying COPD, the radiological criteria for differentiating a bulla from pneumothorax, and to share our operative observations regarding the surgical intervention.

Case Report

We present the case of a 52-year-old male with an established diagnosis of chronic obstructive pulmonary disease (COPD) and smoking history of 80 pack-years. His medical history includes intermittent emergency room visits with chest pain and shortness of breath. Initial suspicion of pneumothorax based on a chest radiograph performed at another clinic was subsequently clarified by thoracic CT, which confirmed the presence of a giant bulla. The patient was ultimately referred to our clinic for management of respiratory distress and consideration for preventive surgical management.

Physical examination revealed decreased breath sounds in the upper zone of the right lung. Laboratory examinations, including CRP and WBC values, were within normal ranges. Thoracic CT showed large air cysts in the right lung and anterior mediastinum extending towards the opposite hemithorax. The right lung was partially collapsed, and increased emphysematous ventilation was observed in both lungs (Figures 1,2). The chest radiograph taken in our clinic showed a radiolucent area in the right hemithorax compatible with a bullous lesion, with the trachea deviated towards the left side (Figure 3).

Surgical excision was planned under general anesthesia. During videothoracoscopic exploration, a giant bullous area originating from the upper lobe was detected, filling a large part of the right hemithorax. Tight adhesions in the bullous lung fields extending from the anterior mediastinal area to the opposite hemithorax were released using blunt dissection and an energy device. Following adhesiolysis, wedge resection was applied to the intact lung tissue on the lateral side of the upper lobe, forming the base of the bulla (Figure 4), thereby achieving lung expansion. A pleural tent was created for preventive purposes against the risk of postoperative air leakage. Histopathological examination was consistent with bullous and emphysematous changes.

Postoperatively, no complications developed. Chest radiographs showed the trachea in normal localization and successful parenchymal expansion (Figure 5). The chest tube was removed on the 7th postoperative day, and the patient was discharged in full recovery.

Written informed consent was obtained from the patient for publication of this case report and any accompanying images.

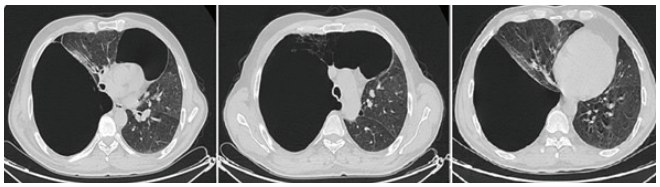

Figure 1. Axial reformatted thoracic CT images showing the giant bullous lesion originating from the right upper lobe and compressing the adjacent parenchyma.

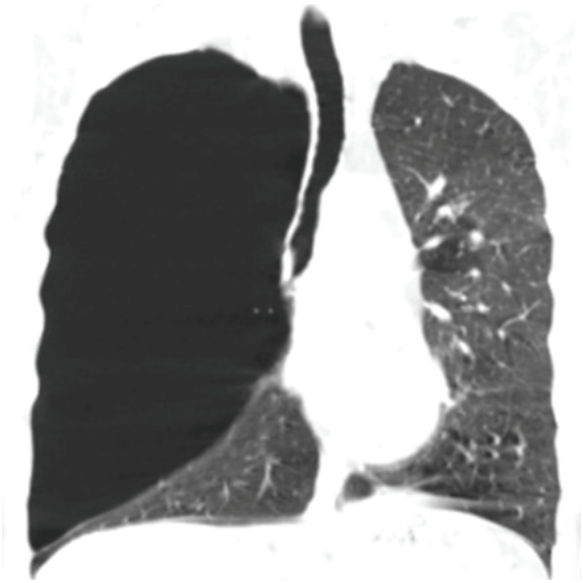

Figure 2. Coronal reformatted thoracic CT sections demonstrating the extent of the giant bulla originating from the right upper lobe and its mass effect on the parenchyma.

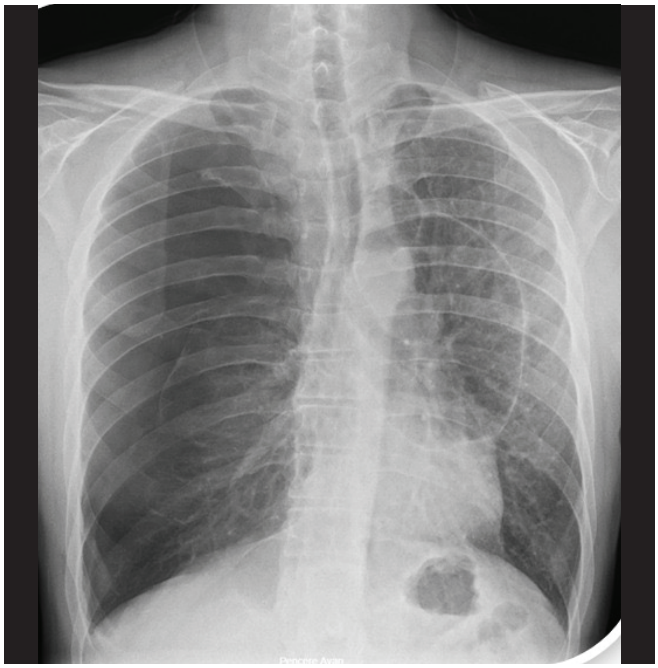

Figure 3. Preoperative posteroanterior (PA) chest radiograph. Significant deviation of the trachea to the left side is observed due to the expansile bullous lesion and increased aeration in the right hemithorax.

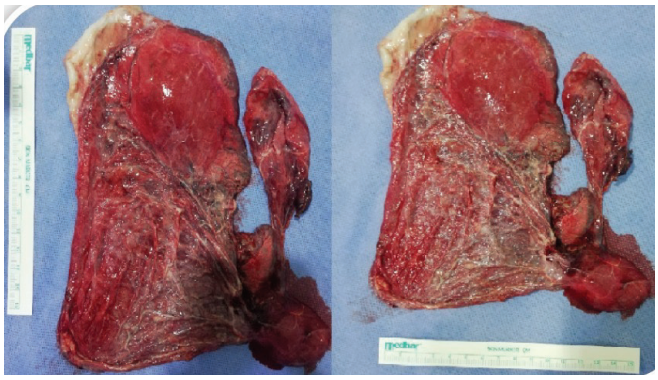

Figure 4. The resected specimen of the bullous lung tissue following wedge resection.

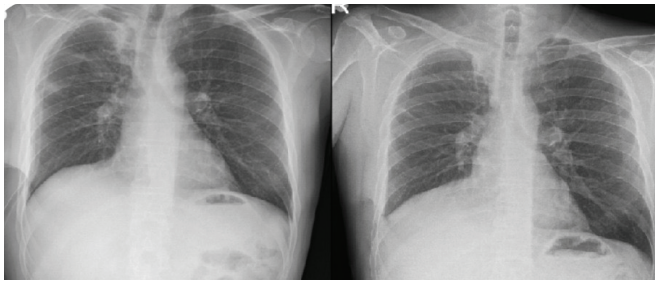

Figure 5. Postoperative PA chest radiographs (early and late periods) showing the return of the trachea to its normal midline position and successful re-expansion of the lung parenchyma.

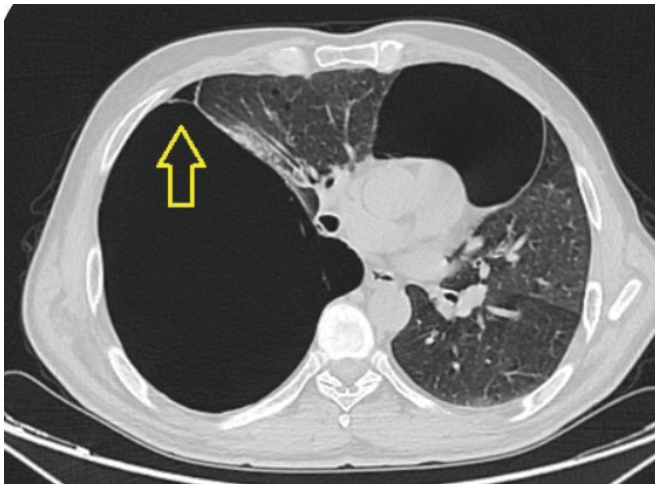

Figure 6. Thoracic CT scan demonstrating the "double wall sign" (indicated by the yellow arrow), which aids in differentiating pneumothorax from bullae.

Discussion

Bullous lung disease is a sequela of emphysema, resulting from the pathological, irreversible dilatation of the airspaces located distal to the terminal bronchiole. The lesions, known as bullae, are defined as air-filled cystic spaces within the pulmonary parenchyma that achieve a minimum diameter of 1 cm. This bullous emphysematous change is a frequent component of COPD, with

cigarette smoking recognized as the predominant etiological factor driving its development [6].

Giant pulmonary bullae are associated with several syndromic conditions, among which Vanishing Lung Syndrome (VLS) is the best characterized. VLS is defined by the presence of massive bullous destruction predominantly in the upper lobes, resulting in compression of the residual lung parenchyma [7]. The condition is frequently linked to cigarette smoking, alpha-1 antitrypsin deficiency (AATD), and connective tissue disorders. In AATD, mutations in the SERPINA1 gene cause a protease-antiprotease imbalance leading to panlobular emphysema, predominantly in the basal zones, often progressing to early indications for lung transplantation [8]. In Marfan and Ehlers–Danlos syndromes, fragility of elastic fibers predisposes to bilateral, multiple bullae and recurrent spontaneous pneumothorax; therefore, pleurodesis is recommended to reduce postoperative recurrence rates [9]. Moreover, HIV infection and inhalational cocaine abuse are associated with apical bullous changes and diffuse parenchymal injury [10,11]. Since pulmonary hypertension and right ventricular overload are common in these patients, preoperative assessment of pulmonary vascular resistance and right ventricular function is essential for optimal surgical planning and perioperative management [12].

Depending on the size of the bulla, patients may be asymptomatic or may describe complaints such as chest pain and dyspnea. More acute dyspnea and chest pain appear to occur in pneumothorax compared to giant bullae. In our patient, the main reason for admission was worsening dyspnea. Giant bullae cause mediastinal shift and parenchymal compression, leading to clinical symptoms [13,14]. Diagnosis is usually suspected by clinical history and physical examination but must be confirmed by imaging. In our patient's radiographs, the trachea and mediastinum were pushed towards the opposite side, a condition that can be confused with tension pneumothorax.

In radiological evaluation, there is an absence of pulmonary signs on the chest radiograph, a clinical condition that can be confused with spontaneous pneumothorax. In the presence of a giant bulla, there is an asymmetric radiolucent appearance that causes compression in the lung parenchyma, whereas in the presence of pneumothorax, a line belonging to the visceral pleura separated from the chest wall is often seen, and bronchovascular branches are not seen lateral to this line. In thorax CT, the "double wall sign" is used to distinguish pneumothorax from giant bullas. It occurs in the presence of air surrounding the wall of the bulla and the wall of the bulla is observed parallel to the parietal pleura. The presence of this sign supports pneumothorax and guides in determining the appropriate location when applying tube thoracostomy [15]. The double wall sign is also observed in our patient's CT findings (Figure 6).

Sometimes the line defining the border of the bulla can be confused with the visceral pleural line on localized pneumothorax. However, the line bordering the bulla is usually more horizontal. Signs used to detect pneumothorax in patients with giant bullous emphysema like our patient are compressed or consolidated lung, nonanatomical hyperlucency, and the double wall sign. The absence of this sign provides evidence against the diagnosis of pneumothorax and may prevent unnecessary chest tube placement. Additionally, if the patient has pneumothorax and a chest tube is placed, immediate symptomatic relief should be provided and there should be radiological evidence of lung re-expansion on subsequent chest radiographs.

Surgical resection (bullectomy) is indicated for bullae filling more than 30% of a hemithorax, especially if there is compression of adjacent lung parenchyma and dyspnea. Benefits of resection include alleviating dyspnea, improving ventilation/perfusion matching, reducing intrathoracic pressure, and improving hemodynamic function [16]. While Video-Assisted Thoracoscopic Surgery (VATS) reduces hospital stay and pain [17], it may be associated with higher recurrence rates compared to thoracotomy [18]. To minimize postoperative air leaks, techniques such as partial pleurectomy, apical pleural tent application, and abrasion can be applied [19]. We performed a perioperative pleural tent application, and no air leakage occurred postoperatively.

In conclusion, pneumothorax and giant bulla are distinct pathologies. Understanding their clinical and radiological differences is crucial to avoid inappropriate invasive procedures and to determine the correct surgical management.

Declaration of conflicting interests

The authors declared no conflicts of interest with respect to the authorship and/or publication of this article.

Funding

The authors received no financial support.

Authors' contribution

DH: Conceptualization, Methodology, Writing - original draft. NO: Data curation, Investigation. TUK: Validation, Visualization. EA: Supervision, Writing - review & editing.

References

1. Burke R. Vanishing lungs: A case report of bullous emphysema. Radiology 1937; 28: 367-71.
2. Yousaf MN, Chan NN, Janvier A. Vanishing lung syndrome: An idiopathic bullous emphysema mimicking pneumothorax. Cureus 2020; 12: e9596.
3. Douedi S, Upadhyaya VD, Patel I, Mazahir U, Costanzo E, Hossain MA. Cocaine-induced giant bullous emphysema. Case Rep Med 2020; 2020: 6410327.
4. Ferreira Junior EG, Costa PA, Silveira LMFG, Almeida LEM, Salvioni NCP, Loureiro BM. Giant bullous emphysema mistaken for traumatic pneumothorax. Int J Surg Case Rep 2019; 56: 50-4.
5. Waseem M, Jones J, Brutus S, Munyak J, Kapoor R, Gernsheimer J. Giant bulla mimicking pneumothorax. J Emerg Med 2005; 29: 155-8.
6. Samanta RP, Agarwal S, Sengupta S. Giant bullous emphysema mimicking spontaneous pneumothorax. Cureus 2022; 14: e31182.
7. Roberts L, Putman CE, Chen JT, Goodman LR, Ravin CE. Vanishing lung syndrome: Upper lobe bullous pneumopathy associated with paraseptal emphysema. Radiology 1987; 164: 29-34.
8. Stoller JK, Aboussouan LS. A review of α1-antitrypsin deficiency. Am J Respir Crit Care Med 2012; 185: 246-59.
9. Akira M, Sakatani M, Ueda E. Computed tomography of pulmonary complications in connective tissue diseases. Radiographics 1993; 13: 729-46.
10. Arora A, Sanyal S, Dutt N Gupta A. Pulmonary complications of cocaine abuse: Bullous emphysema revisited. J Postgrad Med 2015; 61: 113-7.
11. Ooi GC, Khong PL, Müller NL, Ho JC, Lam WK, Ooi CG et al. Pulmonary manifestations of HIV infection: Radiographic and CT findings. Radiographics 1997; 17: 1055-71.
12. Vizza CD, Lynch JP, Ochoa LL. Right and left ventricular dysfunction in severe emphysema. Am J Respir Crit Care Med 1998; 158: 626-33.
13. Erbey A, Oruç M, Şahin A, Meteroğlu F. Giant bulla mimicking tension pneumothorax. J Clin Exp Invest 2012; 3: 548-51.
14. Ascano MP, Kramer N, Le K. Differentiating giant bullous emphysema from tension pneumothorax: A case report. Cureus 2024; 16: e56789.
15. Waitches GM, Stern EJ, Dubinsky TJ. Usefulness of the double-wall sign in detecting pneumothorax in patients with giant bullous emphysema. AJR Am J Roentgenol 2000; 174: 1765-8.
16. Camp PC, Sugarbaker DJ. Surgical interventions for emphysema. Semin Thorac Cardiovasc Surg 2007; 19: 157-71.
17. Freixnet JL, Canalis E, Julia G, Rodriguez P, Santana N, De Castro FR. Axillary thoracotomy versus videothoracoscopy for the treatment of primary spontaneous pneumothorax. Ann Thorac Surg 2004; 78: 417-20.
18. Barker A, Maratos EC, Edmonds L, Lim E. Recurrence rates of video-assisted thoracoscopic versus open surgery in the prevention of recurrent pneumothoraces: A systematic review of randomised and non-randomised trials. Lancet 2007; 370: 329-35.
19. Muramatsu T, Nishii T, Takeshita S, Ishimoto S, Morooka H, Shiono M. Preventing recurrence of spontaneous pneumothorax after thoracoscopic surgery: A review of recent results. Surg Today 2010; 40: 696-9.

This article is an open access article distributed under the terms and conditions of the Creative Commons Attribution (CC BY) license (http://creativecommons.org/licenses/by/4.0/

To cite this article: Ozdemir A, Kahraman S, Bayraktar S, Demirhan R. A rare complication of hydrophilic gel filler: intrathoracic migration. Curr Thorac Surg 2025;10(3):184-186.

Case Report

A rare complication of hydrophilic gel filler: intrathoracic migration

Attila Özdemir[1]*, Selime Kahraman[2], Saliha Bayraktar[1], Recep Demirhan[1]

[1]Department of Thoracic Surgery, Kartal Dr. Lutfi Kirdar City Hospital, Istanbul, Turkey
[2]Department of Thoracic Surgery, Dr. Siyami Ersek Thoracic and Cardiovascular Surgery Training and Research Hospital, Istanbul, Turkey

ABSTRACT

Hydrophilic gel fillers are associated with late complications, including migration. We present a rare case of intrathoracic migration in a 32-year-old female, seven years after bilateral breast augmentation. Despite multiple prior extrathoracic migrations, a new right paracardiac cystic lesion was identified on computed tomography. The lesion was successfully excised via video-assisted thoracoscopic surgery, and pathology confirmed filler material. This case underscores the potential for distant migration of hydrophilic gels and the need to consider this etiology in patients with mediastinal masses and a history of augmentation.

Keywords: hydrophilic gel filler, intrathoracic migration, mediastinal mass, breast augmentation, video-assisted thoracoscopic surgery

Corresponding Author*: Attila Ozdemir, Department of Thoracic Surgery, Kartal Dr. Lutfi Kirdar City Hospital, Istanbul, Turkey.
E-mail: dr.attilaozdemir@gmail.com Phone: +90 5320575686
Doi: 10.26663/cts.2025.033
Received 14.07.2025 accepted 04.12.2025

Introduction

Hydrophilic gel filler (Aquafilling ®) is a polyacrylamide hydrogel based soft tissue filler containing 98% saline and 2% cross-linked polyamide. It was first developed for soft tissue contouring in 2005, and its use has become increasingly widespread since 2008 in applications such as breast and gluteal region augmentation [1]. However, in recent years, reports of late complications associated with hydrophilic gel fillers have been increasing. Serious adverse effects such as chronic inflammation, foreign body reaction, abscess formation, filling migration, tissue necrosis, and even sepsis have been described in the literature [2]. In this study, the case of mediastinal migration occurring 7 years after hydrophilic gel filler application is presented and discussed in comparison with the literature.

Case Report

A 32-year-old female patient who had undergone bilateral breast hydrophilic gel filler injections for aesthetic purposes seven years ago had undergone multiple (8 times) surgical interventions at various times due to hydrophilic gel filler migration to different regions, including the neck, hand, forearm, and posterior chest wall. The patient had no history of trauma or strain that would cause such frequent migration of the hydrophilic gel filler.

On follow-up, thoracic computed tomography (CT) revealed a hypodense mass lesion measuring approximately 41 × 32 mm in the right hemithorax, in the paracardiac region, and it was interpreted as a paracardiac cyst in the CT report of the lesion (Figure 1). In these migration stories, which were seen without trauma or strain in the patient, the 9th migration was to the mediastinum.

The patient, who had no known history of chronic disease, was admitted to our clinic for planned surgery. Exploration was performed via right video-assisted thoracoscopic surgery (VATS). A dense fluid was aspirated from the cystic structure observed in the mediastinal pleura, and the cystic tissue was completely cleared (Figure 2). The patient was discharged in good condition on the 2nd day without any complications. Final pathological evaluation of the surgically excised lesion reported it as granular, acellular material consistent with a foreign body.

Written informed consent was obtained from the patient and her relatives for publication of this case report and any accompanying images.

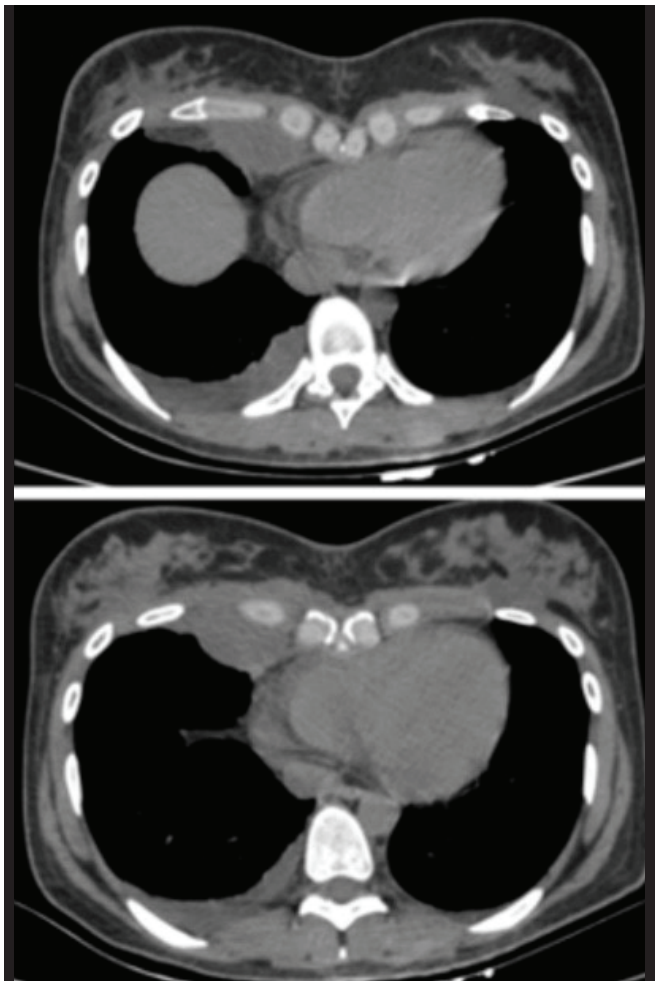

Figure 1. Thoracic CT scan showing a hypodense mass lesion in the right hemithorax, paracardiac region.

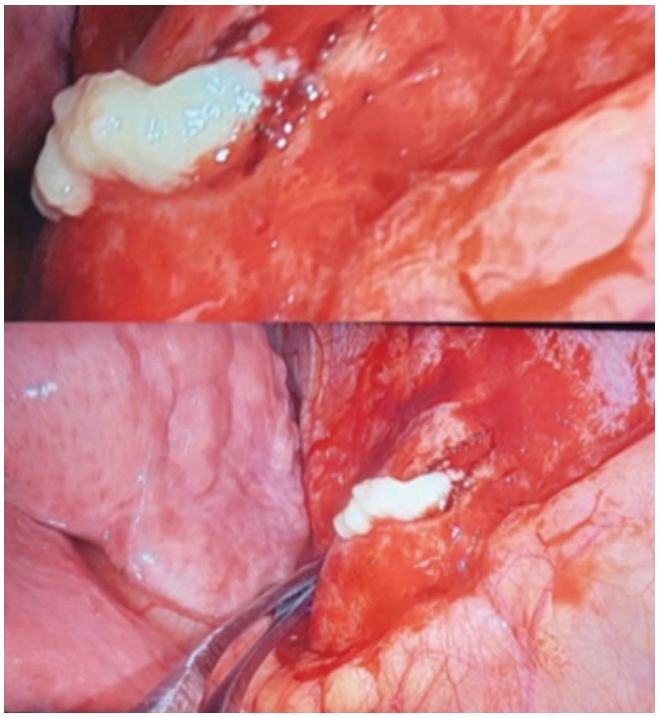

Figure 2. Intraoperative view of the white colored foreign object in the mediastinum during VATS.

Discussion

Although hydrophilic gel filler migration following filler injection has been the subject of only a limited number of case reports, the number is gradually increasing [2,3]. Migration of hydrophilic gel filler to the mediastinal region is a rare complication that has not been directly reported in the literature to date. Especially, the continuous migration of the filler material makes the phenomenon more interesting. This case demonstrates that the filling material in question can reach deep thoracic structures by overcoming anatomical barriers.

Hedström et al reported filler migration in 27 cases in a systematic review of 196 cases [3]. In the case we presented, migration was observed 8 times, and the 9th migration was to the mediastinum. In addition to local areas such as mammary gland tissue, subcutaneous adipose tissue, and pectoralis muscle, hydrophilic gel filler filling migration has been reported to occur in the inguinal area, abdominal wall, thoracic wall, back, upper extremity, and distant areas, including the hand. Similarly, in another case reported by Seyednejad et al, the filler was shown to spread from the chest wall to the retroperitoneal area and vulva, leading to an inflammatory response and tissue degradation secondary to this migration [4].

These cases indicate that hydrophilic gel filler can be transported from the injection site to distant regions through gravity, pressure gradients, weakened tissue planes, and inflammatory processes [5].

In the presented case, the migration of hydrophilic gel filler into the mediastinum can be explained by the interaction of multiple factors such as the anatomical plane of the injection, the volume administered, muscle activity in the region, and potential inflammatory processes. Additionally, differences in the application technique of the hydrophilic gel material can also cause migration, such as injecting into an inappropriate fascial plane or improperly adjusting the amount of gel material.

Migration into the mediastinum may present clinically with a variety of findings, including respiratory symptoms, dysphagia, or the presence of a mediastinal mass, and diagnosis is most often made by radiological methods. In our case, thoracic CT revealed a lesion in the anterior mediastinum; however, due to the patient's history of hydrophilic gel filler injection and previous filler migration, migration was considered the most likely diagnosis.

This case once again highlights the need to consider not only local but also systemic complications that may arise from hydrophilic gel filler applications.

In conclusion, mediastinal migration following hydrophilic gel filler injection is a rarely reported complication in the literature. In cases of newly detected mediastinal lesions, particularly in patients with a history of filler application, filler migration should be considered as a differential diagnosis.

Declaration of conflicting interests

The authors declared no conflicts of interest with respect to the authorship and/or publication of this article.

Funding

The authors received no financial support.

Authors' contribution

Concept and Design: AÖ, SK; Data Collection: SB, RD; Analysis and Interpretation: AÖ; Drafting the Manuscript: AÖ, SK; Critical Revision: RD.

References

1. Kayadibi Y, Karagoz SH, Kargin OA, Kurt SA, Kocer N. A rare cause of breast swelling in lactating women: Aquafilling® gel injection. Sisli Etfal Hastan Tip Bul 2023; 57: 552-6.
2. Toyama S, Akiyama G, Ono S, Nukaga S, Yokobori S, Ogawa R. Sepsis 6 years after breast augmentation with aquafilling: a case report and literature review. Plast Reconstr Surg Glob Open 2025; 13: e6798.
3. Hedström K, Falk-Delgado A, Sackey H. Complications after breast augmentation with dermal fillers containing copolyamide: a systematic review. JPRAS Open 2024; 40: 19-31.
4. Seyednejad H, Asilian A, Dehghani Z. Vulvar migration of aquafilling gel after breast injection: a case report. Iran J Radiol 2021; 18: e63468.
5. Gierej P, Radziszewski M, Miłoński P, Noszczyk B. Distal hand migration of polyacrylamide gel after breast augmentation: a case report and review of the literature. Indian J Plast Surg 2022; 56: 178-81.

This article is an open access article distributed under the terms and conditions of the Creative Commons Attribution (CC BY) license (http://creativecommons.org/licenses/by/4.0/).

To cite this article: Yazkan R. Can the thoracic surgery internship and the right learning outcome be a solution to the recognition and problems of thoracic surgery? Curr Thorac Surg 2025;10(3): 187-190.

Letter to the Editor

Can the thoracic surgery internship and the right learning outcome be a solution to the recognition and problems of thoracic surgery?

Rasih Yazkan*

Department of Thoracic Surgery, Süleyman Demirel University, Faculty of Medicine, Isparta, Turkey

Dear Editor,

This letter deals with only one of the many issues that can be discussed for the recognition of thoracic surgery and the solution of its problems. The issue examined includes internship training programs, which is one of the educational items for the solution. The purpose of this letter is to underscore the significance of the thoracic surgery internship, and to enhance awareness regarding its essential role in medical education and professional development.

The lack of recognition of thoracic surgery by physicians and allied health personnel and the publication of research articles on this subject, is an important problem. This problem suggests that another solution should be found for the recognition of thoracic surgery. Insufficient recognition of a branch means that the practitioners of that branch struggle with problems throughout their professional lives. These problems cause thoracic surgeons to be unable to practice their profession happily, to provide safe and accurate healthcare services, and to be misunderstood by hospital administrators.

In Türkiye, the fields of thoracic surgery and cardiovascular surgery have walked together for a long time, but they were separated as a result of the increase in knowledge, experience and the tendency towards specialization in the historical process [1]. In a session in which the development and history of thoracic and cardiovascular surgery were explained by Urak, a very important obstacle encountered in thoracic surgery that needs to be eliminated was mentioned, and it was stated that this obstacle was that "both doctors and auxiliary health personnel have no knowledge and training about thoracic surgery" [2]. In our recent past, factors affecting thoracic surgery awareness and specialty preferences among medical students [3], a survey on the interests of thoracic surgery [4], do we know thoracic surgery [5], and an interview with specialist physicians on what thoracic surgery deals with [6], unfortunately, shows us that thoracic surgery is not yet fully recognized.

In a study by Aktin et al, it was revealed that there is incomplete and incorrect information about thoracic surgery even among specialist physicians. Considering that patients coming to the thoracic surgery outpatient

Corresponding Author*: Rasih Yazkan, MD. Süleyman Demirel University, Faculty of Medicine, Department of Thoracic Surgery, 32260, Çünür, Isparta, Turkey.
E-mail: drrasihyazkan@yahoo.com Phone: +90 5054835961
Doi: 10.26663/cts.2025.034
Received 23.07.2025 accepted 23.09.2025

clinic are referred from various branches, it has been said that informing the physicians by the thoracic surgeons of the relevant hospitals can provide a more effective working environment [6].0 Again, in Akçay's study, it was concluded that thoracic surgery, which is a specific and multidisciplinary branch, should be promoted more by hospital administrations and professional organizations [5].0 Yıldırım et al found that the level of knowledge and awareness about thoracic surgery among non-physician healthcare professionals was not sufficient, and that especially the secretaries in charge of patient referral needed training on this subject [4].

Multidisciplinary hospital environments are centers where different branches provide health services in proper communication with each other, and where up-to-date health services are provided with the supply of up-to-date technological equipment by staying in contact with hospital administrations. Different branches need to know each other's dynamics and hospital administrations need to know the dynamics of each branch in order to provide accurate and quality healthcare services. The fact that a general practitioner working in the emergency department after graduation has not received adequate training in thoracic surgery and does not know the dynamics of thoracic surgery leads to significant problems in emergency health service delivery. Inadequate training in thoracic surgery is a major barrier to the recognition, appropriate management and referral to a thoracic surgeon of high mortality traumas such as thoracic trauma and life-threatening clinical conditions such as pneumothorax. Inadequate training in thoracic surgery leads to inadequate and inaccurate evaluation of chest radiographs of patients admitted to the emergency department, and densities such as scapula, costae and linear atelectasis are evaluated as pneumothorax, which leads to deterioration in the work motivation of thoracic surgeons and unnecessary energy losses. At the same time, the fact that hospital administrations do not know the dynamics of thoracic surgery leads to significant problems in the professional practice of thoracic surgery, deficiencies in the technological equipment of the clinics and inability to apply current treatment methods.

Considering that both other branch physicians and hospital administrations are physicians, it is possible that the solution to these problems may be in thoracic surgery internship. At this stage, we observe that thoracic surgery internships vary in education programs; in some programs, thoracic surgery internship is compulsory and implemented as a separate internship program, in some programs it is compulsory but integrated into other branches, and in some programs it is included as an elective internship. These different practices show that not all graduates have the same level of training in thoracic surgery.

It is very clear that the time period in which both physicians, administrative and auxiliary health personnel will recognize and learn medical departments and the time period in which what they have learned in that period will not be forgotten is the internship periods and practices during their student years. Internship periods can cause departments to be either correctly recognized, incorrectly recognized, insufficiently recognized or not recognized at all. Internship programs that end in different ways should be taken into account by program preparers and implementers and updated to meet educational standards. It is very important to determine the learning outcomes in the pre-graduate medical education program. At this stage, a new definition of “learning outcomes” comes to the fore and internship programs should be designed around this concept. In the structuring of medical education, learning outcomes are one of the main components that determine the philosophy and direction of the program. Learning outcomes clearly define the knowledge, skills and attitudes that students are expected to acquire at the end of a course or program. In this direction, achievements make it possible to plan both teaching processes and assessment and evaluation approaches in line with the objectives. An internship program designed on learning outcomes will be more engaging, fluid and memorable.

Pre-graduate medical education programs in Türkiye are carried out within the framework of learning outcomes determined by the National Core Education Program of the Council of Higher Education. The National Core Education Program provides coordination in education among medical faculties and contributes to the standardization of program outcomes by defining the basic competencies that graduates should have on a common ground [7].

Learning outcomes directly influence not only the content framework of the curriculum but also quality assurance processes. The Association for the Evalua-

tion and Accreditation of Medical Education Programs, which carries out accreditation activities for medical faculties in Türkiye, positions the clear definition of learning outcomes and the consistency of these outcomes with the education program among the basic evaluation criteria. The National Accreditation Standards for Medical Education developed by the Association for the Evaluation and Accreditation of Medical Education Programs, require that program outcomes be associated with pre-graduation competencies [8].

At the international level, in the Basic Medical Education: World Federation for Medical Education Global Standards for Quality Improvement document published by the World Federation for Medical Education, learning outcomes are among the quality indicators that play a key role in achieving the objectives of the program. The accreditation processes carried out in Türkiye are also structured in accordance with the World Federation for Medical Education standards [9].

The aims, objectives and learning outcomes of the thoracic surgery internship should be carefully prepared in such a way that the student's knowledge, skills and attitudes improve. Learning outcomes allow medical education to be planned in a holistic manner in terms of purpose, scope and outcomes, and enable the development of educational programs that are compatible with both national and international quality standards. In this context, the systematic definition of learning outcomes is considered as a strategic element for medical faculties to fulfil their mission of training physicians based on competence after graduation.

Thoracic surgery internship should enable medical students to learn the dynamics of the thoracic surgery branch, to master the clinical situations related to thoracic surgery in the emergency department and other areas, to recognize thoracic surgical diseases, to comprehend basic surgical approaches, to gain the competencies to approach these diseases from a multidisciplinary perspective, to recognize the thoracic surgeon and thoracic surgery. Students should acquire basic knowledge, skills and attitudes related to thoracic region diseases and take part in clinical decision making and team-based patient management.

In conclusion, I think many more issues can be addressed to solve the problems of thoracic surgery. I want to emphasize that thoracic surgeons have the duty to introduce thoracic surgery to other physicians and allied health personnel in the hospital where they work. This article addresses the importance of the thoracic surgery internship period as a solution and is intended to draw attention to this issue. I suggest that thoracic surgery internship programs are the first encounter with thoracic surgery in the pre-graduation period, the first encounter should be a very important opportunity and unforgettable, the internship process should be evaluated and carried out very seriously and carefully planned, the internship program should be compulsory and compatible with the learning goal, and the priority issues related to thoracic surgery in health service delivery should definitely be included in the program. I suggest that the awareness of thoracic surgery that will be permanent in this period will contribute to the recognition of thoracic surgery, to the provision of safe and quality health care, to the happier performance of the profession by thoracic surgeons, and to the development of thoracic surgery and the solution of its problems.

Keywords: thoracic surgery, internship, learning, outcome

Declaration of conflicting interests

The author declared no conflicts of interest with respect to the authorship and/or publication of this article.

Funding

The author received no financial support for the research and/or authorship of this article.

References

1. Acıduman A, Arda B. Tıp Tarihimizden "Cerrahnameler" Işığında Ülkemizde Göğüs Cerrahisi. In: Ökten İ, Kavukçu HŞ, editors. Göğüs Cerrahisi. 2nd ed. İstanbul Medikal Sağlık ve Yayıncılık Hiz. Tic. Ltd. Şti; 2013. p.9-30.
2. Kaya ŞÖ. Türkiye'de Göğüs Cerrahisi'nin Yakınçağ Tarihçesi. In: Ökten İ, Kavukçu HŞ, editors. Göğüs Cerrahisi. 2nd ed. İstanbul Medikal Sağlık ve Yayıncılık Hiz. Tic. Ltd. Şti; 2013. p.31-9.
3. Aydın S. Awareness of thoracic surgery and factors affecting specialty preferences among medical faculty students. Sağ Aka Derg 2021; 8: 113-6.
4. Yıldırım Ş, Metin B, Yıldırım E. Interests of Thoracic Surgery: A Questionnaire Study. Bozok Tıp Derg 2015; 5: 19-23.

5. Akçay O. Do We Know Thoracic Surgery? Klinik Tıp Bilimleri Dergisi 2018; 6: 1-4.

6. Aktin B, Apilioğulları B, Esme H, Yoldaş T. An interview with specialist physicians: what are the interests of thoracic surgery? Türk Göğüs Kalp Damar Cerrahisi Dergisi 2012; 20: 840-2.

7. National Core Education Program. Available at: https://www.yok.gov.tr/ Documents/Kurumsal/ egitim_ogretim_dairesi/ Ulusal-cekirdek-egitimi-programlari/mezuniyet-oncesi-tip-egitimi-cekirdek-egitimi-programi.pdf, 2020.

8. National Medical Education Accreditation Standards. Available at: https://tepdad.org.tr

9. World Federation for Medical Education Global Standards for Quality Improvement: Basic Medical Education. Available at:https://wfme.org/standards/bme/, 2020.

This article is an open access article distributed under the terms and conditions of the Creative Commons Attribution (CC BY) license (http://creativecommons.org/licenses/by/4.0/).

Editor's Comment

The pivotal role of standardized internship in the future of thoracic surgery

Berkant Özpolat, Editor-in-Chief, Current Thoracic Surgery

Clinics of Thoracic Surgery, Guven Hospital, Ankara, Turkey

Dear Author and Readers,

I read with great interest the letter regarding the recognition of thoracic surgery and the crucial role of internship training programs in solving the challenges faced by our specialty. Yazkan, in his letter [1], touches upon a fundamental issue that extends beyond the operating room and reaches the core of medical education, the visibility and understanding of thoracic surgery within the general medical community.

As highlighted in the letter, the separation of thoracic surgery from cardiovascular surgery in Türkiye was a necessary step for specialization and the advancement of scientific knowledge [1]. However, as the author rightfully points out, this specialization should not lead to isolation. The fact that emergency practitioners or allied health personnel may struggle to interpret chest radiographs accurately or manage life-threatening conditions like pneumothorax is not merely a professional inconvenience for thoracic surgeons; it is a matter of patient safety.

The disparity in internship programs, ranging from compulsory to elective or integrated models, creates a heterogeneous landscape of competency among medical graduates. This inconsistency directly correlates with the "recognition problem" mentioned. If a physician does not encounter the dynamics of our field during their formative years, they cannot be expected to advocate for it, refer appropriately, or manage thoracic emergencies competently in their future practice [2].

Therefore, the author's emphasis on "learning outcomes" aligned with the National Core Education Program is particularly pertinent. Thoracic surgery must not be viewed merely as a niche surgical subspecialty but as a provider of essential skills that every graduating physician must possess. A standardized, outcome-based, and compulsory internship program is indeed the most effective tool to ensure that the "ABCs" of thoracic trauma and pathology are ingrained in the medical community [3].

I commend the author for shifting the focus from clinical techniques to the educational foundations of our profession. Enhancing the quality and standardization of undergraduate education is the most sustainable investment for the recognition of our branch

Keywords: medical education, internship, curriculum, professional recognition, thoracic surgery

Declaration of conflicting interests

The author declared no conflicts of interest with respect to the authorship and/or publication of this article.

Funding

The author received no financial support for the research and/or authorship of this article.

References

1. Yazkan R. Can the thoracic surgery internship and the right learning outcome be a solution to the recognition and problems of thoracic surgery? Curr Thorac Surg 2025; 10: 187-90.
2. Parsons BA, Blencowe NS, Hollowood AD, Grant JR. Surgical training: the impact of changes in curriculum and experience. J Surg Educ 2011; 68: 44-51.
3. Frank JR, Snell LS, Cate OT, Holmboe ES, Carraccio C, Swing SR et al. Competency-based medical education: theory to practice. Med Teach 2010; 32: 638-45.

Doi: 10.26663/cts.2025.035

This article is an open access article distributed under the terms and conditions of the Creative Commons Attribution (CC BY) license (http://creativecommons.org/licenses/by/4.0/).