

To cite this article İncekara F, Türk İ, Demirağ F, Demiröz ŞM, Fındık G. Six different types of primary tumors in a lady: multiple primary tumors. Curr Thorac Surg 2023; 8(2): 109-112.

## Case Report

# Six different types of primary tumors in a lady: multiple primary tumors

 Funda İncekara<sup>1\*</sup>,  İlteriş Türk<sup>1</sup>,  Funda Demirağ<sup>2</sup>,  Şevki Mustafa Demiröz<sup>3</sup>,  Göktürk Fındık<sup>1</sup>

<sup>1</sup>Department of Thoracic Surgery, University of Health Sciences, Ankara Atatürk Sanatoryum Training and Research Hospital, Ankara, Turkey

<sup>2</sup>Department of Pathology, University of Health Sciences, Ankara Atatürk Sanatoryum Training and Research Hospital, Ankara, Turkey

<sup>3</sup>Department of Thoracic Surgery, Gazi University Faculty of Medicine, Ankara, Turkey.

### ABSTRACT

Multiple primary tumors are the ones that develop in the same patient at the same or different times. Each separate tumor should be proved to be malignant by histologic examination to rule out metastatic disease. A 59 year-old female patient was referred to our clinic for a newly diagnosed solitary pulmonary nodule. She is an uncommon case who has six primary tumors; a Kaposi's sarcoma of extremity, an infiltrative ductal carcinoma of breast and four different types of lung neoplasms.

**Keywords:** adenocarcinoma in-situ, carcinoid tumor, infiltrative ductal carcinoma, Kaposi's sarcoma

---

Corresponding Author\*: Funda İncekara, MD. Ankara Atatürk Sanatoryum Training and Research Hospital, Department of Thoracic Surgery. Pınarbaşı Mah. Sanatoryum Cad. 06280, Keçiören, Ankara, Turkey.

E-mail: drfundaincekara@gmail.com Phone: +90 505 768 2387

Doi: 10.26663/cts.2023.0019

Received 06.12.2022 accepted 28.12.2022

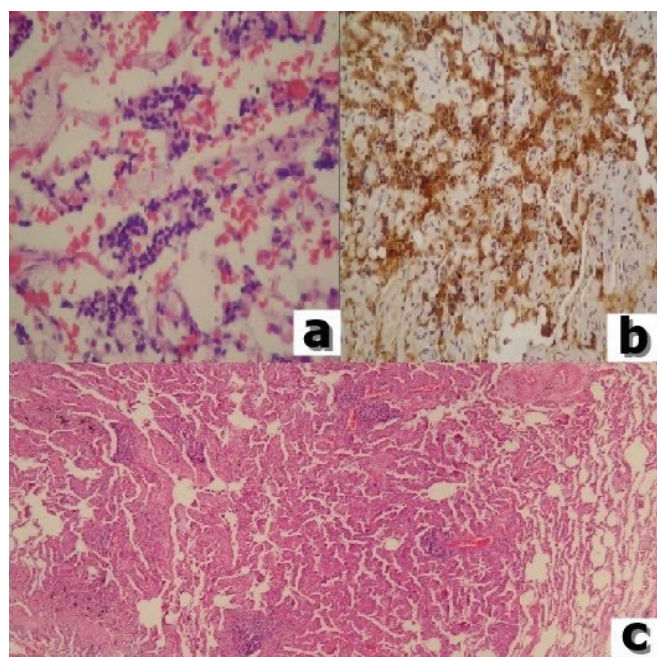
## Introduction

The term, multiple primary tumors (MPT) is used for the tumors which occur in a patient simultaneously or in different time periods. They account 0.7%–11% of all carcinomas. Four or more neoplasm occur in <0.1% of MPT cases [1,2]. It is known that the subsequent tumor develops as a result of many different interactions and also presence of a tumor increases the risk of developing another one [1,3]. In this report we present a 59 years-old lady with an uncommon case who has six primary tumors.

## Case Report

A 59 years-old nonsmoker lady followed by an oncologist for a breast cancer history and was referred to our clinic for a newly diagnosed solitary pulmonary nodule. Her detailed medical history revealed a Kaposi's sarcoma of 1cm that was raised on the second finger of the right foot and was treated with radiation therapy 34 years ago when she was 25 years old. In 2014, a mass had arisen in her left breast, a tru-cut biopsy was performed and diagnosed as infiltrative ductal carcinoma. She had underwent left lumpectomy and axillary lymph node dissection. The final pathologic evaluation revealed a stage 2B tumor (T2N1M0) and combined six cycles of adjuvant chemotherapy and radiation therapy was performed. There were no signs of BRCA-1 and BRCA-2 mutations in blood test. Just after, hormone therapy was decided to be used for five years. But in the third year of her routine follow up, a pulmonary nodule was detected on chest x-ray, and thorax computed tomography revealed a 1 cm sized solitary pulmonary nodule on left upper zone. A PET-CT scan was performed and a ground glass opacity which was 11mm on left apicoposterior segment with a SUVmax value of 4.2 was detected. For preoperative evaluation a flexible bronchoscopy was made and the left bronchial tree was observed to be normal while surprisingly the right middle lobe medial segment bronchus was found to be fully obliterated with an endobronchial lesion. Multiple biopsies were made from the lesion and the pathologic evaluation revealed a carcinoid tumor. Videothoroscopic wedge resection of the left apical lesion was performed. However, the frozen section was not able to differentiate a metastatic or primary lesion so the operation was terminated and final pathology revealed

a primary lung adenocarcinoma in situ. In another session a right sided videothoroscopic middle lobectomy was performed for the carcinoid tumor and the final pathology revealed a 7mm in-size typical carcinoid tumor with reactive 8,9,10 and 11th station mediastinal lymph nodes. And finally a third operation, a left posterolateral thoracotomy was performed to complete the left upper lobectomy, Pathologic examination revealed another focus 11mm in size in the remaining upper lobe which was diagnosed as nonmucinous adenocarcinoma in situ. Also another palpable 6 mm in-size lesion was found in the left lower lobe and it was also resected, unfortunately the latter lesion was also diagnosed an adenocarcinoma in-situ. So the final pathologic diagnosis for all the four lung tumors respectively were a stage 1A typical carcinoid tumor, adenocarcinoma in-situ, nonmucinous adenocarcinoma in-situ, acinar predominant type adenocarcinoma. Immunohistochemistry confirmed the diagnosis primary pulmonary carcinoid tumor, tumor cells were positive (+) for synaptophysin and chromogranin. Presence of the three different types of lung adenocarcinoma was decided by comparative histopathologic examination. Immunohistochemistry confirmed the diagnosis primary pulmonary acinar predominant type adenocarcinoma; tumor cells were positive (+) for Napsin A and thyroid transcription factor-1 (TTF1) while negative (–) for GCDFP15, mammoglobin. The other focus diagnosed as primary pulmonary nonmucinous adenocarcinoma in-situ was also confirmed by immunohistochemistry; tumor cells were positive (+) for napsin A, TTF1 and surfactant A while negative (–) for mucin For the third focus diagnosed as primary pulmonary adenocarcinoma in-situ, immunohistochemistry revealed the tumor cells were positive (+) for napsin A and cytokeratin (CK) 7 (Figures 1a-c). (Table 1). DNA isolated from the paraffin blocks obtained from the left upper lobectomy specimen revealed a p.L858R (C.2573T>G) point mutation located on exon number 21 and codon number 858 of the EGFR gene. There was no mutation on ALK and ROS1 gene. With the decision of a multidisciplinary council adjuvant targeted chemotherapy was planned, the patient was discharged uneventfully and there is no signs of a disease in the 9th months of the follow-up. Written informed consent was obtained from the patient for the publication of her data.



**Figure 1.** Presence of the three different types of lung adenocarcinoma was decided by comparative histopathologic examination. acinar predominant type (a), nonmucinous adenocarcinoma in-situ (b), adenocarcinoma in-situ (c).

**Table 1.** Clinico-pathologic characteristics of the patient.

Age	Organ	Treatment	Histology / TNM stage
25	Right foot 2nd finger	RT	Kaposi's sarcoma (T1N0M0) stage 1A
55	Left breast	Surgery- adjuvant chemotherapy, RT, hormonotherapy	Invasive ductal carcinoma (T2N1M0) stage 2B
59	Right lung middle lobe	Surgery	Typical carcinoid tumor (T1N0M0) stage 1A
59	Left lung lower lobe	Surgery- adjuvant targeted chemotherapy	Acinar predominant type adenocarcinoma (T1N0M0) stage 1A
59	Left lung lower lobe	Surgery	Nonmucinous adenocarcinoma in situ (T1N0M0) stage 1A
59	Left lung lower lobe	Surgery	Adenocarcinoma in situ (T1N0M0) stage 1A

## Discussion

Some factors like new treatment options, increasing use of cytotoxic agents and ionized radiation have lead an increase in MPT prevalence [1,3-6].

The incidence of secondary tumors may also rise with the increase in the number of cancer patients in the following years. Therefore, extreme caution is required regarding the development of secondary tumors in the patients who are followed up and treated for primary tumors. Our case also has the history of a local radiation therapy for the Kaposi's sarcoma and chemotherapy combined with radiation and hormone therapy for an invasive ductal carcinoma of breast. These risk factors also must be considered in the developing of new primary tumors. On the other hand genetic predisposition is blamed in etiology. The patient reported here had no family members with breast cancer and the patient herself had multiple cases of breast and lung cancer (a typical carcinoid tumor, synchronous lung adenocarcinoma, and an infiltrative ductal carcinoma), no mutations in the BRCA1 or BRCA2 genes were found in her blood sample. DNA isolated from the paraffin blocks obtained from the left upper lobectomy specimen revealed a point mutation on EGRFR gene, while there was no mutation on both ALK and ROS1 genes. These results guided treatment of the patient.

Considering the aforementioned criteria, we can say that our case has six MPTs which are a Kaposi sarcoma of skin, an invasive ductal carcinoma of breast, a typical carcinoid tumor and the last three different types of lung adenocarcinoma.

In clinic approach, when two different types of histology are diagnosed in synchronous lung tumors, the term “multiple primary lung carcinoma (MPLC)” is used. Practically, to say that it is a multiple primary lung carcinoma, mediastinal lymph nodes must be free of disease and there must be no distant metastasis. The left upper zone tumors and the lower lobe tumor were each had pathology of different types. In our case, four lung lesions with two different histopathologic types made the MPLC diagnosis a challenging one.

When a MPLC is diagnosed, if respiratory functions and technical aspects allow multiple lung resections, surgical treatment is advised without any waste of time. After a current diagnose is achieved each lesion is staged separately. If one of them is exceeded stage 2 disease, surgery is not recommended. For bilateral disease, generally wedge resection and segmentectomy

is the choice while surgical resections including even pneumonectomy are the choice for unilateral disease [7]. In our case, a video-assisted right middle lobectomy for the typical carcinoid and an open left upper lobectomy and lower lobe wedge resection for the (6 mm) millimetric lesion were performed in two separate sessions. Systematic mediastinal lymph node dissection was also performed in both operations.

The five-year survival of patients with synchronous tumors is lower than the ones with metachronous tumors. An article by Markel et al comparing surgically resected synchronous lung cancers with single lung cancers has reported that nearly half of the (51%) synchronous tumors are bilateral and five-year survival is 23% for early stages [8]. In another report questioning the location of the tumor for being in the same or different lobe and also studying the histopathologic type, for surgically resected synchronous tumors, best five year survival is 33% for the ones in the same lobe with the same histopathology while the worst survival is 18% for the tumors in different lobe with different histopathology [9]. So the differentiation of synchronous MPLC and the metastatic disease is important. It has proven that long-term survival of surgically resected MPLC is better than Stage 3B and stage 4 diseases. Thus it is thought that surgical resection; especially an aggressive surgical approach is an important choice of treatment to achieve long-term survival for these patients [10,11].

In conclusion, patients with MPTs are always under risk of new primary tumors. In the presence of multiple tumors in bilateral lung always synchronous MPLC must be considered and biopsy should be performed for each of the lesions. Although survival of these patients is poor than the patients with similar stage primer lung carcinoma, aggressive surgical treatment should be a choice in selected patients.

### Declaration of conflicting interests

The authors declared no conflicts of interest with respect to the authorship and/or publication of this article.

### Funding

The authors received no financial support.

### Authors' contributions

Fİ,İT,FD,ŞMD,GF: conceived and designed the current case report, co-wrote the paper, collected the clinical data. The authors discussed the case under the literature data together and constituted the final manuscript.

### References

1. Gokyer A, Kostek O, Hacıoglu MB, Erdogan B, Kodaz H, Tutkmen E. Clinical features of the patient with multiple primary tumors: Single center experience. *North Clin İstanb* 2017; 10: 43-51.
2. Arakawa K, Hata K, Yamamoto Y, Nishikawa T, Tanaka T, Kiyomatsu T, Kawai K et al. Nine primary malignant neoplasms-involving the esophagus, stomach, colon, rectum, prostate, and external ear canal-without microsatellite instability: a case report. *BMC cancer* 2018; 18: 24.
3. Ng AK, Kenney LB, Gilbert ES, Travis LB. Secondary malignancies across the age spectrum. *Semin Radiat Oncol* 2010; 20: 67-78.
4. Hemminki K, Boffetta P. Multiple primary cancers as clues to environmental and heritable causes of cancer and mechanisms of carcinogenesis. *IARC Sci Publ* 2004; 157: 289-97.
5. Zhao J, Tan Y, Wu Y, Zhao W, Wu J, Ji M, Shi L et al. A rare case of eight multiple primary malignant neoplasms in a female patient: a case report and review of the literature. *Oncology letters* 2015; 9: 587-590.
6. Wynder EL, Mushinski MH, Spivak JC. Tobacco and alcohol consumption in relation to the development of multiple primary cancers. *Cancer* 1977; 40:1872-8.
7. Detterbeck FC, Jones DR, Kernstine KH, Naunheim KS; American College of Physicians. Lung cancer. Special treatment issues. *Chest* 2003; 123: 244- 58.
8. van Rens MT, Zanen P, Brutel de La Riviere A, Elbers HR, van Swieten HA, van Den Bosch JM. Survival in synchronous vs. single lung cancer: upstaging better reflects prognosis. *Chest* 2000; 118: 952-8
9. Riquet M, Cazes A, Pfeuty K, Ngabou UD, Foucault C, Dujon A, Banu E. Multiple lung cancers prognosis: what about histology? *Ann Thorac Surg* 2008; 86: 921-6.
10. Jung EJ, Lee JH, Jeon K, Koh WJ, Suh GY, Chung MP, Kim H et al. Treatment outcomes for patients with synchronous multiple primary non-small cell lung cancer. *Lung Cancer* 2011; 73: 237-42.
11. Akçam İlker T, Çağırıcı U, Çakan A, Ergönül Gül A, Veral A. Multiple primary malignancies. *Turk Gogus Kalp Dama* 2014; 22: 873-5.

This article is an open access article distributed under the terms and conditions of the Creative Commons Attribution (CC BY) license (<http://creativecommons.org/licenses/by/4.0/>).