

Images in Thoracic Surgery

Calcified fibrothorax as a sequela of long-standing untreated empyema

 Zeeshan Sarwar*,  Muhammad Shoaib Nabi

Department of Thoracic Surgery, Services Institute of Medical Sciences (SIMS), Services Hospital, Lahore, Punjab, Pakistan

Chronic empyema thoracis represents the end stage of pleural infection when early drainage and antimicrobial therapy are inadequate or absent. Progression of untreated empyema resulted in lung entrapment and fibrothorax. In rare, long-standing untreated cases, this pleural peel may undergo extensive dystrophic calcification, forming a rigid shell around the lung and causing severe restriction, chronic chest pain, and functional disability [1,2]. Computed tomography is the imaging modality of choice for chronic empyema and fibrothorax. Typical findings include circumferential pleural thickening, dense pleural calcification, reduction in hemithoracic volume, and compression of the underlying lung [3]. Clinically, patients develop restrictive ventilatory impairment, dyspnea, and reduced quality of life due to mechanical limitation of lung expansion. Chronic chest pain further contributes to morbidity.

Once calcified fibrothorax is established, surgery becomes the definitive treatment. Open thoracotomy with pleural decortication remains the standard approach in heavily calcified disease, allowing complete removal of the fibrous rind and restoration of lung expansion [4,5]. This case highlights the natural history and classic imaging appearance of chronic calcified empyema with

fibrothorax. It emphasizes the critical importance of early diagnosis and timely management of pleural infections to prevent progression to this rare but disabling late sequela. Informed written consent has been taken from the participant before enrollment. Anonymizing data maintained patient confidentiality.

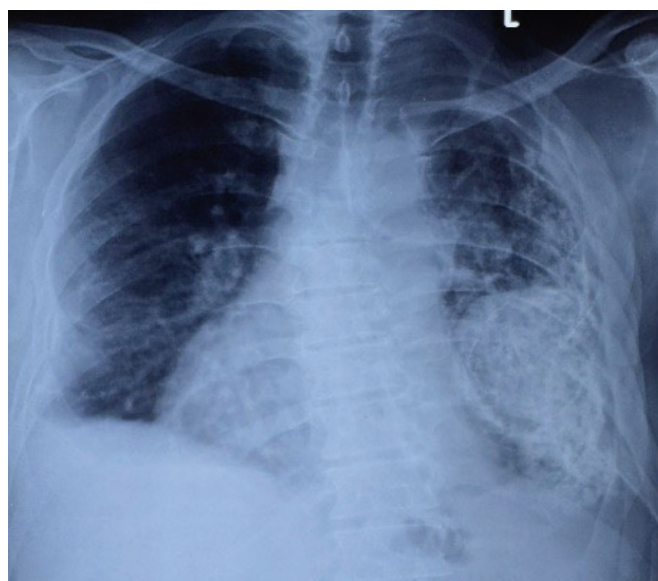


Figure 1. PA chest X-ray showing a large, dense, left-sided calcified mass occupying the hemithorax with associated volume loss, consistent with pleural pathology.

Corresponding Author*: Zeeshan Sarwar, MD. Department of Thoracic Surgery, Services Hospital, House 139, Block 4, Sector C-2, Green Town, Lahore, Punjab, Pakistan.

E-mail: zeeshan.sarwar195@gmail.com Phone: +92 3214347410

Doi: 10.26663/cts.2026.016

Received 26.12.2025 accepted 03.02.2026

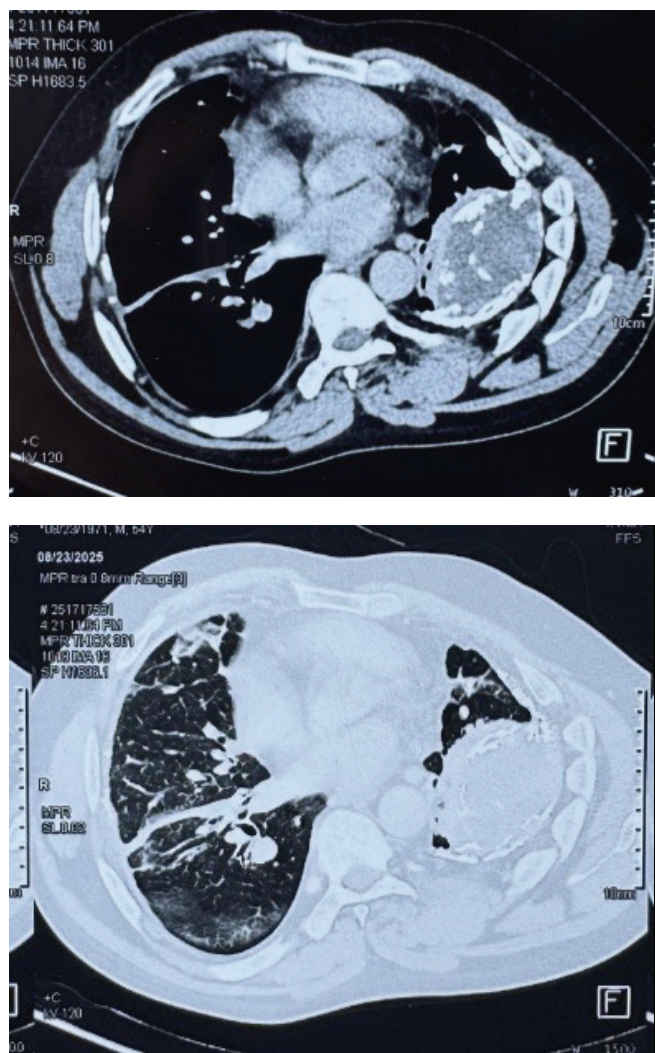


Figure 2. Axial contrast-enhanced CT scan demonstrating long-standing untreated empyema thoracis with a markedly thickened and calcified pleural peel adherent to the left lung, causing fibrothorax.

Keywords: empyema thoracis, fibrothorax, thoracotomy, computed tomography

Declaration of conflicting interests

The authors declared no conflicts of interest with respect to the authorship and/or publication of this article.

Funding

The authors received no financial support for the research and/or authorship of this article.

Authors' contribution

ZS,MSN; design, review, editing and co-writing the paper equally.

References

1. Shen KR, Bribriescio A, Crabtree T, Denlinger C, Eby J, Eiken P et al. The American Association for Thoracic Surgery consensus guidelines for the management of empyema. *J Thorac Cardiovasc Surg* 2017; 153: e129-e146.
2. Scarci M, Abah U, Solli P, Page A, Waller D, van Schil P et al. EACTS expert consensus statement for surgical management of pleural empyema. *Eur J Cardiothorac Surg* 2015; 48: 642-53.
3. Hassan M, Touman AA, Grabczak EM, Skaarup SH, Faber K, Blyth KG, Pochepnia S. Imaging of pleural disease. *Breathe (Sheff)* 2024; 20: 230172.
4. Molnar TF. Current surgical treatment of thoracic empyema in adults. *Eur J Cardiothorac Surg* 2007; 32: 422-30.
5. Yang HC, Drysch A, Kurihara C, Schraufnagel DP, Kim SS, Bharat A, Lung KC. Long-term outcomes after pleural decortication for patients with chronic sterile, non-malignant pleural effusion. *J Thorac Dis* 2025; 17: 7875-85.

This article is an open access article distributed under the terms and conditions of the Creative Commons Attribution (CC BY) license (<http://creativecommons.org/licenses/by/4.0/>).